



Large Tricuspid Valve Myxoma in an Asymptomatic Patient with Uterine Myoma: An Uncommon Case

Mohammad Khani, MD¹, Morteza Abdar Esfahani, MD^{2*}, Fariba Bayat, MD³,
Alireza Khalaj, MD⁴, Abdolhamid Bagheri, MD¹

¹Cardiovascular Research Center, Shahid Beheshti University of Medical Sciences, Tehran, Iran.

²Department of Cardiology, Isfahan University of Medical Sciences, Isfahan, Iran.

³Cardiovascular Research Center, Modarres Hospital, Shahid Beheshti University of Medical Sciences, Tehran, Iran.

⁴Department of Cardiac Surgery, Shahed University of Medical Sciences, Tehran, Iran.

Received 25 October 2020; Accepted 04 February 2021

Abstract

Tricuspid valve myxomas are very uncommon tumors that could be found after the occurrence of pulmonary thromboembolism, symptomatic tricuspid obstruction, and right-sided heart failure. Herein, we describe a 42-year-old woman evaluated for an abdominal mass. In preoperative consultation, a tricuspid valve mass was detected in echocardiography. She underwent the removal of a benign uterine myoma and a myxoma of the tricuspid valve. Tricuspid valve myxomas constitute a scarce diagnosis. They could be asymptomatic, occurring in unusual locations and in association with benign tumors in other organs. Our patient was asymptomatic, underscoring the significance of the early diagnosis of this type of tumor to prevent further catastrophic events.

J Teh Univ Heart Ctr 2021;16(2):75-78

This paper should be cited as: Khani M, Abdar Esfahani M, Bayat F, Khalaj A, Bagheri A. Large Tricuspid Valve Myxoma in an Asymptomatic Patient with Uterine Myoma: An Uncommon Case. *J Teh Univ Heart Ctr* 2021;16(2):75-78.

Keywords: Tricuspid valve; Myoma; Uterine myomectomy; Echocardiography

Introduction

Fifty percent of benign heart tumors are myxomas, which in most cases are sporadic; nonetheless, in about 7% of cases, they are familial.¹ The age at presentation is between 30 and 60 years, although there are reports of congenital myxomas.² Cardiac myxomas are mostly located in the left atrium (75%), followed by the right atrium (18%), the right ventricle (4%), and the left ventricle (3%).¹ A myxoma originating from the tricuspid valve (TV) or the Eustachian valve is extremely rare.³

Case Report

A 42-year-old woman was evaluated for an abdominal mass. The patient had worked as a farmer for over 20 years. She complained of abdominal fullness, which had progressively worsened during the preceding year. She did not complain of weight loss, any syncope-like attack, palpitation, chest pain, or dyspnea; however, she suffered from intermittent vaginal bleeding. Her previous medical history was unremarkable for any disease or drug abuse, and she denied constitutional symptoms.

*Corresponding Author: Morteza Abdar Esfahani, Professor of Cardiology, Department of Cardiology, Faculty of Medicine, Isfahan University of Medical Sciences, Hezar Jerib Street, Isfahan, Iran. 8174673461. Tel: +98 3112223369. Fax: +98 3116691482. E-mail: abdararianian@yahoo.com.



On physical examination, the patient had a blood pressure of 136/87 mmHg without orthostatic change, a pulse rate of 83 beats per minute, a respiratory rate of 21 breaths per minute, and a body temperature of 37.4 °C. She appeared ill and slightly pale. There were no rales over her lung auscultation, while a 3/6 grade systolic murmur was audible at the left lower sternal border in the cardiac examination. The abdominal examination revealed a huge, firm, fixed, and non-tender mass extending from the pelvic cavity to the abdomen. Routine laboratory tests were all within normal limits, except for evidence of hypochromic-microcytic anemia (hemoglobin=9 g/dL, MCH=21, and MCV=73).

Abdominal ultrasonography demonstrated a huge uterine mass, 21 cm² in area. Preoperative cardiology consultation was requested. Twelve-lead electrocardiography showed a normal sinus rhythm, a normal axis, and no ST-segment or T-wave changes. The patient underwent transthoracic echocardiography, which revealed a left ventricular ejection fraction of 51% by the biplane Simpson method. Additionally, a highly mobile, ovoid, well-defined, and pedunculated mass with myocardium-like echogenicity, measuring 4.1 cm×2.6 cm in diameter, was detected. The mass was attached to the atrial aspect of the “belly” of the anterior TV leaflet and prolapsed through the valve to the right ventricular cavity during diastole. The appearance of the mass was suggestive of a cardiac myxoma (Figure 1). For additional data, transesophageal echocardiography was performed. The cardiac mass caused a mild-to-moderate, eccentric, and posteriorly directed tricuspid regurgitation jet and mild valvular stenosis (the mean gradient=3.5 mmHg, the heart rate=94 bpm, and the systolic pulmonary artery pressure=30 mmHg). Right ventricular function was normal (S velocity=12 cm/s).

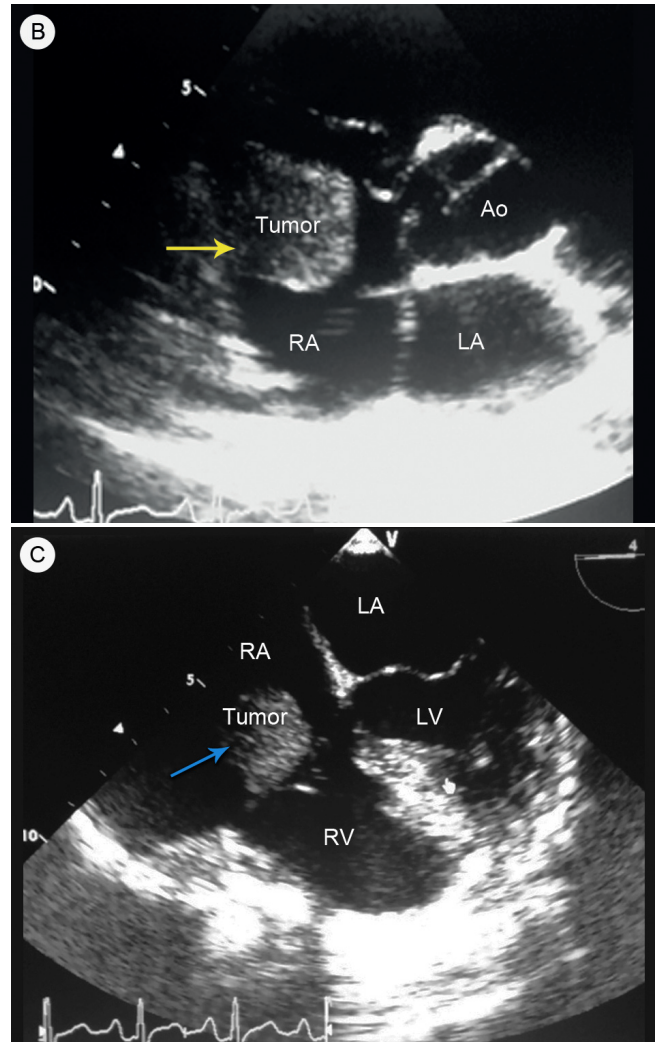
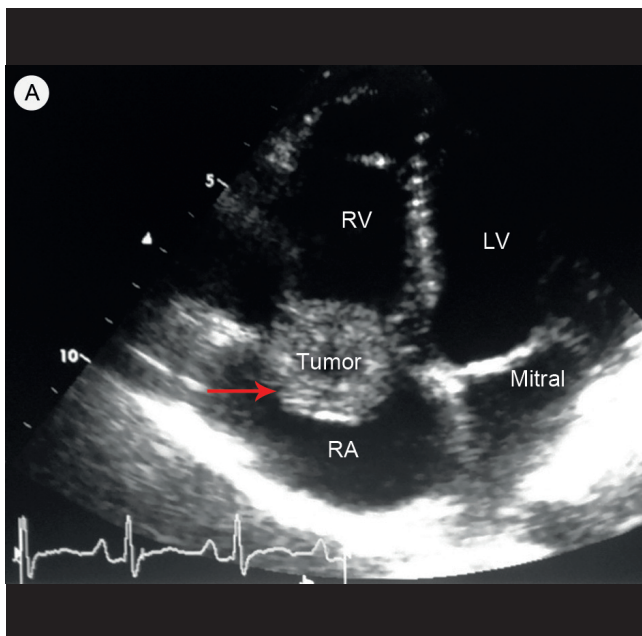


Figure 1. Transthoracic (TTE) and transesophageal (TEE) echocardiographic examinations show a mass in the right heart.

A) TTE in the apical 4-chamber and RV-focused view shows an ovoid, well-defined, and pedunculated mass with “myocardium-like” echogenicity (red arrow). The mass is 4.1 cm×2.6 cm in diameter, and it is attached to the atrial aspect of the “belly” of the anterior tricuspid valve leaflet. It prolapses through the valve to the RV cavity during diastole. The appearance of the mass is suggestive of a cardiac myxoma.

B) The short-axis view in parasternal TTE shows a mobile and well-defined mass (yellow arrow) in the RA (systolic phase).

C) TEE in midesophageal and 0° (CV) in the diastolic phase shows a mass (blue arrow) attached to the atrial aspect of the anterior tricuspid valve leaflet. It prolapses through the valve to the RA cavity during the systolic phase.

RV, Right ventricle; LV, Left ventricle; RA, Right atrium; Ao, Aorta; LA, Left atrium

After cardiac surgery consultation, the surgical removal of the TV mass with TV repair was performed. Six weeks afterward, the patient became a candidate for open laparotomy for pelvic mass removal. A hysterectomy was performed,



and the specimen was sent to the pathology lab. Pathologic findings were indicative of a benign uterine myoma and a TV myxoma. She had an uneventful postoperative course and was discharged 5 days after surgery. On follow-up visits 1, 3, 12, and 48 months later, she was well and had no significant complaints.

Discussion

Our literature review yielded 53 case reports of TV myxomas since 1873.⁴⁻⁹ A TV mass is most likely a tumor or vegetation. Papillary fibroelastomas are usually attached to the valve leaflets and are the third most common type of primary cardiac tumors.¹⁰ A TV myxoma is a very uncommon diagnosis. Conditions associated with atrial myxomas include mitral stenosis, endocarditis, mitral regurgitation, and collagen vascular disease.¹¹ This type of myxoma might occur in both sexes and on the anterior or septal leaflets of the TV, whereas no myxomas solely on the posterior leaflet have been reported yet. The case that we have presented herein has some scintillating and significant clinical points. Firstly, it illustrates that a TV myxoma may be asymptomatic, perhaps due to the smooth surface of this myxoma or the slow growth rate of the tumor. Secondly, the tumor was located on the atrial side of the anterior TV leaflet. Last but not least, our patient had a uterine myoma at the time of the diagnosis of the TV mass.

There have been reports of uterine leiomyomas or leiomyosarcomas extending into or simulating atrial myxomas.¹²⁻¹⁵ Uterine leiomyomas (myomas) or uterine fibroids comprise benign tumors of the uterus, and they arise from the smooth muscle cells of the myometrium. Intravenous leiomyomas with intracardiac extension are very rare clinical entities that usually develop exclusively in women. They originate from either the uterine venous wall or the uterine leiomyoma, and they are commonly misdiagnosed as primary cardiac tumors such as myxomas.¹⁶ A previous case report described a 77-year-old woman who presented with a pelvic mass. The patient was found to have primary endometrial cancer and primary lung cancer with a concomitant metastatic adrenal gland and mesenteric lesions. Her prior medical history also included an untreated 4.0×2.0 cm left atrial myxoma, which was identified on computed tomography scanning during the workup of her pelvic mass. The authors sought cardiothoracic surgery consultation and reported that the deciding factor in the initial treatment of the endometrial cancer reflected the concern for a metastatic malignancy and the quiescent nature of the cardiac lesion.¹⁷

In previous studies, only 5% of patients with TV myxomas were asymptomatic,⁵ with the predominant location of the tumors being on the ventricular side of the TV. Furthermore, we cannot prove any association between the simultaneous occurrences of these tumors. Indeed, such an occurrence

may be an accidental finding or may be in consequence of an association between these tumors. There is only 1 case report in the literature that presents a tumor in the right ventricular outflow tract in a patient with a history of multiple benign tumors in the other organs.⁴ Further genetic studies should be considered in these patients to determine any association between these 2 entities. Moreover, it might be reasonable to perform echocardiography in patients with a benign tumor in the other organs.

Because of the risk of TV obstruction, embolic events, and even sudden cardiac death, TV myxomas must be surgically removed upon diagnosis. The surgical mortality rate is about 1%, and the risk of relapse ranges between 1% and 5%. The latter is mainly due to the dissemination of the tumor during surgical removal, incomplete resection of the tumor, familial predisposition, and unrecognized multifocal origin of the primary lesion, which could occur up to 48 months after tumor resection.^{6,7}

Conclusion

Tricuspid valve myxomas are very uncommon tumors that could be found after the occurrence of pulmonary thromboembolism, symptomatic tricuspid obstruction, and right-sided heart failure. Nevertheless, that our patient was asymptomatic underscores the vital importance of the early diagnosis of this type of tumor to prevent further catastrophic events.

References

1. Lazzara RR, Park SB, Magovern GJ. Cardiac myxomas: results of surgical treatment. *J Cardiovasc Surg (Torino)* 1991;32:824-827.
2. Gopalakrishnaiah Gupta K, Reddy DJ, Sakuntala Devi P, Suryaprakasa Rao T, Venkaiah KR, Venkataswamy Naidu N. Congenital myxoma of the heart. *Indian J Pediatr* 1956;23:210-212.
3. Xiao ZH, Hu J, Zhu D, Shi YK, Zhang EY. Tricuspid valve obstruction and right heart failure due to a giant right atrial myxoma arising from the superior vena cava. *J Cardiothorac Surg* 2013;8:200.
4. Vizzardi E, D'Aloia A, Chiari E, Nardi M, Zanini G, Cabras R, Faden G, Maiandi C, Cas LD. Tricuspid valve myxoma in a patient with congestive heart failure. *Cases J* 2010;3:21.
5. Kim DH, Yi JE, In HJ, Jeong M, Kim MS, Lee JS, Lee JH, Kang B, Jung HO, Youn HJ. Asymptomatic myxoma originating from the right ventricular outflow tract. *J Cardiovasc Ultrasound* 2013;21:186-188.
6. Yuan SM, Shinfeld A, Raanani E. Tricuspid valve myxoma: a case report and a collective review of the literature. *J Card Surg*. 2009;24:69-72.
7. Cho SH, Shim MS, Kim WS. The right ventricular myxoma which attached to the tricuspid valve: sliding tricuspid valvuloplasty. *Korean J Thorac Cardiovasc Surg* 2015;48:228-230.
8. Mustafa ER, Tudoraşcu DR, Giucă A, Toader DM, Foařfă MC, Puiu I, Istrate-Ofițeru AM. A rare cause of ischemic stroke: cardiac myxoma. Case report and review of literature. *Rom J Morphol Embryol* 2018;59:903-909.



9. Wang H, Li Q, Xue M, Zhao P, Cui J. Cardiac myxoma: a rare case series of 3 patients and a literature review. *J Ultrasound Med* 2017;36:2361-2366.
10. Chitwood WR, Jr. Cardiac neoplasms: current diagnosis, pathology, and therapy. *J Card Surg* 1988;3:119-154.
11. Aoyagi S, Tayama E, Yokokura Y, Yokokura H. Right atrial myxoma in a patient presenting with syncope. *Kurume Med J* 2004;51:91-93.
12. Glazer M, Kioschos JM, Kroetz FW, Lawrence MS, Korns ME. Simulation of right atrial myxoma by metastatic leiomyosarcoma. *Cancer* 1971;27:238-241.
13. Tamburino C, Russo G, Incognito C, Battaglia G, Monaca V, Lomeo A, Abbate M. Intracardiac extension of a calcified ovarian hemangioma--a case report. *Angiology* 1992;43:249-252.
14. Lang RM, Borow KM, Neumann A. Metastatic carcinoma involving the left atrium. *Am Heart J* 1985;110:884-886.
15. Kaszar-Seibert DJ, Gauvin GP, Rogoff PA, Vittimberga FJ, Margolis S, Hilgenberg AD, Saal DK, Goldsmith GO. Intracardiac extension of intravenous leiomyomatosis. *Radiology* 1988;168:409-410.
16. Clement PB. Intravenous leiomyomatosis of the uterus. *Pathol Annu* 1988;23:153-183.
17. Abaid LN, Epstein HD, Chang M, Kankus R, Goldstein BH. Endometrial adenocarcinoma with concomitant left atrial myxoma. *Case Rep Oncol* 2009;2:150-156.