



Left Ventricular Dimension after Mitral Valve Surgery in Rheumatic Mitral Stenosis: the Impact of Myocardial Fibrosis

Teuku Muhammad Haykal Putra, MD*, Renan Sukmawan, MD, PhD, Dwita Rian Desandri, MD, Celly A. Atmadikoesoemah, MD, Elen Elen, MD, Manoefris Kasim, MD

Faculty of Medicine, Universitas Indonesia, National Cardiovascular Center Harapan Kita, Jakarta, Indonesia.

Received 05 January 2020; Accepted 06 June 2020

Abstract

Background: Patients with rheumatic mitral stenosis (MS) experience changes in left ventricular (LV) dimensions after mitral valve surgery. We sought to investigate changes in LV dimensional parameters after mitral valve surgery and find out whether the same changes occurred in different extents of myocardial fibrosis.

Methods: This prospective observational study comprised 43 patients with rheumatic MS planned for mitral valve surgery between October 2017 and April 2018 in National Cardiovascular Center Harapan Kita (NCCHK) Jakarta. All the patients underwent cardiac magnetic resonance imaging based on the late gadolinium enhancement (LGE) protocol for myocardial fibrosis assessment prior to surgery. The patients were classified according to the estimated fibrosis volume considered to influence hemodynamic performance (myocardial fibrosis <5% and myocardial fibrosis ≥5%). Serial transthoracic echocardiographic examinations before and after surgery were performed to detect changes in LV dimensional parameters.

Results: This study consisted of 31 (72.1%) women and 12 (27.9%) men at a mean age of 46±9 years. The LGE protocol revealed myocardial fibrosis of less than 5% in 32 (74.4%) patients. A significant increase was detected in the LV end-diastolic diameter postoperatively, specifically in the patients with myocardial fibrosis of less than 5% (44.0±4.8 mm vs 46.6±5.6 mm; P value=0.027). A similar significant increase was not found in the other group (45.0±6.6 mm vs 46.7±6.9 mm; P value=0.256). Other changes in echocardiographic parameters showed similar patterns in both groups.

Conclusion: Our patients with rheumatic MS who had myocardial fibrosis of less than 5% demonstrated better improvements in terms of increased preload. Myocardial fibrosis of less than 5% is associated with more favorable improvements in LV geometry.

J Teh Univ Heart Ctr 2020;15(3):119-127

This paper should be cited as: Putra TMH, Sukmawan R, Desandri DR, Atmadikoesoemah CA, Elen E, Kasim M. Left Ventricular Dimension after Mitral Valve Surgery in Rheumatic Mitral Stenosis: The Impact of Myocardial Fibrosis. J Teh Univ Heart Ctr 2020;15(3):119-127.

Keywords: Endomyocardial fibrosis; Mitral valve stenosis; Rheumatic heart disease

*Corresponding Author: Teuku Muhammad Haykal Putra, National Cardiovascular Center Harapan Kita, Jakarta, Indonesia, Jl. Gandaria I, No. 52, Kebayoran Baru, Jakarta Selatan, Indonesia. Tel: +6282123882795. Fax: +6282123882795. E-mail: tm_haykal@yahoo.com.

Introduction

Rheumatic mitral stenosis (MS) is common in developing countries.^{1, 2} Despite the low prevalence of rheumatic MS in developed countries, a comprehensive understanding of this disease is important to clinicians in all parts of the world.³ A new realm regarding this disease is the presence of myocardial fibrosis in the left ventricle (LV).⁴⁻⁶ The development of myocardial fibrosis in rheumatic MS is related to chronic inflammation surrounding the myocardium.⁷ Some previous studies have highlighted the presence of myocardial fibrosis in rheumatic MS and its clinical impact in terms of LV dysfunction. Those studies have mostly relied on histopathological analyses to detect myocardial fibrosis.⁸⁻⁹

Cardiac magnetic resonance imaging (CMR) is a relatively new modality to detect myocardial fibrosis. We used to depend only on myocardial biopsy to identify myocardial fibrosis. With the development of the late gadolinium enhancement (LGE) protocol, a noninvasive modality to detect myocardial fibrosis is currently available.¹⁰ Furthermore, this modality has already been validated to have good accuracy in detecting myocardial fibrosis in patients with rheumatic MS.⁶

The presence of myocardial fibrosis leads to increased morbidity after heart surgery.¹¹⁻¹³ Multiple investigations regarding this topic have already been published. It applies not only to coronary heart disease but also to aortic valve diseases.¹³ Furthermore, this issue is also applicable to patients with rheumatic MS who undergo mitral valve surgery as was described in previous publications with a similar subset of patients to this research.¹⁴ Despite the established association between myocardial fibrosis and the clinical outcome after heart surgery, we still have no evidence whether it affects the LV anatomically.

Patients with rheumatic MS will experience changes in LV dimensions after the removal of the restrictive flow in the mitral valve, either surgically or percutaneously.^{15, 16} It has already been shown that myocardial fibrosis influences LV dimensional improvement following aortic valve replacement in severe aortic stenosis cases.¹⁷ The extent of myocardial fibrosis might also influence alterations in LV dimensions following mitral valve surgery in patients with rheumatic MS. We sought to investigate changes in LV dimensional parameters after mitral valve surgery and find out whether the same changes occurred in different extents of myocardial fibrosis.

In most clinicians' minds, the presence of myocardial fibrosis among patients with rheumatic MS planned for mitral valve surgery warrants evidence that such things influence the outcome of the surgery. This issue has already been established by our previous publication. More extensive myocardial fibrosis is associated with postoperative morbidity after mitral valve surgery in patients with rheumatic MS.¹⁴ Therefore, the clinical outcome after

surgery is not what we tried to investigate. Cardiologists and surgeons expect the drastic recovery of preload after the surgical removal of the restrictive flow in the mitral valve. This expectation emerges from a basic understanding of MS hemodynamically. This is also evident from multiple previous studies.^{15, 16} The emerging issue regarding the presence of myocardial fibrosis in patients with rheumatic MS creates doubts as to whether such an increase in preload occurs to all patients with rheumatic MS after surgery. Do patients with extensive myocardial fibrosis also experience drastic preload improvement after surgery? The clinical implication of our study is for clinicians, both surgeons and cardiologists, in their efforts to understand the mechanism of changes in LV dimensions following mitral valve surgery in patients with rheumatic MS.

Methods

This is a prospective observational study designed to analyze changes in LV dimensions after mitral valve surgery in patients with rheumatic MS and their association with the extent of myocardial fibrosis. We enrolled 47 consecutive adult patients with severe rheumatic MS who were planned for mitral valve surgery between October 2017 and April 2018. All the patients enrolled were examined by transthoracic echocardiography and CMR prior to surgery.

The exclusions criteria were comprised of congenital heart disease, coronary heart disease, significant aortic valve abnormalities, significant mitral regurgitation, contraindications for CMR (creatinine > 2 g/dL, metallic implants, and inability to lie still during examinations), and inability to undergo transthoracic echocardiography between day 5 and day 8 postoperatively. A significant aortic valve abnormality was defined as either aortic stenosis or aortic regurgitation with more-than-mild severity evaluated according to the updated American Society of Echocardiography (ASE) guidelines.^{18, 19} Significant mitral regurgitation was defined as mitral regurgitation with more-than-mild severity evaluated according to the updated ASE guidelines.¹⁸ Four patients were excluded because the second transthoracic echocardiographic examination could not be performed in time; it was due to death and prolonged intensive care unit (ICU) stay. Finally, 43 enrolled patients were analyzed in this study. The detailed process of the patients' enrollment is illustrated in Figure 1.

The bulk of the study population's clinical history was acquired from medical records including preoperative medications, history of stroke, and atrial fibrillation. The body mass index was measured at the time of CMR. The functional class was assessed during interviews prior to CMR.

This is a single-centered study, conducted in a national tertiary referral center National Cardiovascular Center

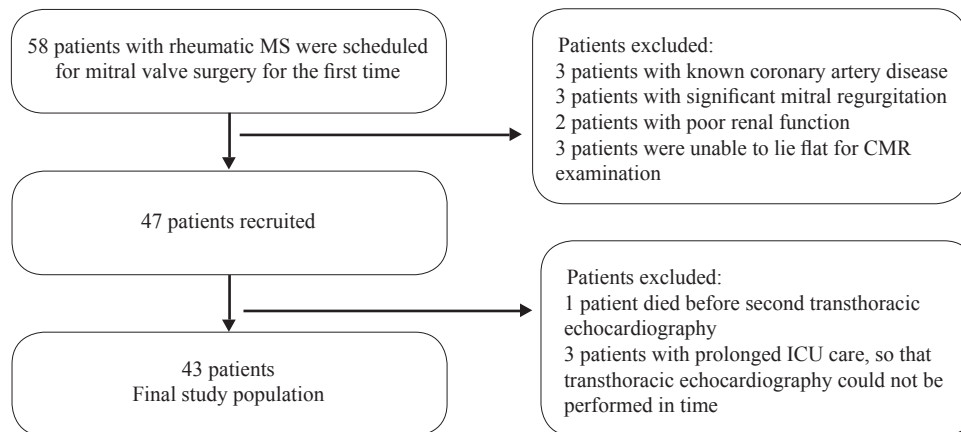


Figure 1. Patient enrollment flow diagram

CMR, Cardiac magnetic resonance imaging; ICU, Intensive care unit

Harapan Kita [NCCHK]) in Indonesia. The study protocol was approved by the Review Board of NCCHK, and written informed consent was obtained from all the patients including consent for CMR examinations with the use of contrast agents.

Echocardiographic examinations were performed using the GE Vivid E9 system (GE Vingmed Ultrasound AS, Horten, Norway) with a 3.5-MHz transducer. All the acquired data were analyzed in a workstation (EchoPAC PC, GE Vingmed Ultrasound AS). The size of the heart chambers was measured according to the updated ASE guidelines for the cardiac chamber quantification.²⁰ The left ventricular ejection fraction (LVEF) was measured from the M-mode analysis utilizing the left ventricular end-diastolic diameter (LVEDD) and left ventricular end-systolic diameter (LVESD). The mitral valve area was measured by pressure half-time calculation, planimetry tracing, or continuity equation calculation. The mean pulmonary arterial pressure was calculated according to the formula: $80 - \text{right ventricular outflow tract acceleration time} \times 0.5$.²¹ Every measurement of echocardiographic data in patients with atrial fibrillation was performed 3 times. The average result of those 3 measurements was recorded as the final data to be analyzed.²⁰ Transthoracic echocardiography was performed twice in each patient: before surgery and in the span of 5 to 8 days following surgery. The preoperative echocardiographic data are reported and described as baseline characteristics in Table 1. The postoperative echocardiographic data, mainly used for comparisons and statistical analyses, are presented in Table 2. The transthoracic echocardiographic examinations were analyzed by a cardiologist blinded to the CMR imaging results.

Similar standards and protocol of CMR examinations were adhered to for all the patients. CMR was performed within 1 month prior to surgery by using Achieva 1.5 Tesla MRI (Philips®, Amsterdam, Netherlands). The electrocardiography (ECG)-gated steady-state free precession (SSFP) method

was used for image acquisition to multiple planes of the heart, particularly short-axis images for LGE analyses. The standard gadolinium dosage was used (0.1 mmol/kg). Image acquisition for the LGE protocol was taken 10 minutes after gadolinium injection. All CMR parameters, including LGE quantification, were analyzed using the integrated software CVI42® (Circle CVI, Calgary, Canada) in a specialized computer unit. The results of the CMR examinations of all the patients were in good quality for measurements and analyses. CMR analysis and interpretation was performed by a team of cardiovascular imaging cardiologists blinded to the echocardiography result. Myocardial fibrosis assessment and quantification were performed by the leader of the team, a senior cardiologist/cardiovascular imaging specialist with more than 15 years of experience in interpreting CMR. Estimated myocardial fibrosis volumes were analyzed from a stack of short-axis LGE images using manual adjustments semiautomatically. The LGE volume was quantified through the manual adjustment of the signal intensity threshold determined by the team leader. It integrated both cardiologist expertise and software capability to quantify the estimated fibrosis volume as a percentage of the LGE mass to the LV mass. The fibrosis volume was presented as the percentage of the LGE mass to the LV mass accumulated from each segment.^{22, 23} Finally, the patients were classified according to their estimated fibrosis volumes, considered to influence hemodynamic performance: those with myocardial fibrosis of less than 5% and those with minimum myocardial fibrosis of 5%.²⁴⁻²⁶

The continuous variables with normal distributions were presented as the mean±the standard deviation, while the continuous variables with non-normal distributions were presented as the median and the interquartile range (IQR). The patients were classified into 2 groups: those with myocardial fibrosis of less than 5% and those with minimum myocardial fibrosis of 5%. The independent Student t-test was used to analyze differences in means between the groups. The

Table 1. Baseline characteristics*

	All patients (N=43)	LGE <5% (n=32)	LGE ≥5% (n=11)	P
Age (y)	46.3±9.1	46.2±8.2	46.5±11.8	0.942
Female	31 (72.1)	25 (78.1)	6 (54.6)	0.241
Body mass index (kg/m ²)	23.3±4.7	23.8±4.8	21.7±4.2	0.204
Atrial fibrillation	36 (83.7)	29 (90.6)	7 (63.6)	0.058
NYHA Functional Class				0.698
NYHA I – II	31 (72.1)	22 (68.8)	9 (81.8)	
NYHA III – IV	12 (27.9)	10 (31.2)	2 (18.2)	
Preoperative Echocardiographic data				
LVEDD (mm)	44.0±5.4	43.5±4.9	45.0±6.6	0.582
LVESD (mm)	30.3±5.6	30.4±4.9	30.0±7.4	0.746
LVEF (%)	59.3±9.3	59.6±8.4	58.7±11.6	0.748
TAPSE (mm)	17.5±4.8	17.0±5.1	18.6±3.7	0.185
MVA (cm ²)	0.72±0.22	0.74±0.22	0.67±0.21	0.328
Mean MVG (mmHg)	11.3±4.2	11.2±4.5	11.7±3.5	0.754
LAVI (mL/m ²)	106 (67-145)	104 (78-130)	107 (57-157)	0.469
mPAP (mmHg)	34.2±9.9	33.6±10.8	35.7±7.3	0.549
TVG (mmHg)	54.9±21.5	52.4±21.6	61.0±21.2	0.194
Severe tricuspid regurgitation	11 (25.6)	7 (21.9)	4 (36.4)	0.430
Severe pulmonary hypertension	27 (62.8)	18 (56.3)	9 (81.8)	0.166
Preoperative Laboratory Data				
Creatinine (mg/dL)	0.89±0.20	0.88±0.20	0.93±0.21	0.441
eGFR (mL/min/1.73m ²)	87.4±18.3	87.1±18.9	88.1±17.3	0.875
Preoperative Medications				
ACE-Inhibitors or ARBs	16 (37.2)	14 (43.8)	2 (18.2)	0.166
β-blockers	35 (81.4)	26 (81.3)	9 (81.8)	1.000
Digoxin	19 (44.2)	13 (40.6)	6 (54.5)	0.495
MRA	32 (74.4)	24 (75)	8 (72.7)	1.000
History of stroke	6 (14.0)	4 (12.5)	2 (18.2)	0.637
Cross-clamp time (min)	68 (42-94)	65 (35-95)	89 (56-122)	0.181
CPB time (min)	113.1±51.3	107.9±52.1	128.3±47.7	0.260
Types of Mitral Valve Surgery				0.401
Mitral valve repair	8 (18.6)	5 (15.6)	3 (27.3)	
Mitral valve replace	35 (81.4)	27 (84.4)	8 (72.7)	
Concomitant tricuspid valve repair	27 (62.8)	17 (53.1)	10 (90.9)	0.033
Other Concomitant Surgical Procedure				
Left atrial reduction	13 (30.2)	9 (28.1)	4 (36.4)	0.709
Exclusion of left atrial appendage	30 (69.8)	21 (65.6)	9 (81.8)	0.456

*Data are presented as mean±SD, median (IQR), or n (%)

LGE, Late gadolinium enhancement; NYHA, New York Heart Association; LVEDD, Left ventricular end-diastolic diameter; LVESD, Left ventricular end-systolic diameter; LVEF, Left ventricular ejection fraction; TAPSE, Tricuspid annular plane systolic excursion; MVA, Mitral valve area; MVG, Mitral valve gradient; LAVI, Left atrial volume index; mPAP, Mean pulmonary artery pressure; TVG, Tricuspid valve gradient; eGFR, Estimated glomerular filtration rate; ACE, Angiotensin-converting enzyme; ARB, Angiotensin II receptor blocker; MRA, Mineralocorticoid receptor antagonist; CPB, Cardiopulmonary bypass



Table 2. Preoperative cardiac magnetic resonance imaging characteristics*

	All Patients (N=43)	LGE <5% (n=32)	LGE ≥5% (n=11)	P
LVEF (%)	53 (37-69)	53 (38-68)	55 (31-79)	0.845
Low LVEF (<40%)	9 (20.9)	6 (18.8)	3 (27.3)	0.672
RVEF (%)	43.2±10.5	43.6±10.8	42.2±9.6	0.704
LVEDVi (mL/m ²)	75 (59-91)	73.5 (45.2-101.8)	84 (59-109)	0.452
LVESVi (mL/m ²)	36 (27-45)	35.5 (22-49)	36 (19-53)	0.540
RVEDVi (mL/m ²)	89 (71-108)	85.5 (55.5-115.5)	111 (59-163)	0.116
RVESVi (mL/m ²)	47 (35-59)	45.5 (24.2-66.8)	60 (30-90)	0.220
LAVI (mL/m ²)	158 (104-212)	150 (87-213)	175 (86-264)	0.749

*Data are presented as mean±SD, median (IQR), or n (%)

LGE, Late gadolinium enhancement; LVEF, Left ventricular ejection fraction; RVEF, Right ventricular ejection fraction; LVEDVi, Left ventricular end-diastolic volume index; LVESVi, Left ventricular end-systolic volume index; RVEDVi, Right ventricular end-diastolic volume index; RVESVi, Right ventricular end-systolic volume index; LAVI, Left atrial volume index

Mann–Whitney U-test was employed to analyze differences in medians between the groups. The categorical data were presented as frequencies and percentages, and the analysis of differences was carried out using the χ^2 and Fisher exact tests, as appropriate. The paired *t*-test was applied to analyze the mean difference of the echocardiographic parameter before and after surgery in each group. All the statistical analyses were performed using IBM SPSS Statistics, version 20 (IBM Corp, Chicago, USA). A P value of less than 0.05 was considered statistically significant.

Results

The 43 patients enrolled in this research consisted of 31 (72.1%) women and 12 (27.9%) men at a mean age of 46±9 years. Most patients had relatively mild functional disturbance, (New York Heart Association [NYHA] functional classes I and II). Most patients had their mitral valve replaced with either mechanical or bioprosthetic valves (81.4%). The repair of the mitral valve was only performed in a small number of patients (18.6%). Concomitant tricuspid valve surgery was performed in 62.8% of the cases. All the clinical characteristics and intraoperative data of the entire study population are presented in Table 1. No significant difference was observed between the groups concerning patient characteristics, except for the concomitant procedure of tricuspid valve repair. The patients with minimum myocardial fibrosis of 5% were most likely to have concomitant tricuspid valve repair compared with the patients with myocardial fibrosis of less than 5%.

The LGE protocol in CMR revealed that the prevalence of myocardial fibrosis in our patients with rheumatic MS scheduled for surgery was 90.7%. All the LGE appearances were patchy in the mid-myocardium and scattered throughout multiple regions of the LV. The median estimated fibrosis volume was 3.0% (IQR: 1.1%-5.0%). The main LGE sites of detection in the LV were the inferior wall (61.5%) and the inferior septum (48.7%). The bulk of LGE was found at the mid-level of the LV (89.7%). A thorough distribution

of the detected myocardial fibrosis based on the LV region is depicted in Figure 2. Some representative examples of the myocardial fibrosis analysis by the LGE protocol are presented in Figure 3. There were 9 (20.9%) patients with an LVEF of less than 40% (overall median of LVEF=53%, IQR: 37%–69%). A detailed description of the preoperative CMR data is presented in Table 2.

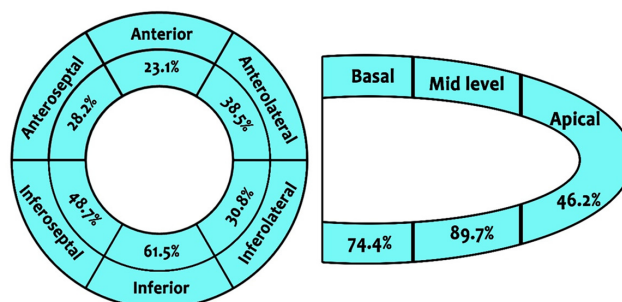
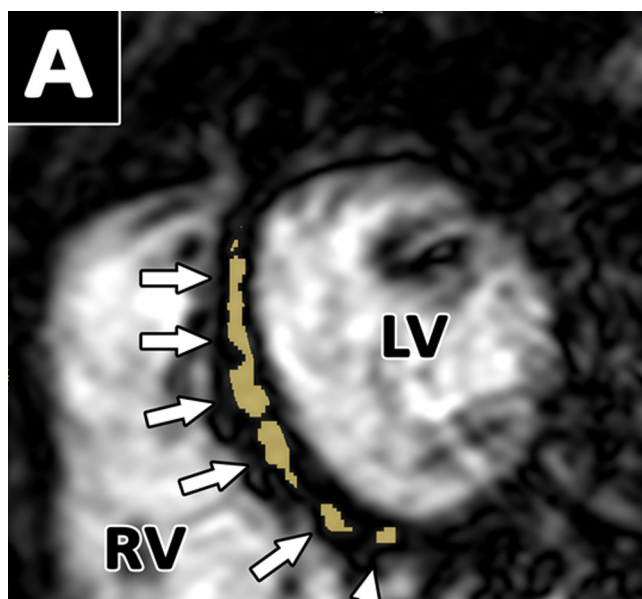


Figure 2. Distribution of the detected LGE image in every LV region
LGE, Late gadolinium enhancement; LV, Left ventricle



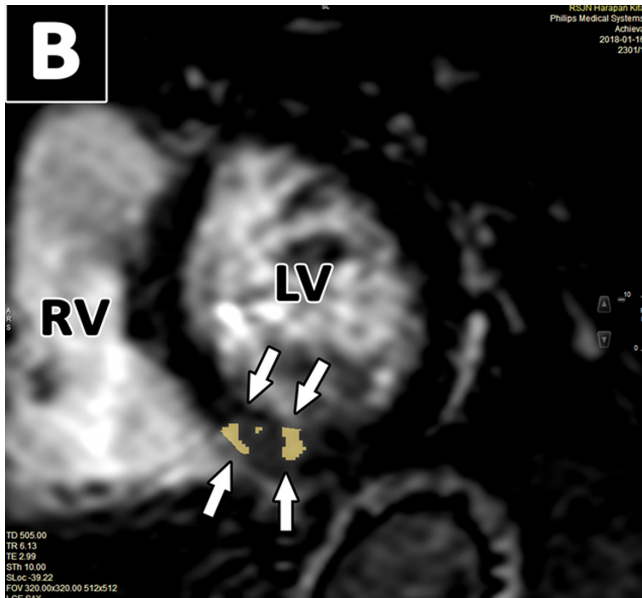


Figure 3. Late gadolinium enhancement protocol in cardiac magnetic resonance imaging analysis from different patients with rheumatic mitral stenosis

Both pictures were taken from the short-axis view of the heart at mid-level. Myocardial fibrosis analyzed in this view is shown in yellow (pointed by the white arrow). Different amounts of myocardial fibrosis can be noticed from Picture A and Picture B. Picture A was obtained from a 64-year-old man with an estimated fibrosis volume of 11.4%. Picture B was obtained from a 43-year-old woman with an estimated fibrosis volume of 1.4%.

LV, Left ventricle; RV, Right ventricle

The measurements of LV dimensional parameters, as well as LVEF and tricuspid annular plane systolic excursion (TAPSE), after mitral valve surgery were compared with those measured before surgery. Overall, LVEDD was significantly increased after mitral valve surgery (from 44.2±5.3 mm to 46.6±5.8 mm; P value=0.012), while LVESD did not change significantly (from 30.5±5.7 mm to 31.7±6.1 mm; P value=0.269). LVEF did not change significantly after surgery (from 59.5±9.5% to 59.9±9.3%, P value=0.843). TAPSE was significantly reduced after surgery (from 16.9±5.0 mm to 11.0±2.8 mm; P value<0.001).

Further analysis was performed in the group with myocardial fibrosis of less than 5% and the group with minimum myocardial fibrosis of 5%. A similar pattern of change was noted in LVESD, LVEF, and TAPSE in each group. However, a significant increase in LVEDD after surgery was found exclusively in the patients with myocardial fibrosis of less than 5% (from 44.0±4.8 mm to 46.6±5.6 mm; P value=0.027). No significant change in LVEDD was observed in the patients with minimum myocardial fibrosis of 5% (from 45.0±6.6 mm to 46.7±6.9 mm; P value=0.256). The comparisons of echocardiographic parameters between the groups are shown in Table 3.

Table 3. Echocardiographic changes after mitral valve surgery in rheumatic MS*

Echocardiographic Parameter	Preoperative	Postoperative	P
Overall (N=43)			
LVEDD (mm)	44.2±5.3	46.6±5.8	0.012
LVESD (mm)	30.5±5.7	31.7±6.1	0.269
LVEF (%)	59.5±9.5	59.9±9.3	0.843
TAPSE (mm)	16.9±5.0	11.0±2.8	<0.001
Myocardial Fibrosis <5% (n=32)			
LVEDD (mm)	44.0±4.8	46.6±5.6	0.027
LVESD (mm)	30.7±5.1	31.5±6.2	0.521
LVEF (%)	59.8±8.8	60.1±8.8	0.897
TAPSE (mm)	16.3±5.3	11.0±2.9	<0.001
Myocardial Fibrosis ≥5% (n=11)			
LVEDD (mm)	45.0±6.6	46.7±6.9	0.256
LVESD (mm)	30.0±7.4	32.2±6.1	0.269
LVEF (%)	58.7±11.6	59.3±11.2	0.854
TAPSE (mm)	18.6±3.7	10.9±2.4	<0.001

*Data are presented as mean±SD

MS, Mitral stenosis; LVEDD, Left ventricular end-diastolic diameter; LVESD, Left ventricular end-systolic diameter; LVEF, Left ventricular ejection fraction; TAPSE, Tricuspid annular plane systolic excursion

Discussion

The prevalence of myocardial fibrosis in the population with rheumatic MS in the present study was very high. Thirty-nine patients from 43 patients (90.7%) were positive for LV myocardial fibrosis by CMR examinations. This result is not very different from the results in some previous investigations that recruited a subset of patients similar to that in our research (91.5%).¹⁴ However, other epidemiological studies regarding this topic have provided very different numbers. A previous study stated that the prevalence of myocardial fibrosis detected by necropsy analysis among patients with rheumatic heart disease (RHD) was only 19.9%.²⁷ This great difference in prevalence might have resulted from different methods to identify myocardial fibrosis. The detection of myocardial fibrosis by myocardial biopsy is subjected to selection bias during tissue sampling, leading to a high number of false-negative findings.^{10, 17} The prevalence rate of myocardial fibrosis in patients with rheumatic MS as detected by CMR in our study is quite novel. Accordingly, the results of this study indicate that myocardial fibrosis in the population with RHD is more common than previously imagined.

The LGE findings in our study were patchy in the mid-myocardium and scattered throughout multiple regions of the LV. The patchy appearance of LGE is highlighted as a nonischemic cause of myocardial fibrosis.¹⁰ This characteristic resembles the findings of myocardial fibrosis in patients with hypertrophic cardiomyopathy and aortic stenosis.^{17, 24-28}



Replacement fibrosis in both hypertrophic cardiomyopathy and aortic stenosis is due to myocyte apoptosis because of the progression of the disease. On the other hand, the cause of myocardial fibrosis in rheumatic MS is the inflammatory process. Recurrent inflammatory exposure to the myocardium is responsible for this pathology.²⁹ Although manifested with a pattern of myocardial fibrosis similar to that of hypertrophic cardiomyopathy and aortic stenosis, myocardial fibrosis in RHD arises from a very different mechanism.

The distribution of myocardial fibrosis throughout specific regions of the LV in the population with RHD as described in our study has never been reported before. On the horizontal plane, we detected myocardial fibrosis primarily in the inferior, inferoseptal, and anterolateral segments of the LV. This apparently represents regions of the LV in which the papillary muscles of the mitral valve are located. The pathophysiologic process of recurrent inflammatory exposure in RHD, which is known as molecular mimicry, indicates that the parts of the heart recognized by autoantibodies are the valve endothelium and myocardium.²⁹ The initial inflammatory process, as well as initial myocardial fibrosis, might occur in those regions. Starting at the valve endothelium, the inflammatory process might spread out to the myocardium surrounding each papillary muscle of the mitral valve and result in myocardial fibrosis predominantly at that specific segment. A similar pattern can be suspected by observing the distribution of myocardial fibrosis from the vertical plane. Myocardial fibrosis is predominantly found in the basal and mid parts of the LV, where the papillary muscles are located. The specific pattern of myocardial fibrosis distribution in the population with RHD was first reported by Horwitz et al.⁸ in 1973. They observed LV regional wall motion abnormalities in patients with rheumatic MS in cardioangiographic examinations, with the abnormalities dominantly found around the papillary muscles, prompting the suspicion of myocardial fibrosis in that area.⁸ Although it appears that our research confirms that notion from decades ago, further molecular analysis is needed to confirm the suspected pathophysiologic inflammatory development.

Image reconstruction in CMR requires several cardiac cycles with ECG gating. Arrhythmias such as atrial fibrillation might result in degraded image quality. Poor image quality might result in poor accuracy of measurements. Nonetheless, it has been validated by multiple research that CMR examinations in patients with atrial fibrillation are accurate and reproducible.^{30, 31} Therefore, atrial fibrillation should not be an issue in analyzing CMR unless the quality of the image is poor. This is important to our research because the proportion of samples with atrial fibrillation was 83.7%. The common practice for CMR examinations is that poor image quality is considered to be invalid for measurement. In our research, if the image quality was poor, we scheduled the patient for a re-examination. Fortunately, all data from 43 CMR examinations were in good quality. Consequently,

neither redo CMR nor the exclusion of samples because of poor image quality was required.

Right ventricular (RV) function is decreased after mitral valve surgery in patients with rheumatic MS as demonstrated by the result of our research. This phenomenon is not exclusive to the population with rheumatic MS. A decrease in TAPSE has been previously recorded after mitral valve surgery in degenerative mitral regurgitation.³² Previous research has also shown that any cardiac surgical procedure might decrease RV function.^{33, 34} Decreased RV function might even persist over time years after surgery.³⁵ In our research, we identified decreased RV function in both groups, indicating that RV function will drop regardless of the extent of myocardial fibrosis in the LV. This is a plausible condition because myocardial fibrosis in the LV might not influence RV function directly.

It has already been established that the release of the restrictive flow in MS percutaneously results in the increased dimensional size of the LV during diastole. This increase in the dimensional size of the LV during diastole is in line with increased stroke volume and cardiac output. It indicates increased preload in the LV after the removal of the restrictive flow in the mitral valve.^{15, 36} A similar response has also been previously observed after mitral valve surgery in patients with rheumatic MS. The removal of the restrictive flow surgically will also cause increased LV dimensional size during diastole. Hence, better preload and improved cardiac output can also be achieved after mitral valve surgery.¹⁶ This mechanism was also pointed out by the result of our study. Overall, a significant increase in LVEDD after mitral valve surgery can be found in the population with rheumatic MS.

A dissimilar pattern of change in LV dimensional parameters after mitral valve surgery was conspicuous between our 2 groups. Our patients with myocardial fibrosis of less than 5% had a significant increase in LVEDD following mitral valve surgery, while those with minimum myocardial fibrosis of 5% did not exhibit such significant change. A previous study highlighted the different response of LV geometry after aortic valve replacement in patients with severe aortic stenosis based on LGE findings: the presence of LGE was associated with poor improvements in LV geometry following aortic valve replacement.¹⁷ Albeit conducted in a different subset of patients, the results of our study chime in with those of previous studies insofar as our patients with more extensive myocardial fibrosis presented with a poor response in terms of LV improvement following mitral valve surgery. Additionally, myocardial fibrosis of less than 5% was associated with more favorable improvements in LV geometry.

A heart with myocardial fibrosis develops certain traits of LV dysfunction. Systolic dysfunction in myocardial fibrosis is easily detected by global longitudinal strain. Specifically in the population with rheumatic MS, a moderate correlation has been previously reported between the estimated volume

of myocardial fibrosis detected by LGE in CMR and global longitudinal strain.³⁷ On the other hand, diastolic dysfunction is an obvious condition in myocardial fibrosis. Severe myocardial fibrosis analyzed by LGE significantly correlates with the degree of diastolic dysfunction.³⁸ This is in line with what we find in our research. The heart's ability to significantly increase preload after mitral valve surgery in rheumatic MS was not evident in our patients with minimum myocardial fibrosis of 5%. This indicates the poor compliance of the heart with larger extensions of myocardial fibrosis, suggesting its characteristic of diastolic dysfunction.

This research aimed to determine differences in LV changes based on the extent of myocardial fibrosis. The clinical impact of these differences is not explored in this research. It is worthy of note that clinicians might argue whether such a small difference (ie, increased LVEDD) after surgery is clinically important. Further research with a larger sample size in order to understand the clinical impact of different LV changes might be needed. On the other hand, the clinical profile of our study population was relatively mild to moderate. Patients with a severe clinical profile were excluded indirectly because such patients were unable to undergo CMR. Patients with such a profile tend to have a poor renal function and cannot lie flat for CMR. Moreover, we did not analyze the advanced parameters of echocardiography such as global longitudinal strain by speckle-tracking echocardiography. The analysis of such advanced echocardiographic parameters might reveal more detailed changes in the LV following mitral valve surgery.

Conclusion

A significant increase in LVEDD was observed after mitral valve surgery in our patients with rheumatic MS. Nevertheless, this change occurred almost exclusively in patients with myocardial fibrosis of less than 5%. Myocardial fibrosis of less than 5% was associated with favorable improvements in LV geometry. This study demonstrated different changes in the LV in patients with more extensive myocardial fibrosis.

Acknowledgments

The protocol of the current study was approved by the Review Board of the National Cardiovascular Center Harapan Kita (NCCHK). Written informed consent was obtained from all the patients including consent for cardiac magnetic resonance imaging, which used contrast agents. Funding used in this research was independently managed by the authors. All the authors declare that there are no conflicts of interest.

References

1. Bhaya M, Panwar S, Beniwal R, Panwar RB. High prevalence of rheumatic heart disease detected by echocardiography in school children. *Echocardiography* 2010;27:448-453.
2. Marijon E, Ou P, Celermajer DS, Ferreira B, Mocumbi AO, Jani D, Paquet C, Jacob S, Sidi D, Jouven X. Prevalence of rheumatic heart disease detected by echocardiographic screening. *N Engl J Med* 2007;357:470-476.
3. Lung B. Mitral stenosis still a concern in heart valve disease. *Arch Cardiovasc Dis* 2008;101:597-599.
4. Saraiva LR, Carneiro RW, Arruda MB, Brindeiro D, Lira V. Mitral valve disease with rheumatic appearance in the presence of left ventricular endomyocardial fibrosis. *Arq Bras Cardiol* 1999;72:330-332.
5. Perennec J, Herremans F, Ameer A, Degeorges M, Hatt PY. Ultrastructural and histological study of left ventricular myocardium in mitral stenosis. *Basic Res Cardiol* 1980;75:353-364.
6. Choi EY, Yoon SJ, Lim SH, Choi BW, Ha JW, Shin DH, Chung N. Detection of myocardial involvement of rheumatic heart disease with contrast-enhanced magnetic resonance imaging. *Int J Cardiol* 2006;113:36-38.
7. Wedum B, McGuire J. Origin of the aschoff body. *Ann rheum Dis* 1963;22:127-141.
8. Horwitz L, Mullins C, Payne R, Curry G. Left ventricular function in mitral stenosis. *Chest* 1973;64:609-614.
9. Lee Y, Lee C. Ultrastructural pathological study of left ventricular myocardium in patients with isolated rheumatic mitral stenosis with normal or abnormal left ventricular function. *Jpn heart J* 1990;31:435-448.
10. Mewton N, Liu CY, Croisille P, Bluemke D, Lima JA. Assessment of myocardial fibrosis with cardiovascular magnetic resonance. *J Am Coll Cardiol* 2011;57:891-903.
11. Chaikringkrai K, Lopez-Mattei J, Lawrie G, Ibrahim H, Quinones MA, Zoghbi W, Little SH, Shah DJ. Prognostic value of delayed enhancement cardiac magnetic resonance imaging in mitral valve repair. *Ann Thorac Surg* 2014;9:1557-1563.
12. Kancharla K, Weissman G, Elagha A, Kancherla K, Samineni S, Hill PC, Boyce S, Fuisz AR. Scar quantification by cardiovascular magnetic resonance as an independent predictor of long-term survival in patients with ischemic heart failure treated by coronary artery bypass graft surgery. *J Cardiovasc Magn Reson* 2016;18:1-9.
13. Barone-Rochette G, Pierard S, DeMeester de Ravenstein C, Seldrum S, Melchior J, Maes F, Pouleur AC, Vancraeynest D, Pasquet A, Vanoverschelde JL, Gerber BL. Prognostic significance of LGE by CMR in aortic stenosis patients undergoing valve replacement. *J Am Coll Cardiol* 2014;64:144-154.
14. Putra TMH, Sukmawan R, Elen E, Atmadikoesoemah CA, Desandri DR, Kasim M. Prognostic value of late gadolinium enhancement in postoperative morbidity following mitral valve surgery in rheumatic mitral stenosis. *Int J Angiol* 2019;28:237-244.
15. Sengupta SP, Amaki M, Bansal M, Fulwani M, Washimkar S, Hofstra L, Narula J, Sengupta PP. Effects of percutaneous balloon mitral valvuloplasty on left ventricular deformation in patients with isolated severe mitral stenosis: a speckle-tracking strain echocardiographic study. *J Am Soc Echocardiogr* 2014;27:639-647.
16. Parvathy UT, Rajan R, Faybushevich G. Reversal of abnormal cardiac parameters following mitral valve replacement for severe mitral stenosis in relation to pulmonary artery pressure: a retrospective study of noninvasive parameters – early and late pattern. *Interv Med Appl Sci* 2016;8:49-59.
17. Park J, Chang HJ, Choi JH, Yang PS, Lee SE, Heo R, Shin S, Cho JJ, Kim YJ, Shim CY, Hong GR, Chung N. Late gadolinium enhancement in cardiac MRI in patients with severe aortic stenosis and preserved left ventricular systolic function is related to attenuated improvement of left ventricular geometry and



- filling pressure after aortic valve replacement. *Korean Circ J* 2014;44:312-319.
18. Zoghbi WA, Adams D, Bonow RO, Enriquez-Sarano M, Foster E, Grayburn PA, Hahn RT, Han Y, Hung J, Lang RM, Little SH, Shah DJ, Sherman S, Thavendiranathan P, Thomas JD, Weissman NJ. Recommendations for noninvasive evaluation of native valvular regurgitation: a report from the American Society of Echocardiography developed in collaboration with the Society for Cardiovascular Magnetic Resonance. *J Am Soc Echocardiogr* 2017;30:303-371.
 19. Baumgartner HC, Hung JC, Bermejo J, Chambers JB, Edvardsen T, Goldstein S, Lancellotti P, LeFevre M, Miler F, Jr, Otto CM. Recommendations on the echocardiographic assessment of aortic valve stenosis: a focused update from the European Association of Cardiovascular Imaging and the American Society of Echocardiography. *Eur Heart J Cardiovasc Imaging* 2017;18:254-275.
 20. Lang RM, Badano LP, Mor-Avi V, Afilalo J, Erande L, Flachskampf FA, Foster E, Goldstein SA, Kuznetsova T, Lancellotti P, Muraru D, Picard MH, Rietzschel ER, Rudski L, Spencer KT, Tsang W, Voigt JU. Recommendations for cardiac chamber quantification by echocardiography in adults: an update from the American Society of Echocardiography and the European Association of Cardiovascular Imaging. *Eur Heart J* 2015;16:233-271.
 21. Parasuraman S, Walker S, Loudon BL, Gollop ND, Wilson AM, Lowery C, Frennaux MP. Assessment of pulmonary artery pressure by echocardiography – a comprehensive review. *Int J Cardiol Heart Vasc* 2016;12:45-51.
 22. Mikami Y, Kolman L, Joncas SX, Stirrat J, Scholl D, Rajchl M, Lydell CP, Weeks SG, Howarth AG, White JA. Accuracy and reproducibility of semi-automated late gadolinium enhancement quantification techniques in patients with hypertrophic cardiomyopathy. *J Cardiovasc Magn Reson* 2014;16:1-9.
 23. Flett A, Hasleton J, Cook C, Hausenloy D, Quarta G, Ariti C, Muthurangu V, Moon JC. Evaluation of techniques for the quantification of myocardial scar of differing etiology using cardiac magnetic resonance. *JACC Cardiovasc Imaging* 2011;4:150-156.
 24. Azevedo CF, Nigri M, Higuchi ML, Pomerantzeff PM, Spina GS, Sampaio RO, Tarasoutchi F, Grinberg M, Rochitte CE. Prognostic significance of myocardial fibrosis quantification by histopathology and magnetic resonance imaging in patients with severe aortic valve disease. *J Am Coll Cardiol* 2010;56:278-287.
 25. Ismail TF, Jabbour A, Gulati A, Mallorie A, Raza S, Cowling TE, Das B, Khwaja J, Alpendurada FD, Wage R, Roughton M, McKenna WJ, Moon JC, Varnava A, Shakespeare C, Cowie MR, Cook SA, Elliott P, O'Hanlon R, Pennell DJ, Prasad SK. Role of late gadolinium enhancement cardiovascular magnetic resonance in the risk stratification of hypertrophic cardiomyopathy. *Heart* 2014;100:1851-1888.
 26. Park CH, Chung H, Kim Y, Kim JY, Min PK, Lee KA, Yoon YW, Kim TH, Lee BK, Hong BK, Rim SJ, Kwon HM, Choi EY. Electrocardiography based prediction of hypertrophy pattern and fibrosis amount in hypertrophic cardiomyopathy: comparative study with cardiac magnetic resonance imaging. *Int J Cardiovasc Imaging* 2018;34:1619-1628.
 27. Shaper AG, Hutt MSR, Coles RM. Necropsy study of endomyocardial fibrosis and rheumatic heart disease in Uganda 1950-1965. *Brit Heart J* 1968;30:391-401.
 28. Moon JC, Reed E, Sheppard MN, Elkington AG, Ho SY, Burke M, Petrou M, Pennell DJ. The histologic basis of late gadolinium enhancement cardiovascular magnetic resonance in hypertrophic cardiomyopathy. *J Am Coll Cardiol* 2004;43:2260-2264.
 29. Cunningham MW. Rheumatic fever, autoimmunity, and molecular mimicry: the streptococcal connection. *Int Rev Immunol* 2014;33:314-329.
 30. Therkelsen SK, Groenning BA, Svendsen JH, Jensen GB. Atrial and ventricular volume and function in persistent and permanent atrial fibrillation, a magnetic resonance imaging study. *J Cardiovasc Magn Reson* 2005;7:465-473.
 31. Hundley WG, Meshack BM, Willett DL, Sayad DE, Lange RA, Willard JE, Landau C, Hills LD, Peshock RM. Comparison of quantification of left ventricular volume, ejection fraction, and cardiac output in patients with atrial fibrillation by cine magnetic resonance imaging versus invasive measurements. *Am J Cardiol* 1996;78:1119-1123.
 32. Hyllen S, Nozohoor S, Ingvarsson A, Meurling C, Wierup P, Sjogren J. Right ventricular performance after valve repair for chronic degenerative mitral regurgitation. *Ann Thorac Surg* 2014;98:2023-2030.
 33. Nguyen T, Cao L, Mohaved A. Altered right ventricular contractile pattern after cardiac surgery: monitoring of septal function is essential. *Echocardiography* 2014;31:1159-1165.
 34. Singh A, Huang X, Dai L, Wylter D, Alfirevic A, Blackstone EH, Pettersson GB, Duncan AE. Right ventricular function is reduced during cardiac surgery independent of procedural characteristics, reoperative status, or pericardiotomy. *J Thorac Cardiovasc Surg* 2019;159:1430-1438.
 35. Ragnarsson S, Sjogren J, Stagmo M, Wierup P, Nozohoor S. Late right ventricular performance after mitral valve repair assessed by exercise echocardiography. *Gen Thorac Cardiovasc Surg* 2018;66:398-404.
 36. Samet P, Litwak RS, Bernstein WH, Fierer EM, Silverman LM. Clinical and physiologic relationships in mitral valve disease. *Circulation* 1959;19:517-530.
 37. Soesanto AM, Desandri DR, Haykal TM, Kasim M. Association between late gadolinium enhancement and global longitudinal strain in patients with rheumatic mitral stenosis. *Int J Cardiovasc Imaging* 2019;35:781-789.
 38. Moreo A, Ambrosio G, De Chiara B, Pu M, Tran T, Mauri F, Raman SV. Influence of myocardial fibrosis on left ventricular diastolic function: non-invasive assessment by CMR and ECHO. *Circ Cardiovasc Imaging* 2009;2:437-443.