

## Thrombosis Formation in the Apical Aneurysm of a Patient with Apical Hypertrophic Cardiomyopathy

Dear Editor,

A 60-year-old man, a known case of apical hypertrophic cardiomyopathy (HCM) with an apical aneurysm formation of many years' duration, presented to our emergency department with atypical chest pains. Electrocardiography showed no new changes compared with previous ones, which featured a tall R-wave, a deep negative T-wave, and ST-segment depression in the precordial leads. The level of high-sensitive troponin T on admission was slightly elevated; however, the rise in the level 1 hour following admission relative to the admission value was not significant. The patient was, therefore, discharged and referred to the HCM

clinic. Transthoracic echocardiography revealed the presence of thrombosis in the left ventricular (LV) apical aneurysm (Figure 1A and 1B, Video 1). The LV ejection fraction was about 40% to 45%, denoting no changes compared with previous echocardiography, and the intraventricular gradient was 24 mmHg. Coronary computed tomography angiography revealed mild atherosclerotic plaques in the coronary artery and confirmed the presence of the apical LV thrombosis (Figure 1C). Rivaroxaban (as an off-label drug for LV thrombosis) was added to the patient's drug regimen after a complete interactive discussion regarding various drug options. Follow-up echocardiography after about 2 months demonstrated a significant reduction in the thrombosis bulk (Figure 1D and 1E, Video 2). While thrombosis formation in the LV apex in patients following myocardial infarctions or in patients with heart failure with a reduced ejection fraction is clearly known, thrombosis formation in an apical HCM setting is not usual. However, given our patient's HCM background, his LV ejection fraction was significantly reduced.

The prevalence rate of apical aneurysms in patients with HCM is less than 5%, and fewer than 2% of these aneurysms are accompanied by thrombosis.<sup>1</sup> It is, therefore, a rare condition. Whereas some believe that the presence of mid-

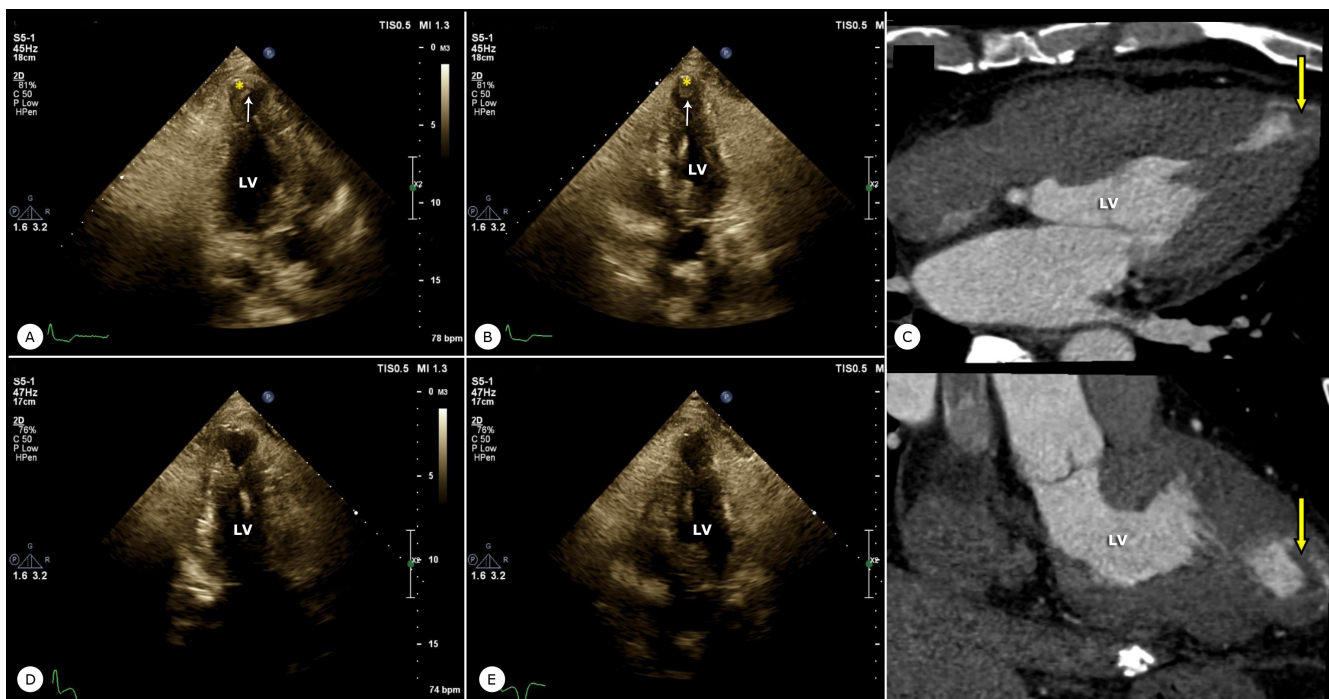


Figure 1. Thrombosis in the left ventricular apical aneurysm in the presence of apical hypertrophic cardiomyopathy in transthoracic echocardiography in the apical 3- and 5-chamber views (A and B, respectively) and cardiac computed tomography angiography (C) is shown. Significant thrombosis bulk reduction after treatment in the apical 3- and 5-chamber views of transthoracic echocardiography is illustrated (D and F, respectively).

LV, Left ventricle; Arrows point to left ventricular apical thrombosis



cavity obstruction leads to apical aneurysm formation, others maintain that the myocardial damage process is a major etiology for aneurysm formation and blood stagnation seems to be the main mechanism for thrombosis formation in aneurysms.<sup>2</sup> Although direct oral anticoagulant administration in LV thrombosis is off-label, there are several reports regarding the successful resolution of apical aneurysm thrombosis in patients with HCM by direct oral anticoagulants administration.<sup>2-4</sup> In patients with HCM, it is advisable that apical aneurysm formation be investigated, and indeed if there is such a formation, the presence of thrombosis be taken into account.

Tel: +98 21 88029731.

Fax: +98 21 88029731.

E-mail: a-hosseinsabet@tums.ac.ir.

### ***To watch the following videos, please refer to the relevant URLs:***

<https://jthc.tums.ac.ir/index.php/jthc/article/view/1258/956>

Video 1. Thrombosis in the left ventricular apical aneurysm in the presence of apical hypertrophic cardiomyopathy in transthoracic echocardiography is demonstrated.

<https://jthc.tums.ac.ir/index.php/jthc/article/view/1258/957>

Video 2. Significant reduction of the apical thrombosis bulk after treatment in transthoracic echocardiography is shown.

### ***References***

1. Rowin EJ, Maron BJ, Haas TS, Garberich RF, Wang W, Link MS, Maron MS. Hypertrophic cardiomyopathy with left ventricular apical aneurysm: implications for risk stratification and management. *J Am Coll Cardiol* 2017;69:761-773.
2. Hamada M. Left ventricular thrombus in hypertrophic cardiomyopathy. *Intern Med* 2019;58:465-467.
3. Kaku B. Intra-cardiac thrombus resolution after anti-coagulation therapy with dabigatran in a patient with mid-ventricular obstructive hypertrophic cardiomyopathy: a case report. *J Med Case Rep* 2013;7:238.
4. Kaya A, Hayiroğlu Mİ, Keskin M, Tekkeşin Aİ, Alper AT. Resolution of left ventricular thrombus with apixaban in a patient with hypertrophic cardiomyopathy. *Turk Kardiyol Dern Ars* 2016;44:335-337.

#### ***Ali Hosseinsabet, MD\****

Associate Professor of Cardiology,

Tehran Heart Center,

North Karegar Street,

Tehran,

Iran.

1411713138.