



Left-Sided Endocarditis Associated with Multi-Drug Resistance *Acinetobacter Lwoffii*

Hossein Ahmadi, MD, Mohammad Ali Boroumand, MD, Maryam Sotoudeh Anvari, MD*, Abbasali Karimi, MD, Naghmeh Moshtaghi, MD

Tehran Heart Center, Tehran University of Medical Sciences, Tehran, Iran.

Received 15 April 2008; Accepted 14 August 2008

Abstract

Acinetobacter lwoffii, an important nosocomial pathogen, is a gram-negative aerobic bacillus that is a component of the normal flora on the skin, oropharynx, and perineum of about 20-25% of healthy individuals. We herein present a case of a 66-year-old man with combined mitral and aortic valve endocarditis associated with multi-drug resistance *acinetobacter lwoffii* bacteremia.

J Teh Univ Heart Ctr 3 (2009) 189-192

Keywords: *Acinetobacter* • Drug resistance, multiple • Endocarditis

Introduction

Infections begotten by *acinetobacter* spp have gained wide attention as a result of the resistance which this common nosocomial pathogen exhibits to several antimicrobial agents. Bacteremia secondary to *acinetobacter* spp is associated with mortality rates as high as 40% to 50%, especially in patients hospitalized in the intensive care unit undergoing invasive procedures and usually suffering from ventilator-associated pneumonia caused by this pathogen.¹

Endocarditis due to *acinetobacter* spp has been described in only a few sporadic cases.²⁻⁴ We present a case of left-sided endocarditis associated with *acinetobacter lwoffii* bacteremia.

Case report

A 66-year-old man with a history of hypertension was admitted to our hospital for an evaluation of aortic and mitral valve endocarditis. Two years previously, after myocardial infarction (MI) the patient had percutaneous coronary

intervention on his right coronary artery. His fever commenced approximately 4 months prior to his admission. In the period of MI and onset of fever, the patient experienced an episode of long-term pneumonia. Two weeks before he referred to us, he had visited a local clinic while having a temperature of 38.5°C, dyspnea, and coughs. Echocardiography revealed vegetation on the aortic valve with severe insufficiency and mitral valve regurgitation. For 10 days, cefazolin, amikacin, and ciprofloxacin were prescribed empirically for him. The patient was thereafter referred to our hospital for cardiac surgery.

In our hospital, the patient was afebrile. However, three sets of blood cultures in sterile condition were obtained, all of which yielded *acinetobacter lwoffii* sensitive to amikacin, ciprofloxacin, and gentamycin, and resistant to ceftazidime, tobramycin, cefepime, and imipenem on disc diffusion method; the case was, therefore, considered multidrug resistance. The interpretative criteria were in accordance with the CLSI (Clinical and Laboratory Standard Institute) guidelines. At surgery, the patient's mitral and aortic valves were replaced with prosthetic ST Jude 27 and ST Jude

*Corresponding Author: *Maryam Sotoudeh Anvari*, Surgical and Clinical Pathologist, Tehran Heart Center, Tehran University of Medical Sciences, North Kargar Street, Tehran, Iran. 1411713138. Tel: +98 21 88029256. Fax: +98 21 88029256. E-mail: maryamsotoudeh2006@yahoo.com.

Regent 21, respectively. The mitral and aortic valves were subsequently transferred for a pathological examination, and the cultures of both of them were negative. The macroscopic examination of the mitral valve revealed a thickened leaflet with attached chordae, measuring 3×2×0.5 cm with an area of perforation measuring 0.5 cm in the diameter near the line of closure and loose consistency in other areas. The aortic valve, measuring 3.3×1.2×0.3 cm, showed severe deformity and multiple creamy-color vegetations on the line of closure and atrial surface.

The microscopic examination of the mitral valve revealed multiple areas of granulation tissue formation at the base with surface lympho-histiocytic infiltration on the line of closure, but colonies of micro organisms in routine staining (H & E) were not seen. In the aortic

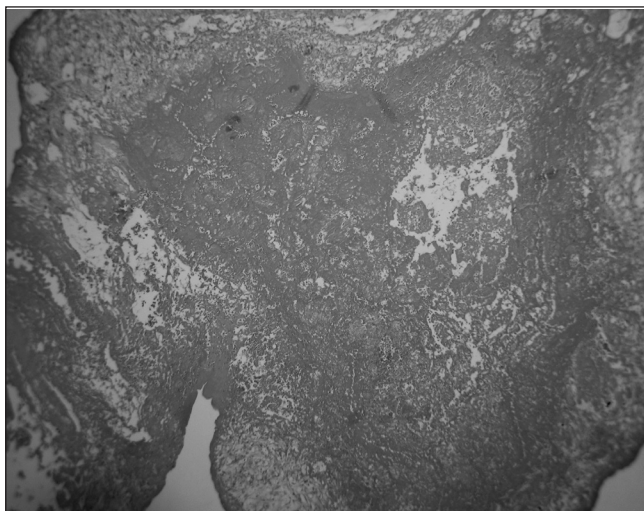


Figure 1. Histopathological feature of aortic valve consisting of acute vegetation with extensive fibrin and scant inflammatory cells

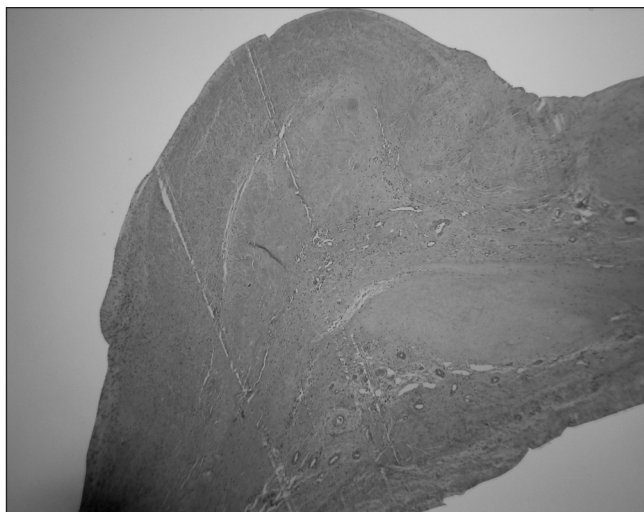


Figure 2. Mitral valve organizing, healing vegetation containing varying degrees of granulation tissue

valve, acute vegetations consisted of fibrinous material, and necrotic debris and neutrophils were present.

Finally, the diagnosis of acute and subacute endocarditis was made for the aortic and mitral valves, respectively (Figure 1, 2).

About 2 weeks post-operatively, the patient was discharged uneventfully; and almost 2 months after the operation, he remains in excellent condition.

Discussion

Acinetobacter has been found to be responsible for various types of opportunistic infections, including septicemia, pneumonia, endocarditis, meningitis, wound sepsis, and urinary tract infections.⁵ All species can cause nosocomial and community-acquired infections, but endocarditis by acinetobacter spp is very unusual.⁶ acinetobacter spp has also been found in the oral cavity, respiratory tract, and gastrointestinal tract of healthy adults; be that as it may, the carriage rate in non-hospitalized patients apart from the skin is generally low.⁷ Most cases of acinetobacter infection occur in patients with impaired immune systems. Risk factors contributing to reduced patient resistance include malignancy, burns, immunosuppression, and major surgery. Occasionally, sporadic cases occur in healthy individuals exposed to environmental sources. Luciano Tega et al.⁸ found the role of catheters as the principal source of acinetobacter lwoffii infections. Also, they defined multi-drug resistance acinetobacter lwoffii isolated as resistance to ≥ 4 classes of drugs.

Many studies have documented the high rates of antibiotic resistance found in acinetobacter spp.⁹ High proportions of clinical acinetobacter isolates are now resistance to aminopenicillins, ureidopenicillins, narrow-spectrum and expanded-spectrum cephalosporins, cephamycins such as cefoxitin, most aminoglycosides, chloramphenicol, and tetracyclines.¹⁰ For some relatively new antibiotics such as broad-spectrum cephalosporins (cefotaxime, ceftazidime, and cefepime), imipenem, amikacin, tobramycin, and fluoroquinolones, partial susceptibility is retained; nevertheless, the MICs of these antibiotics for acinetobacter isolates have substantially increased during the last decade.⁶

Conclusion

It was difficult to explain the source of acinetobacter lwoffii-related bacteremia in our case. Except for percutaneous coronary intervention, which had been carried out about two years previously, the patient did not have any manipulation before his recent bacteremia. We would, nonetheless, posit that an insidious course of the disease must have reactivated the colonization of this microorganism.



References

1. Rizos I, Tsiodras S, Papathanasiou S, Rigopoulos A, Barbetseas J, Stefanadis C. Prosthetic valve endocarditis due to acinetobacter spp: a rare case and literature review. *Am J Med Sci* 2007;333:197-199.
2. Gradon JD, Chapnick EK, Lutwick LI. Infective endocarditis of a native valve due to acinetobacter: case report and review. *Clin Infect Dis* 1992;14:1145-1148.
3. Malik AS. Acinetobacter endocarditis in children: a case report and review of the literature. *Infection* 1995;23:306-308.
4. Weinberger I, Davidson E, Rotenberg Z, Fuchs J, Agmon J. Prosthetic valve endocarditis caused by acinetobacter calcoaceticus subsp. lwoffii. *J Clin Microbiol* 1987;25:955-957.
5. Rathinavelu S, Zavros Y, Merchant JL. Acinetobacter lwoffii infection and gastritis. *Microbes and Infection* 2003;5:651-657.
6. Starakis I, Blikas A, Siagris D, Marangos M, Karatza C, Bassaris H. Prosthetic valve endocarditis caused by acinetobacter lwoffii: a case report and review. *Cardiol Rev* 2006;14:45-49.
7. Gaughan M, White PM, Noble WC. Skin as a source of acinetobacter/moraxella species. *J Clin Pathol* 1979;32:1193.
8. Tega L, Raieta K, Ottaviani D, Russo GL, Blanco G, Carraturo A. Catheter-related bacteremia and multidrug-resistant acinetobacter lwoffii. *Emerg Infect Dis* 2007;13:355-356.
9. Struelens MJ, Carlier E, Maes N, Serruys E, Quint WG, vanBelkum A. Nosocomial colonization and infection with multiresistant acinetobacter baumannii: outbreak delineation using DNA macrorestriction analysis and PCR- fingerprinting. *J Hosp Infect* 1993;25:15-32.
10. Joly-Guillou ML, Bergogne-Berezin E. Evolution of acinetobacter calcoaceticus in the hospital milieu, from 1971 to 1984. *Presse Med* 1985;14:2331-2335.

