



Remdesivir-Associated Significant Bradycardia: A Report of Three Cases

Maria Shirvani, MD¹, Babak Sayad, MD¹, Lida Shojaei, PharmD², Azadeh Amini, PharmD³, Foroud Shahbazi, PharmD^{2*}

¹Infectious Diseases Research Center, Kermanshah University of Medical Sciences, Kermanshah, Iran.

²Department of Clinical Pharmacy, Faculty of Pharmacy, Kermanshah University of Medical Sciences, Kermanshah, Iran.

³Department of Pharmaceutical Biomaterials and Medical Biomaterials Research Center, Faculty of Pharmacy, Tehran University of Medical Sciences, Tehran, Iran.

Received 11 January 2021; Accepted 24 March 2021

Abstract

Recently, remdesivir was approved by the United States Food and Drug Administration for patients with Coronavirus disease 2019 (COVID-19). We herein describe 3 patients with COVID-19 who showed significant bradycardia and QTc prolongation after remdesivir administration. Bradycardia did not respond to atropine treatment in 2 of the patients, one of whom received theophylline and the other required a temporary pacemaker. Fortunately, the patients' heart rate and rhythm returned to normal after the discontinuation of remdesivir, albeit it lengthened their hospital stays. Careful monitoring during remdesivir infusion may decrease the risk of adverse cardiovascular side effects.

J Teh Univ Heart Ctr 2021;16(2):79-83

This paper should be cited as: Shirvani M, Sayad B, Shojaei L, Amini A, Shahbazi F. Remdesivir-Associated Significant Bradycardia: A Report of Three Cases. *J Teh Univ Heart Ctr* 2021;16(2):79-83.

Keywords: Arrhythmias, cardiac; Bradycardia; COVID-19; Remdesivir

Introduction

Coronavirus disease 2019 (COVID-19) is a global pandemic that affects various organs and has caused more than 2.6 million deaths as of 11 March 2021. It has numerous pulmonary and extra-pulmonary manifestations including renal, hepatic, cardiac, endocrine, gastrointestinal, dermatological, and thromboembolic.¹

Several medications have been investigated for the treatment and management of patients with COVID-19, and supportive care has an important role for hospitalized patients.²

Recently, remdesivir was approved by the United States Food and Drug Administration for patients suffering from

COVID-19. Treatment with remdesivir may shorten the duration of patients' hospital stays, especially those receiving this agent within the first 10 days of symptom initiation.³ Nonetheless, no in-hospital mortality benefit has been seen with remdesivir,³⁻⁵ nor has the safety of this agent been fully understood. Here, we describe 3 patients who experienced significant bradycardia associated with this remdesivir.

Case Reports

Case #1

A 52-year-old man with a history of dyslipidemia

*Corresponding Author: Foroud Shahbazi, Assistant Professor of Clinical Pharmacy, Department of Clinical Pharmacy, Faculty of Pharmacy, Building No. 1, Kermanshah University of Medical Sciences (KUMS), Shahid Beheshti Boulevard, Kermanshah, Iran. 6734667149. Tel: +98 83 34276489. Fax: +98 83 34276489. E-mail: foroud08@gmail.com.



who presented with cough and fever was admitted to the emergency department. Upon his arrival, the patient had a respiratory rate of 22 beats/min, a blood pressure (BP) of 130/80 mmHg, and a heart rate of 110 beats/min. Initial evaluation showed an oxygen saturation of 89%, and computed tomography (CT) scan findings showed bilateral ground-glass opacification. Laboratory data revealed leukopenia ($3.8 \times 10^9/l$) and positive COVID-19 polymerase chain reaction (PCR) and qualitative C-reactive protein (CRP) tests. All other lab data were normal.

With a possible diagnosis of COVID-19, dexamethasone (16 mg/d) and remdesivir were administered. Other agents prescribed were pantoprazole, doxycycline, heparin, atorvastatin, and diphenhydramine. On day 4 of remdesivir therapy, the patient experienced dizziness, diaphoresis, and significant bradycardia (heart rate=37 beats/min and QTc interval=313 ms). Therefore, remdesivir was discontinued, and supportive therapy, including hydration and atropine, was initiated.

Unfortunately, bradycardia was not resolved following atropine treatment. Therefore, the patient was transferred to a specialized heart center, where he underwent the implantation of a temporary pacemaker. Forty-eight hours after the pacemaker insertion, the patient's heart rate was increased, and the pacemaker was removed. Finally, 3 days after the discontinuation of remdesivir, he was discharged from the hospital with a normal heart rate (90–95 beats/min and QTc interval=335 ms) and an oxygen saturation level of 96%.

Case #2

A 52-year-old woman with a history of fever, shivering, and shortness of breath was admitted to our hospital. Her

medical history showed diabetes and hypothyroidism. Upon her arrival, she had a blood pressure of 120/80 mmHg, a respiratory rate of 16 beats/min, and a heart rate of 83 beats/min.

The patient had leukocytosis ($11 \times 10^9/l$) and positive COVID-19 PCR and qualitative CRP tests. A CT scan showed ground-glass opacification. Other laboratory data were normal. Remdesivir, dexamethasone (16 mg/d), heparin at prophylactic doses, insulin, levothyroxine, and pantoprazole were administered.

After 3 doses of remdesivir, the patient experienced chest pain, critical bradycardia (heart rate=23 beats/min), and QTc prolongation (533 ms). Remdesivir was immediately discontinued, and atropine was injected. Unfortunately, the patient did not respond, and she was transferred to the specialized heart center for more interventions.

At the heart center, dexamethasone, levothyroxine, and heparin were continued. In addition, theophylline was initiated. Four hours after remdesivir discontinuation and theophylline administration, the patient's heart rate increased to 45 beats/min. She was discharged with an oxygen saturation level of 96% and a heart rate of 55 beats/min 2 days after her admission.

Case #3

A 59-year-old man with a 3-day history of dyspnea, cough, and fever was admitted to the hospital with an oxygen saturation level of 88%. His vital signs upon arrival were a respiratory rate of 24 beats/min, a blood pressure of 130/80 mmHg, and a heart rate of 125 beats/min (Figure 1). A CT scan showed ground-glass opacification. The patient had lymphopenia and positive COVID-19 PCR and qualitative CRP tests. Other lab data were within the normal range.

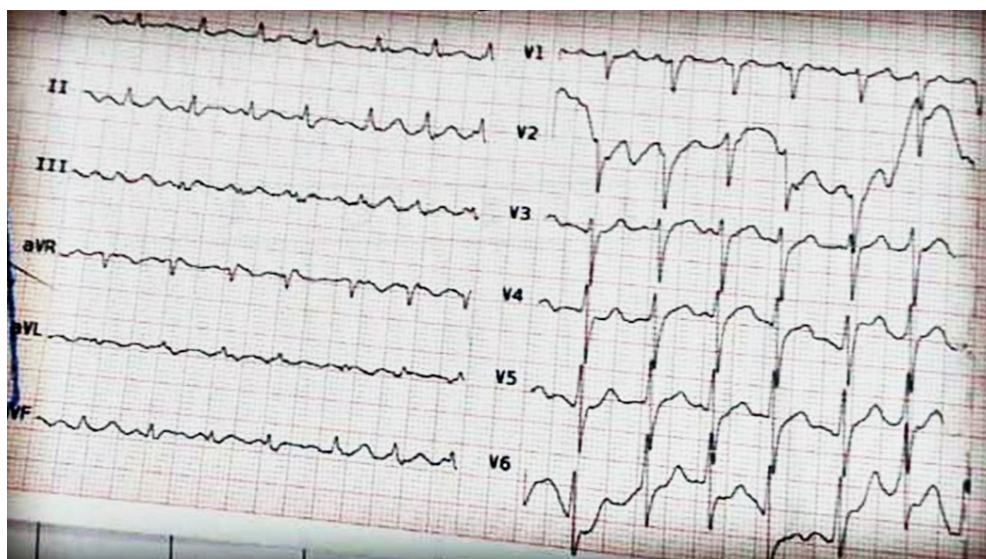


Figure 1. The image depicts the baseline electrocardiogram (speed =25 mm/s) of a 59-year-old man, 1 hour before he received remdesivir for COVID-19 (heart rate=125 beats/min and QTc=404 ms).

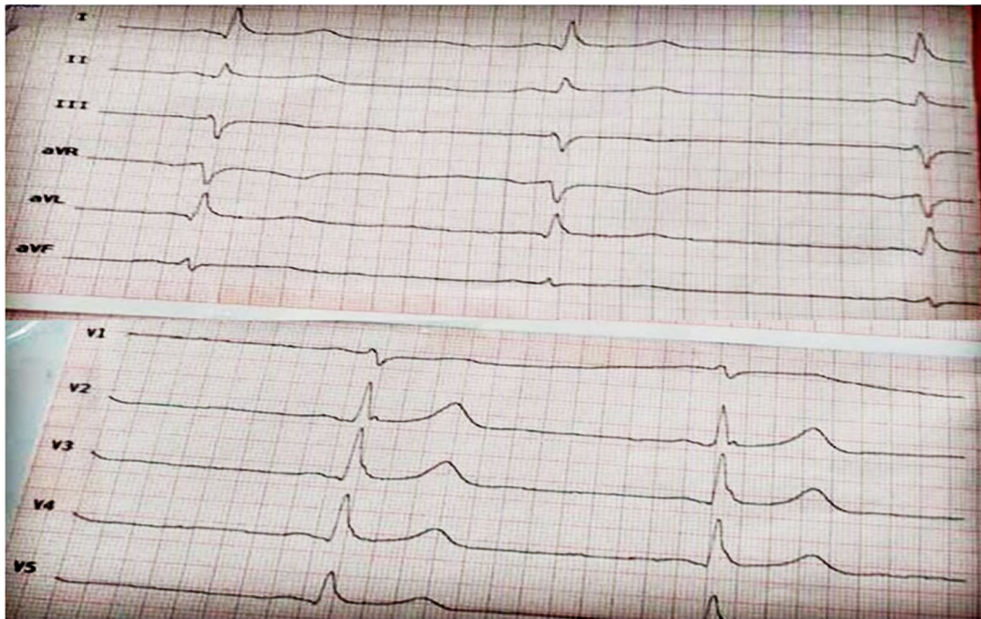


Figure 2. The images show the electrocardiograms (speed =25 mm/s) of a 59-year-old man, 20 minutes after the third dose of remdesivir for COVID-19 (heart rate =30 beats/min and QTc =548 ms).

With a diagnosis of COVID-19, remdesivir, heparin, dexamethasone, doxycycline, and pantoprazole were prescribed. The loading and second doses of remdesivir were tolerated well. However, 20 minutes after the third dose, the patient experienced sweating, bradycardia (heart rate=30 beats/min), and QTc prolongation (548 ms) (Figure 2). With supportive care and atropine, the patient was hemodynamically stabilized, and remdesivir was discontinued after 3 doses.

Discussion

Since the outbreak of COVID-19, several complications related to this disease or its treatment have been reported.²⁻⁶ Cardiovascular complications, including QTc prolongation and sudden cardiac death, were initially seen due to hydroxychloroquine/chloroquine treatment.⁶ Owing to a lack of clear evidence, hydroxychloroquine is not recommended by the current guidelines.^{7,8}

Since gaining the approval of the United States Food and Drug Administration, remdesivir has been commonly used in our center and has recently been covered by insurance for inpatient use in Iran. Remdesivir is commonly used alongside intravenous corticosteroids (high, very high, and pulse equivalent doses) and interferon β 1a in our hospital. Remdesivir is a nucleoside prodrug analog that is phosphorylated intracellularly to the active metabolite rapidly, consequently inhibiting RNA-dependent RNA polymerase.^{9,10}

The patients described in this paper received no other negative chronotropic agents, and they experienced

significant bradycardia 3 to 4 days after remdesivir initiation. Remdesivir triphosphate, the active metabolite of remdesivir, has an elimination half-life of 35 to 40 hours. Therefore, a loading dose is necessary to achieve an effective concentration.¹⁰ Remdesivir is an adenosine analog and could, theoretically, slow atrioventricular (AV) conduction.¹¹ Adenosine slows atrioventricular conduction by stimulating adenosine receptors (ie, A1, A2A, A2B, and A3 receptors).¹²

The safety profile of remdesivir was investigated in a multicenter study. No significant differences were observed between remdesivir and placebo groups regarding acute kidney injury, anemia, lymphopenia, respiratory failure, pyrexia, hyperglycemia, and cardiac events.³

Remdesivir warnings are hypersensitivity reactions (ie, bradycardia, hypotension, dyspnea, and angioedema), hepatotoxicity, and potential drug interactions with chloroquine and hydroxychloroquine.¹³ Notably, slower infusions (eg, over 120 min) can be considered to minimize the risk of hypersensitivity reactions. In our hospital, remdesivir is usually infused over 120 minutes for all patients. Due to significant bradycardia in our patients described herein, remdesivir was discontinued.

One of the patients experienced severe bradycardia and subsequently needed a temporary pacemaker. There are a few reports of remdesivir-induced bradycardia in the literature.^{11,14} Gubitosa et al¹¹ reported a case of remdesivir-associated bradycardia and QRS prolongation in a patient with underlying left bundle branch block and lymphoma.¹⁴ Gupta et al¹⁴ reported 2 cases of bradycardia, one of whom experienced QTc prolongation.

Whether remdesivir prolongs QTc remains to be elucidated. In the above reports, cardiac adverse effects

were resolved very quickly after remdesivir discontinuation. Still, in 2 of our patients, bradycardia was not resolved immediately after remdesivir discontinuation and atropine treatment (eg, 0.5 mg every 5 min for 3 doses). One reason for this delay might be the prolonged terminal half-life of remdesivir active triphosphate metabolites.^{9,10} Mitochondrial dysfunctions associated with the inhibition of mitochondrial polymerase could be another proposed effect of remdesivir-induced bradycardia.¹⁵

The QTc interval was prolonged in 2 of our cases. Both of them had normal serum potassium, magnesium, and glucose levels, and they received no other medication that might have predisposed them to arrhythmia. The association between remdesivir and the QTc interval prolongation has been observed in a few reports.^{14, 16-17} In a recent study, 9% of patients (6/67) who received remdesivir had QTc interval prolongation. Their analysis showed that receiving remdesivir alone was not a predictor of the QTc interval prolongation.¹⁷

The potential of remdesivir to block the rapid delayed rectifier (IKr) channel can be considered the main mechanism of the QTc interval prolongation. Accordingly, cardiac monitoring might be reasonable during remdesivir intravenous administration.¹⁶

Remdesivir should be prepared according to the product information. Vigorous shaking and improper storage may increase free adenosine concentrations and consequently increase the risk of bradycardia.

Corticosteroids are among the agents that can cause bradycardia.¹⁸ Direct corticosteroids on the myocardium, altered responses to catecholamines, and electrolyte shifts are among the proposed mechanisms underlying corticosteroids associated with bradycardia.¹⁹ In our patients, corticosteroid was not discontinued.

Relative bradycardia is a common finding in patients with COVID-19.²⁰ This can be mediated via the ACE2 receptor activation in the sinoatrial node by severe acute respiratory syndrome coronavirus 2 (SARS-CoV-2). Amaratunga et al²⁰ highlighted 4 cases of significant bradycardia (heart rate=49, 46, 46, and 42 beats/min) in patients without a pre-existing disease. Relative bradycardia could be a warning sign of cytokine storms and severe pneumonia.²⁰ Nevertheless, our patients had normal heart rates at the time of admission and pre-remdesivir initiation.

Favipiravir and sofosbuvir are other antiviral agents that are commonly used for COVID-19. They might increase the risk of bradycardia. Clinicians should be aware of bradycardia associated with remdesivir.

Robust evidence is not available regarding remdesivir-induced bradycardia. Significant bradycardia precluded us from studying this link. Nonetheless, our case series and previous reports highlight the need for more cardiac monitoring of patients who receive remdesivir and more

focus on the adverse cardiovascular effects of this drug.

Conclusion

Given that no mortality benefit is associated with remdesivir and considering the efficacy in the earlier stage of the disease, remdesivir should be restricted to patients who are in the viral replication phase with no contraindication. Observational and post-marketing studies are needed to determine the cardiac safety of remdesivir. Additionally, there is a need to include a new black box warning on its monograph.

References

1. Gupta A, Madhavan MV, Sehgal K, Nair N, Mahajan S, Sehrawat TS, Bikdeli B, Ahluwalia N, Ausiello JC, Wan EY, Freedberg DE, Kirtane AJ, Parikh SA, Maurer MS, Nordvig AS, Accili D, Bathone JM, Mohan S, Bauer KA, Leon MB, Krumholz HM, Uriel N, Mehra MR, Elkind MSV, Stone GW, Schwartz A, Ho DD, Bilezikian JP, Landry DW. Extrapulmonary manifestations of COVID-19. *Nat Med* 2020;26:1017-1032.
2. Sanders JM, Monogue ML, Jodlowski TZ, Cutrell JB. Pharmacologic treatments for Coronavirus disease 2019 (COVID-19): a Review. *JAMA* 2020;323:1824-1836.
3. Beigel JH, Tomashek KM, Dodd LE, Mehta AK, Zingman BS, Kallil AC, Hohmann E, Chu HY, Luetkemeyer A, Kline S, Lopez de Castilla D, Finberg RW, Dierberg K, Tapson V, Hsieh L, Patterson TF, Paredes R, Sweeney DA, Short WR, Touloumi G, Lye DC, Ohmagari N, Oh MD, Ruiz-Palacios GM, Benfield T, Fätkenheuer G, Kortepeter MG, Atmar RL, Creech CB, Lundgren J, Babiker AG, Pett S, Neaton JD, Burgess TH, Bonnett T, Green M, Makowski M, Osinusi A, Nayak S, Lane HC; ACTT-1 Study Group Members. Remdesivir for the Treatment of Covid-19 - Final Report. *N Engl J Med* 2020;383:1813-1826.
4. Dyer O. Covid-19: Remdesivir has little or no impact on survival, WHO trial shows. *BMJ* 2020;371:m4057.
5. WHO Solidarity Trial Consortium; Pan H, Peto R, Heno-Restrepo AM, Preziosi MP, Sathiyamoorthy V, Abdool Karim Q, Alejandria MM, Hernández García C, Kieny MP, Malekzadeh R, Murthy S, Reddy KS, Roses Periago M, Abi Hanna P, Ader F, Al-Bader AM, Alhasawi A, Allum E, Alotaibi A, Alvarez-Moreno CA, Appadoo S, Asiri A, Aukrust P, Barratt-Due A, Bellani S, Branca M, Cappel-Porter HBC, Cerrato N, Chow TS, Como N, Eustace J, García PJ, Godbole S, Gotuzzo E, Griskevicius L, Hamra R, Hassan M, Hassany M, Hutton D, Irmansyah I, Jancoriene L, Kirwan J, Kumar S, Lennon P, Lopardo G, Lydon P, Magrini N, Maguire T, Manevska S, Manuel O, McGinty S, Medina MT, Mesa Rubio ML, Miranda-Montoya MC, Nel J, Nunes EP, Perola M, Portolés A, Rasmin MR, Raza A, Rees H, Reges PPS, Rogers CA, Salami K, Salvadori MI, Sinani N, Sterne JAC, Stevanovikj M, Tacconelli E, Tikkinen KAO, Trelle S, Zaid H, Røttingen JA, Swaminathan S. Repurposed antiviral drugs for Covid-19 - interim WHO solidarity trial results. *N Engl J Med* 2021;384:497-511.
6. Bonow RO, Hernandez AF, Turakhia M. Hydroxychloroquine, Coronavirus disease 2019, and QT prolongation. *JAMA Cardiol* 2020;5:986-987.
7. Bhimraj A, Morgan RL, Shumaker AH, Lavergne V, Baden L, Cheng VC, Edwards KM, Gandhi R, Muller WJ, O'Horo JC, Shoham S, Murad MH, Mustafa RA, Sultan S, Falck-Ytter Y. Infectious Diseases Society of America guidelines on the treatment and management of patients with COVID-19. *Clin Infect Dis* 2020:ciaa478.



8. RECOVERY Collaborative Group; Horby P, Lim WS, Emberson JR, Mafham M, Bell JL, Linsell L, Staplin N, Brightling C, Ustianowski A, Elmahi E, Prudon B, Green C, Felton T, Chadwick D, Rege K, Fegan C, Chappell LC, Faust SN, Jaki T, Jeffery K, Montgomery A, Rowan K, Juszczak E, Baillie JK, Haynes R, Landray MJ. Dexamethasone in hospitalized patients with Covid-19. *N Engl J Med* 2021;384:693-704.
9. Jorgensen SCJ, Kebriaei R, Dresser LD. Remdesivir: review of pharmacology, pre-clinical data, and emerging clinical experience for COVID-19. *Pharmacotherapy* 2020;40:659-671.
10. Aleissa MM, Silverman EA, Paredes Acosta LM, Nutt CT, Richterman A, Marty FM. New perspectives on antimicrobial agents: remdesivir treatment for COVID-19. *Antimicrob Agents Chemother* 2020;65:e01814-01820.
11. Gubitosa JC, Kakar P, Gerula C, Nossa H, Finkel D, Wong K, Khatri M, Ali H. Marked sinus bradycardia associated with remdesivir in COVID-19: a case and literature review. *JACC Case Rep* 2020;2:2260-2264.
12. Layland J, Carrick D, Lee M, Oldroyd K, Berry C. Adenosine: physiology, pharmacology, and clinical applications. *JACC Cardiovasc Interv* 2014;7:581-591.
13. Fan Q, Zhang B, Ma J, Zhang S. Safety profile of the antiviral drug remdesivir: An update. *Biomed Pharmacother* 2020;130:110532.
14. Gupta AK, Parker BM, Priyadarshi V, Parker J. Cardiac adverse events with remdesivir in COVID-19 infection. *Cureus* 2020;12:e11132.
15. Varga ZV, Ferdinandy P, Liaudet L, Pacher P. Drug-induced mitochondrial dysfunction and cardiotoxicity. *Am J Physiol Heart Circ Physiol* 2015;309:H1453-1467.
16. Michaud V, Dow P, Al Rihani SB, Deodhar M, Arwood M, Cicali B, Turgeon J. Risk assessment of drug-induced long QT syndrome for some COVID-19 repurposed drugs. *Clin Transl Sci* 2021;14:20-28.
17. Haghjoo M, Golipra R, Kheirkhah J, Golabchi A, Shahabi J, Oni-Heris S, Sami R, Tajmirrahi M, Saravi M, Khatami M, Varnasseri M, Kiarsi M, Hejazi SF, Yousefzadeh Rahaghi M, Taherkhani M, Ashraf H, Keshmiri MS, Akbarzadeh MA, Bozorgi A, Mottaghizadeh F, Hedayat B, Heidarali M, Hajhossein Talasaz A. Effect of COVID-19 medications on corrected QT interval and induction of torsade de pointes: results of a multicenter national survey. *Int J Clin Pract* 2021:e14182.
18. Sodero A, Squitieri M, Mazzeo S, Pasca M, Matà S, Pieri F, Bessi V, Sorbi S. Acute symptomatic sinus bradycardia in high-dose methylprednisolone therapy in a woman with inflammatory myelitis: a case report and review of the literature. *Clin Med Insights Case Rep* 2019;12:1179547619831026.
19. Stroeder J, Evans C, Mansell H. Corticosteroid-induced bradycardia: case report and review of the literature. *Can Pharm J (Ott)* 2015;148:235-240.
20. Amaratunga EA, Corwin DS, Moran L, Snyder R. Bradycardia in patients with COVID-19: a calm before the storm? *Cureus* 2020;12:e8599.