



Discordance between the Clinical Presentation and Morphology of Myocardial Infarction in a Patient with Acute Post-Hemorrhagic Anemia

Truong Huy Hoang, MD^{1*}, Pavel V. Lazarev, MD, PhD¹, Victor V. Maiskov, MD, PhD^{1,2}, Imad Meray, MD, PhD^{1,2}, Zhanna D. Kobalava, MD, DMedSc¹

¹Department of Internal Diseases, Medical Institute, RUDN University, Moscow, Russia.

²Vinogradov City Clinical Hospital, Moscow, Russia.

Received 16 December 2019; Accepted 12 May 2020

Abstract

While atherosclerotic plaque disruption remains the hallmark of type 1 myocardial infarction (T1MI), multiple other mechanisms provoking myocardial supply/demand mismatch (eg, anemia and tachyarrhythmias) are recognized as the potential causes of type 2 myocardial infarction (T2MI). In clinical practice, angiography is underutilized in patients with MI that have typical T2MI triggers, although the presence of these triggers and various forms of atherosclerotic coronary artery disease is not mutually exclusive. We describe a 70-year-old man that developed MI during hospitalization for gastrointestinal bleeding. He was treated conservatively without angiography due to posthemorrhagic anemia, which is a recognized T2MI trigger, and subsequently developed refractory cardiogenic shock. Autopsy revealed atherothrombosis, which is characteristic of T1MI.

J Teh Univ Heart Ctr 2020;15(3):136-141

This paper should be cited as: Hoang TH, Lazarev PV, Maiskov VV, Meray I, Kobalava ZD. Discordance between the Clinical Presentation and Morphology of Myocardial Infarction in a Patient with Acute Post-Hemorrhagic Anemia. *J Teh Univ Heart Ctr* 2020;15(3):136-141.

Keywords: Acute coronary syndrome; Anemia; Coronary angiography; Myocardial infarction; Myocardial ischemia

Introduction

Type 2 myocardial infarction (T2MI) occurs due to myocardial oxygen supply/demand mismatch without acute atherosclerotic plaque disruption and thrombosis, which is characteristic of type 1 myocardial infarction (T1MI).¹ No more than one-third of patients with clinically suspected T2MI undergo coronary angiography (CAG).² However, it may be challenging to determine the type of MI and appropriate management based on clinical assessment

alone and tools other than CAG. We present a fatal case of MI triggered by post-hemorrhagic anemia resulting in cardiogenic shock.

Case Report

A 70-year-old man presented to our hospital with episodes of acute epigastric pain radiating to the retrosternal region,

*Corresponding Author: **Truong Huy Hoang**, Department of Internal Diseases, Medical Institute, RUDN University, Miklukho-Maklaya Street, 6, Moscow, Russia, 117198. Tel: +7 977 4160257. Fax: +7 977 4160257. E-mail: trangxuchin89@gmail.com.





nausea, and 2 passages of black stool in the previous 3 days. A former smoker, the patient had a history of arterial hypertension, peptic ulcer disease, gout, an unspecified stroke 10 years earlier with good neurological recovery, excessive alcohol consumption after retirement (about 500 mL of vodka/week), and a history of several hospitalizations due to exacerbations of peptic ulcer disease over the previous 20 years. His regular medications included bisoprolol (2.5 mg QD), aspirin (50 mg QD), and allopurinol (100 mg QD). He also periodically took various nonsteroidal anti-inflammatory drugs for lower back and joint pain.

On admission, the patient was afebrile and tachycardic (heart rate = 100/min and blood pressure [BP]=115/70 mmHg). Additionally, he had a respiratory rate of 22 per minute and SpO₂ of 96% in the ambient air. His abdomen was soft, although pain in the epigastric region was elicited on palpation. Otherwise, the physical examination was

unremarkable. The baseline electrocardiogram (ECG) demonstrated sinus rhythm with a ST-segment depression of less than 1 mm in I, aVL, and V₄-V₆ leads (Figure 1). Serum troponin I was mildly elevated (0.07 ng/mL [N <0.02 ng/mL]) on admission and 0.08 ng/mL after 6 hours]. Echocardiography showed a preserved left ventricular ejection fraction of 55% with no local wall motion abnormalities. Upper gastrointestinal endoscopy showed an ulcer defect, 6×8 mm in size, on the posterior-upper wall of the duodenum with active oozing bleeding (stage 1B, Forrest classification). Given the presence of acute peptic ulcer disease exacerbation, the ECG findings and the stable serum troponin elevation with an insignificant change (<20%) over time were interpreted as an acute myocardial injury. Immediate endoscopic hemostasis was achieved, and therapy with proton-pump inhibitors (pantoprazole [40 mg BID]) was initiated.

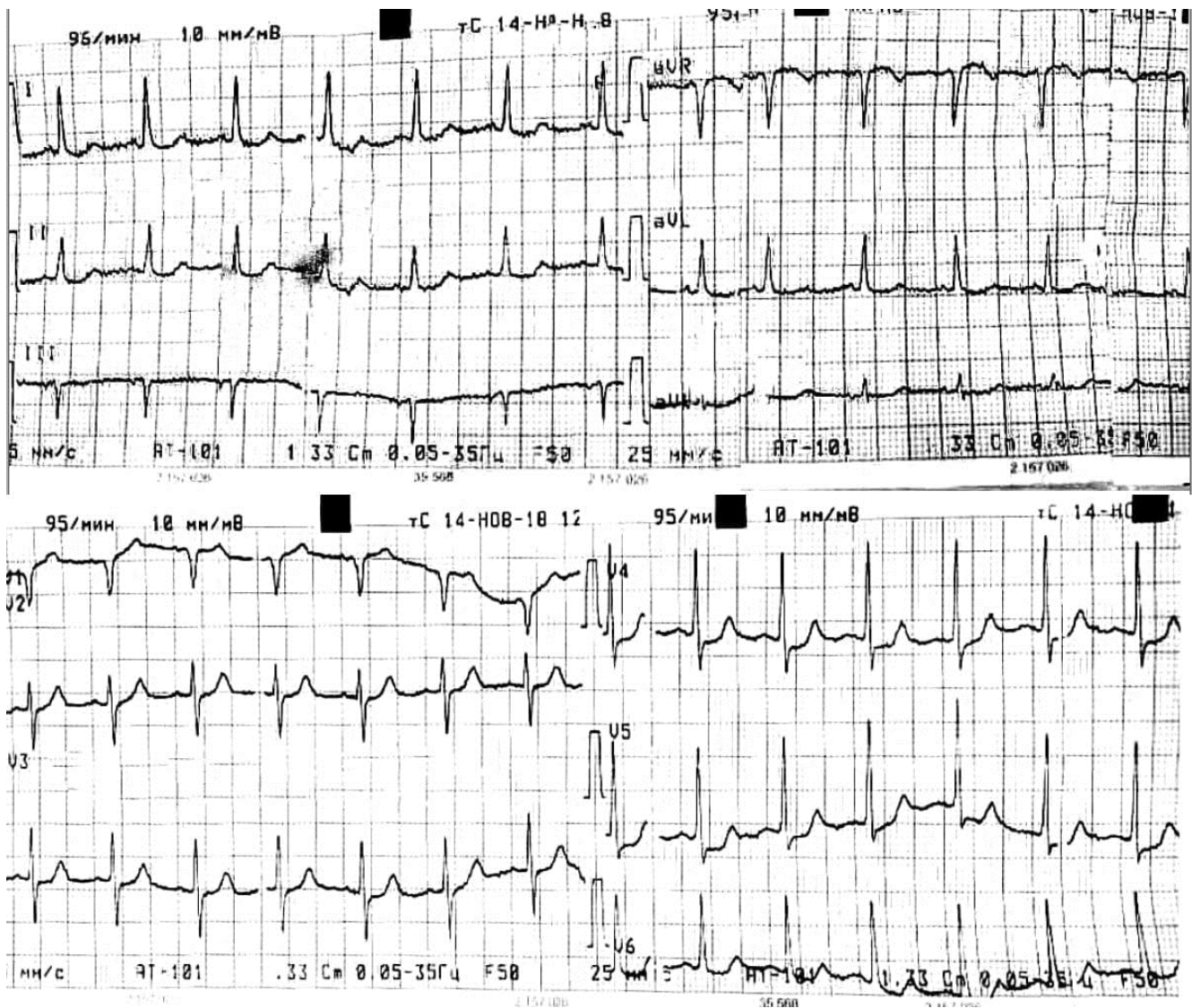


Figure 1. Electrocardiogram on admission, showing sinus rhythm with ST-segment depression <1 mm in leads I, aVL, and V₄-V₆.

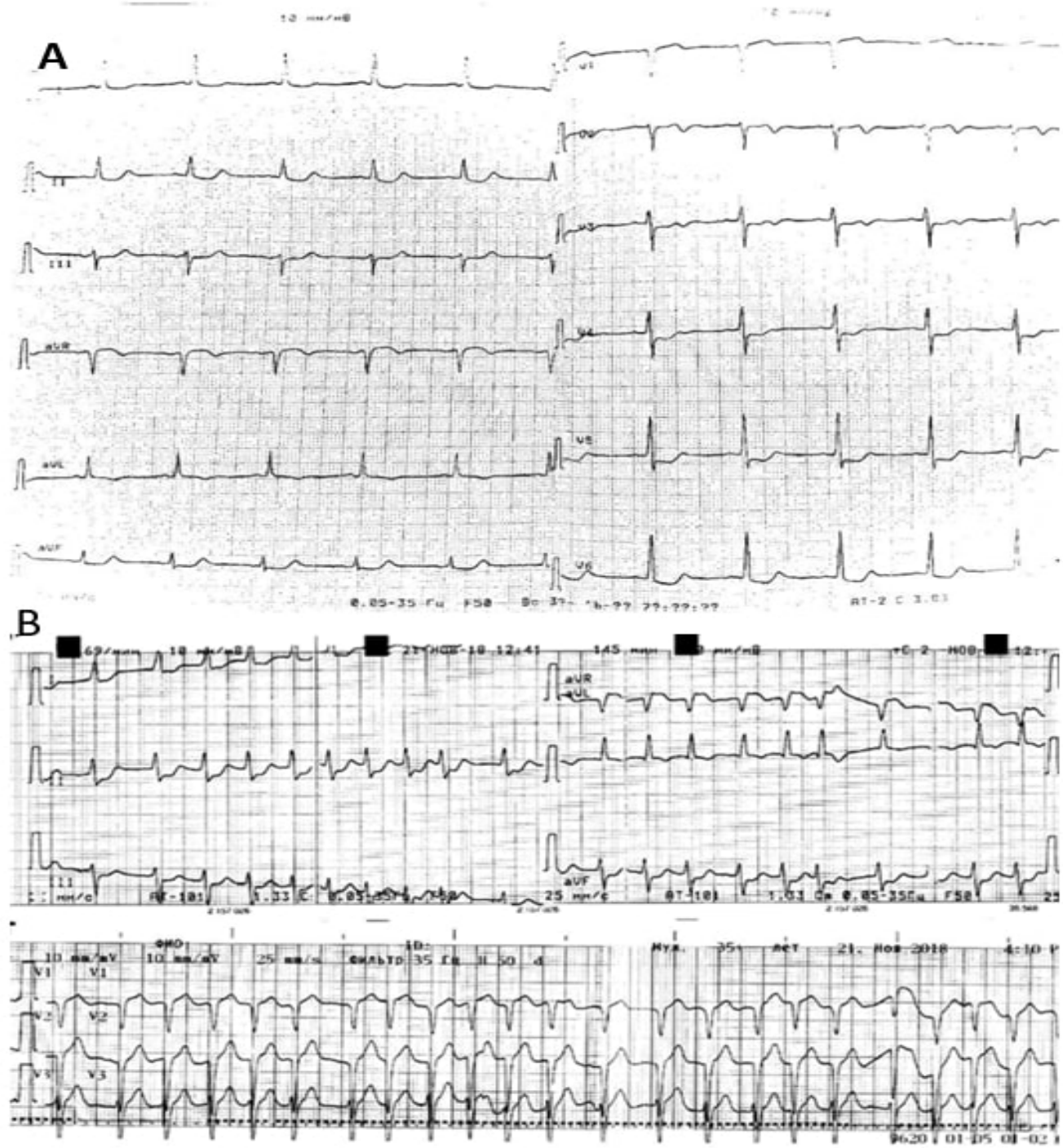


Figure 2. ECG on hospital day 4 (A), and day 7 (B)

A) Shows sinus rhythm with ST- segment depression in leads II, aVF, and V_3 - V_5 .

B) Shows paroxysmal atrial fibrillation with rapid ventricular response (150 bpm) and ST-segment depression >2 mm in leads II and aVF.

On hospital day 2, hemoglobin decreased from 10 g/dL to 8.6 g/dL, and 1 unit of packed red blood cells was transfused. The patient's condition was stable: there were no signs of rebleeding on control endoscopy (Forrest III) and the epigastric pain was decreased. However, the intensity of his retrosternal pain increased. On day 4, ST-

segment depression deepened to greater than 2 mm in II, aVF, V_3 - V_5 leads (Figure 2A). Further, a decrease in the left ventricular ejection fraction to 30% with concomitant left ventricular dyskinesia was noted on echocardiography. The serum troponin I value rose to 1.75 ng/mL. The clinical diagnosis of type 2 non-ST-elevation MI was established,

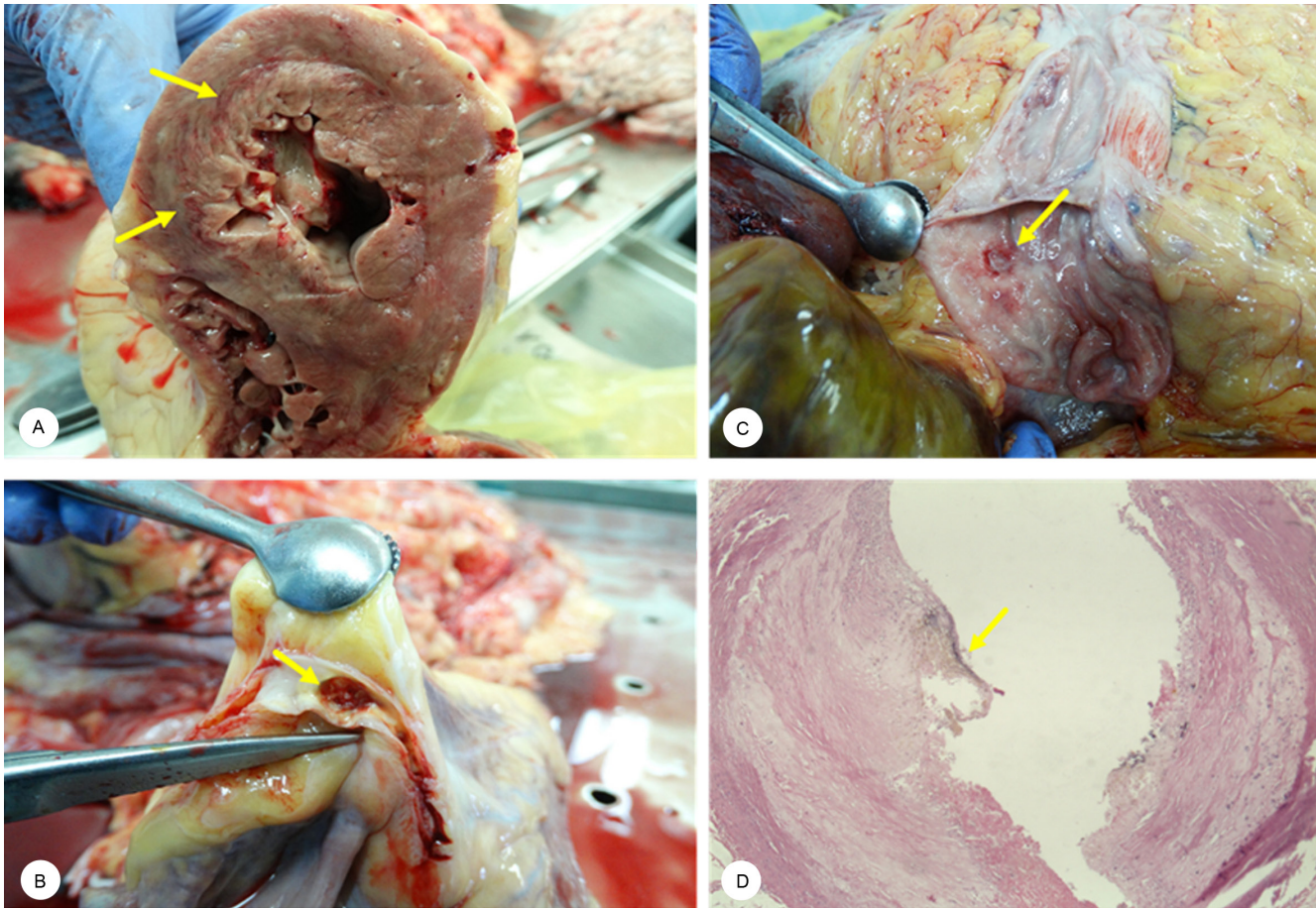


Figure 3. Postmortem pathologic images

- A) Acute transmural myocardial infarction: The transverse heart specimen shows a large myocardial infarction in the anterolateral wall and interventricular septum with signs of bleeding from the damaged vessels (arrows). Specimen is oriented with the posterior wall at the bottom.
- B) Peptic ulcer disease: An ulcer, located on the posterior-upper duodenal wall, is covered with fibrin and granulation tissue (arrow).
- C) Atherosclerotic coronary plaque rupture: Plaque rupture with superimposed coronary thrombosis (arrow) is illustrated.
- D) Atherosclerotic coronary plaque rupture: Intraplaque hemorrhage is seen due to the rupture of the overlying fibrous cap (arrow).

and conservative therapy with a beta-blocker (metoprolol [12.5 mg BID]), an angiotensin-converting enzyme inhibitor (enalapril [2.5 mg BID]), and a statin (atorvastatin [20 mg QD]) was initiated. Antithrombotic therapy was withheld due to concerns regarding recurrent bleeding and assumptions about the low risk of thrombosis. On day 7, the patient's otherwise stable clinical course was complicated by paroxysmal atrial fibrillation (Figure 2B), which was unresponsive to cardioversion attempts and resulted in a cardiogenic shock (BP = 80/40 mmHg and urine output <300 mL/d) that proved refractory to inotropic support, in part, due to the previous beta-blocker administration. The serum troponin I level further rose to 10.55 ng/mL. The patient died, and an autopsy was performed. Pathology revealed acute (3 days old) transmural MI of the left ventricular anterolateral wall and interventricular septum (Figure 3A), as well as a chronic duodenal ulcer (Figure 3B). Autopsy additionally demonstrated the presence of coronary atherosclerosis, an unstable plaques with intraplaque hemorrhage, and an

adjacent non-occlusive thrombus in the proximal third of the right coronary artery, consistent with T1MI (Figure 3C, 3D).

Discussion

CAG plays an essential role in the diagnosis of atherothrombosis, which can be detected in between 26% and 90% of patients with MI.¹ In patients with T2MI, the use of CAG along with clinical judgment has been suggested to improve the accuracy of MI type classification.² In our patient, MI was triggered by acute gastrointestinal bleeding and post-hemorrhagic anemia, which is a suitable clinical criterion for T2MI, according to the current definition and published literature.²⁻⁴ However, autopsy results demonstrated the classical signs of T1MI in the form of coronary plaque disruption, thus emphasizing the possible discrepancies between the clinical and morphological signs of the MI type.³ The presence of a non-occlusive thrombus

in the right coronary artery seemingly contradicted the anteroseptal localization of the MI, which could be explained by systemic inflammation contributing to the concurrent (pancoronary) vulnerability of multiple atherosclerotic plaques or the additive action of atherothrombosis and the decreased oxygen supply on the development of acute ischemia.⁵ It should also be noted that the finding of transmural MI on autopsy is not unexpected, given that according to magnetic resonance imaging and autopsy studies, ECG signs (ST elevation or Q wave) cannot reliably exclude this possibility.^{6,7} The prevalence of moderate and severe anemia was reported in approximately 12% of T2MI cases,⁸ forming a distinct clinical syndrome. MI is frequently underdiagnosed in this setting⁹ because severe bleeding frequently overshadows ischemic symptoms and signs. In the Israeli acute coronary syndrome (ACS) prospective registry (n=5600), CAG was performed less frequently in patients with anemia than in those without this condition (77% vs. 91%; $P < 0.001$), although most anemic patients (95%) who underwent CAG were eventually diagnosed with obstructive coronary artery disease and 78% of them were triaged to revascularization.⁹ CAG has been demonstrated to improve short-term prognosis with no significant excess in major bleeding.¹⁰ Timing to perform CAG depends on the initial risk stratification.¹¹ In our patient, the thrombotic risk was high (rise or fall in cardiac troponin compatible with MI, and GRACE score >140, dynamic ST-T changes); consequently, an early invasive strategy (<24 h) was indicated. However, given the perceived high risk of bleeding (CRUSADE bleeding score=42), a decision to postpone CAG was made. The need for blood transfusion after bleeding cessation was also questionable. According to the current guidelines, transfusion should be considered in patients with ACS and ongoing ischemia that have hemoglobin values in the range of 8 to 10 g/dL. This range represents a “gray area” in which the decision to transfuse needs to be tailored to the patient’s specific comorbidities.¹¹ Anticoagulant and antiplatelet therapy should not be withheld completely in patients with non-ST-elevation MI if at all possible.¹¹

This case illustrates the possible consequences of undertreatment with antithrombotic drugs. Indeed, at least P2Y₁₂ inhibitors, which have less ulcerogenic properties,¹² should have been administered. Timely CAG could have also changed the management and clinical course of this patient.

Conclusion

The presented case highlights the discrepancy between the presence of the clinical triggers of T2MI and the morphological signs of atherothrombosis, underscoring the need to perform CAG for this category of patients to avoid underdiagnosis of TIMI and to change management according to angiography findings. Individualized approaches to blood transfusions,

wider use of antithrombotic drugs, and CAG in the absence of ongoing bleeding may help to improve outcomes in such patients.

Acknowledgments

The publication was prepared with the support of the “RUDN University, Program 5-100”.

References

1. Agewall S, Beltrame JF, Reynolds HR, Niessner A, Rosano G, Caforio ALP, Caterina R De, Zimarino M, Roffi M, Kjeldsen K, Atar D, Kaski JC, Sechtem U, Tornvall P. ESC working group position paper on myocardial infarction with non-obstructive coronary arteries. *Eur Heart J* 2017;38:143-153.
2. Vargas KG, Haller PM, Jäger B, Tscharré M, Binder RK, Mueller C, Lindahl B, Huber K. Variations on classification of main types of myocardial infarction: a systematic review and outcome meta-analysis. *Clin Res Cardiol* 2019;108:749-762.
3. Thygesen K, Alpert JS, Jaffe AS, Chaitman BR, Bax JJ, Morrow DA, White HD, Mickley H, Crea F, Van de Werf F, Bucciarelli-Ducci C, Katus HA, Pinto FJ, Antman EM, Hamm CW, De Caterina R, Januzzi JL, Jr, Apple FS, Alonso Garcia MA, Underwood SR, Canty JM, Jr, Lyon AR, Devereaux PJ, Zamorano JL, Lindahl B, Weintraub WS, Newby LK, Virmani R, Vranckx P, Cutlip D, Gibbons RJ, Smith SC, Atar D, Luepker RV, Robertson RM, Bonow RO, Steg PG, O’Gara PT, Fox KAA. Fourth universal definition of myocardial infarction (2018). *Kardiol Pol* 2018;76:1383-1415.
4. Gupta S, Vaidya SR, Arora S, Bahekar A, Devarapally SR. Type 2 versus type 1 myocardial infarction: a comparison of clinical characteristics and outcomes with a meta-analysis of observational studies. *Cardiovasc Diagn Ther* 2017;7:348-358.
5. Morariu M, Hodas R, Benedek T, Benedek I, Opincariu D, Mester A, Chitu M, Kovacs I, Rezus C, Pasaroiu D, Mitra N, Szilágyi SM, Georgescu D, Rezus E. Impact of inflammation-mediated response on pan-coronary plaque vulnerability, myocardial viability and ventricular remodeling in the postinfarction period - the VIABILITY study: Protocol for a non-randomized prospective clinical study. *Medicine (Baltimore)* 2019;98:e15194.
6. Raunio H, Rissanen V, Romppanen T, Jokinen Y, Rehnberg S, Heilin M, Pyörälä K. Changes in the QRS complex and ST segment in transmural and subendocardial myocardial infarctions. A clinicopathologic study. *Am Heart J* 1979;98:176-184.
7. Sievers B, John B, Brandts B, Franken U, Bracht M Van, Trappe HJ. How reliable is electrocardiography in differentiating transmural from non-transmural myocardial infarction? A study with contrast magnetic resonance imaging as gold standard. *Int J Cardiol* 2004;97:417-423.
8. Bellotto F, Fagioli S, Pavei A, Gregory SA, Cati A, Silverj E, Plebani M, Zaninotto M, Mancuso T, Iliceto S. Anemia and ischemia: Myocardial injury in patients with gastrointestinal bleeding. *Am J Med* 2005;118:548-551.
9. Sudarsky D, Sudarsky M, Matezky S, Goldenberg I, Farcas A, Nikolsky E. Impact of early invasive approach on outcomes of patients with acute coronary syndrome and baseline anemia: analysis from the ACSIS registry. *J Interv Cardiol* 2015;28:315-325.
10. Roffi M, Patrono C, Collet J-P, Mueller C, Valgimigli M, Andreotti F, Bax JJ, Borger MA, Brotons C, Chew DP, Gencer B, Hasenfuss G, Kjeldsen K, Lancellotti P, Landmesser U, Mehilli J, Mukherjee D, Storey RF, Windecker S; ESC Scientific Document Group. 2015 ESC Guidelines for the management of acute coronary syndromes in patients presenting without persistent ST-segment elevation:



Task Force for the Management of Acute Coronary Syndromes in Patients Presenting without Persistent ST-Segment Elevation of the European Society of Cardiology (ESC). *Eur Heart J* 2016;37:267-315.

11. Carson JL, Guyatt G, Heddle NM, Grossman BJ, Cohn CS, Fung MK, Gernsheimer T, Holcomb JB, Kaplan LJ, Katz LM, Peterson N, Ramsey G, Rao SV, Roback JD, Shander A, Tobian AA. Clinical Practice Guidelines From the AABB: Red Blood Cell Transfusion Thresholds and Storage. *JAMA* 2016;316:2025-2035.
12. Mcquaid KR, Laine L. Systematic review and meta-analysis of adverse events of low-dose Aspirin and Clopidogrel in randomized controlled trials. *Am J Med* 2006;119:624-638.