



Hyperimmunoglobulin E Syndrome with Tortuous and Massively Dilated Thoracic and Abdominal Aorta: An Extremely Rare Cardiac Presentation of an Immunodeficiency Disease

Alireza Golbabaee, MD¹, Behdad Gharib, MD^{2*}

¹Department of Perinatology and Fetal Cardiology, Shariati Hospital, Tehran University of Medical Sciences, Tehran, Iran.

²Department of Pediatrics, Children's Medical Center, Tehran University of Medical Sciences, Tehran, Iran.

A 21-year-old girl, a known case of hyperimmunoglobulin E syndrome (HIES), was referred for cardiologic evaluation. She was born to consanguineous parents. Her past medical history was significant for several episodes of pneumonia, otitis media, and cutaneous infections. She presented with generalized dermatitis, which was infected in some regions. Staphylococcus aureus was isolated from the infected areas. Cutaneous human papillomavirus (HPV) infections were obvious as epidermodysplasia verruciformis on sun-exposed areas and giant warts on the anogenital regions. The laboratory studies revealed anemia, lymphopenia, and eosinophilia. The patient did not present any cardiac signs or symptoms, and her blood pressure was normal. Preemptive cardiac evaluations using echocardiography and magnetic resonance imaging revealed giant ascending (Figure A and Figure B; blue arrows), descending (Figure 1 and Figure 2; yellow arrows), and abdominal (Figure 3; yellow arrow) aortic tortuosity and dilation. The parasternal long-axis echocardiographic view (Figure 4) showed highly dilated aortic Valsalva sinus (blue line), sinotubular junction (red line), and aortic annulus (yellow line). As the whole length of the aorta was involved and surgical repair could not be performed, we started enalapril and recommended the patient to follow the conservative management.

HIES is a very rare type of primary immune deficiency.¹ The disease is characterized by high serum immunoglobulin E (IgE) levels; dermatologic, dental, and skeletal abnormalities; recurrent staphylococcal abscesses; and pneumonia. A serum level of IgE is routinely more than 2000 IU/mL.² Vascular anomalies and their sequelae contribute to significant morbidity and mortality in patients with HIES. It is advisable that all patients with HIES be evaluated thoroughly for vascular involvement.

J Teh Univ Heart Ctr 2020;15(3):147-148

This paper should be cited as: Golbabaee A, Gharib B. Hyperimmunoglobulin E Syndrome with Tortuous and Massively Dilated Thoracic and Abdominal Aorta: An Extremely Rare Cardiac Presentation of an Immunodeficiency Disease. *J Teh Univ Heart Ctr 2020;15(3):147-148.*

Keywords: Immunologic deficiency syndromes; Aorta, thoracic; Aorta, abdominal

*Corresponding Author: **Behdad Gharib**, Assistant Professor of Pediatrics, Children's Medical Center Hospital, No 62, Dr Gharib Street, Tehran, Iran. 1419733151. Tel: +98 21 61472506. Fax: +98 21 66930024. E-mail: bgharib@sina.tums.ac.ir.



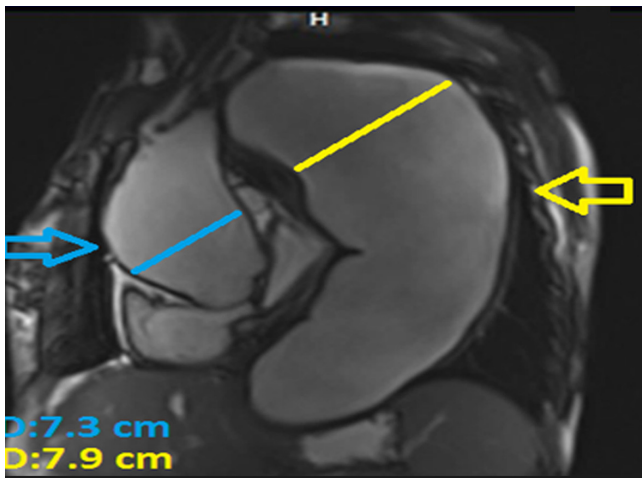


Figure 1. Sagittal view of cardiac magnetic resonance imaging, showing a massively dilated ascending aorta (blue arrow, 7.3 cm in diameter) and a large-sized descending aorta aneurysm (yellow arrow, 7.9 cm in diameter)

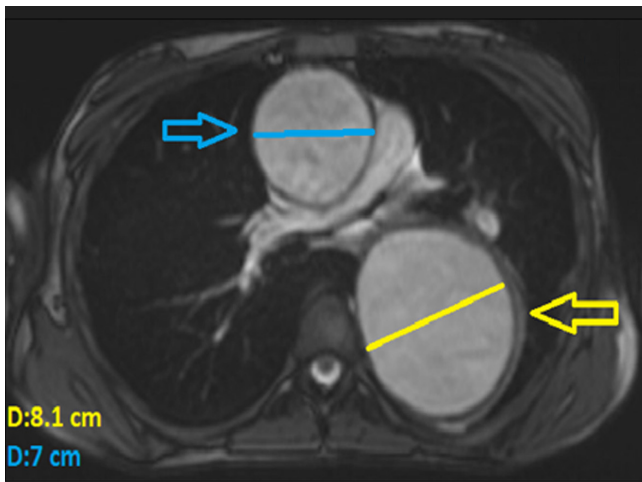


Figure 2. Axial view of cardiac magnetic resonance imaging, showing a massively dilated ascending aorta (blue arrow, 7 cm in diameter) and a large-sized descending aorta aneurysm (yellow arrow, 8.1 cm in diameter)

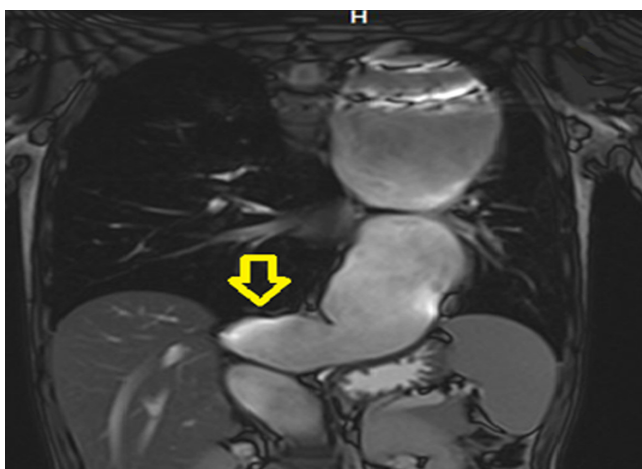

Figure 3. Coronal view of the thoracic and abdominal magnetic resonance

imaging, showing huge and tortuous abdominal aorta (yellow arrow)

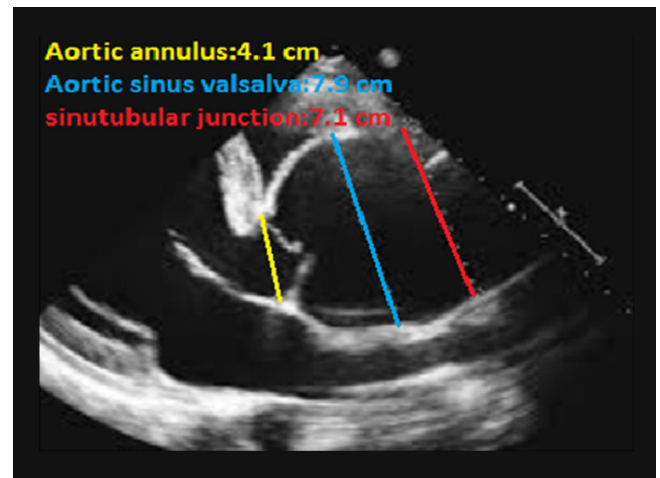


Figure 4. Parasternal long-axis echocardiographic view, showing a highly dilated aortic Valsalva sinus (blue line), sinotubular junction (red line), and aortic annulus (yellow line)

References

1. Sharafian S, Movahedi M, Kalantari A, Parvaneh N, Gharagozlou M. A rare case of hyper IGE syndrome with vocal cords involvement. *Iran J Allergy Asthma Immunol* 2019;18:225-229.
2. Sullivan, KE Buckley, RH. Combined immunodeficiency. In: Kliegman MR, St. Geme J, eds. *Nelson Textbook of Pediatrics*, 21st ed. Philadelphia: Elsevier Health Sciences; 2020. p. 1117-1118.