



# Cryoballoon Atrial Fibrillation Ablation in a Patient with an Atrial Septal Defect Closure Device

Meisam Mokhtari, MD<sup>1,2</sup>, Zahra Khajali, MD<sup>1</sup>, Mona Heidarali, MD<sup>1</sup>, Majid Haghjoo, MD<sup>1,2\*</sup>

<sup>1</sup>Rajaie Cardiovascular Medical and Research Center, Iran University of Medical Sciences, Tehran, Iran.

<sup>2</sup>Cardiac Electrophysiology Research Center, Rajaie Cardiovascular Medical and Research Center, Iran University of Medical Sciences, Tehran, Iran.

Received 17 July 2020; Accepted 02 December 2020

## Abstract

Atrial fibrillation (AF) is the most commonly treated arrhythmia in clinical practice and is often found in association with an atrial septal defect (ASD). However, ASD closure rarely confers complete arrhythmia control. A 23-year-old man presented to our center with frequent episodes of palpitations. AF was documented in 12-lead electrocardiography, and echocardiography showed a secundum-type ASD, 14 mm in size, with a significant left-to-right shunt. ASD closure was performed successfully with an ASD occluder device with no residual shunting. During follow-up, the patient experienced several episodes of AF. Thirteen months after the ASD closure, cryoballoon pulmonary vein isolation was done successfully with no complications. During a 12-month follow-up, he had no symptoms or AF recurrences, and echocardiography showed no residual shunting. This study showed that cryoballoon pulmonary vein isolation could be performed successfully without residual shunts in patients with ASD closure devices.

*J Teh Univ Heart Ctr 2021;16(1):42-44*

**This paper should be cited as:** Mokhtari M, Khajali Z, Heidarali M, Haghjoo M. Cryoballoon Atrial Fibrillation Ablation in a Patient with an Atrial Septal Defect Closure Device. *J Teh Univ Heart Ctr 2021;16(1):42-44.*

**Keywords:** Heart septal defects, atrial; Atrial fibrillation; Catheter ablation

## Introduction

Atrial fibrillation (AF) is the most frequently treated arrhythmia in clinical practice and is often found in association with an atrial septal defect (ASD).<sup>1</sup> Nonetheless, ASD closure rarely results in complete arrhythmia control.<sup>2</sup> The electrical isolation of the pulmonary veins via radiofrequency (RF) catheter ablation or cryoballoon (CB) ablation is an effective and widely available treatment for drug-refractory symptomatic AF.<sup>3</sup> Anticipating technical difficulties for transseptal access to the left atrium and

potential complications may discourage operators from considering the catheter ablation of AF in this particular patient population.

Prior reports have described the technical feasibility of performing percutaneous RF catheter ablation after either surgical or percutaneous ASD closure.<sup>4,5</sup> In the present study, we describe our experience with transseptal puncture (TSP) and CB-pulmonary vein isolation (PVI) in a patient with prior implantation of an ASD closure device.

\*Corresponding Author: Majid Haghjoo, Professor of Cardiovascular Diseases, Cardiac Electrophysiology Research Center, Rajaie Cardiovascular Medical and Research Center, Vali-e-Asr Street, Ayatollah Hashemi-Rafsanjani Blvd, Tehran, Iran. 1995614331. Tel: +98 21 23923830. Fax: +98 21 22042026. E-mail:majid.haghjoo@gmail.com.





## Case Report

A 23-year-old man presented to our center with frequent episodes of palpitations. AF was documented in 12-lead electrocardiography, and echocardiography showed a secundum-type ASD, 14 mm in size, with significant left-to-right shunting. Electrophysiologic study demonstrated no non-pulmonary vein triggers or inducible supraventricular tachycardias. Therefore, the patient was referred for ASD closure, which was performed successfully with a Figulla ASD Occluder (FSO; Occlutech GmbH, Jena, Germany) with no residual shunting. During follow-up, he experienced several episodes of palpitations. AF was confirmed in 24-hour ambulatory electrocardiography. Accordingly, amiodarone was prescribed for rhythm control. However, his palpitations proved refractory to amiodarone, and he was admitted with persistent AF. Cardioversion was performed successfully by direct-current energy (150 J) into normal sinus rhythm. Thirteen months after the ASD closure, the patient was scheduled for CB-PVI due to drug-refractory and symptomatic AF.

The patient provided written informed consent for electrophysiologic study and PVI. The ablation procedure was performed under sedation with a continuous propofol infusion. Two venous punctures were made in the left femoral vein, and 2 introducer sheaths were placed: a 6 F quadripolar catheter was introduced into the right ventricle and a 7 F multipolar electrode catheter (Biosense Webster, Inc, Diamond Bar, CA) in the coronary sinus. Another venous puncture was made in the right femoral vein, and a long steerable sheath was placed for TSP. At the time, we had no access to intracardiac echocardiography; consequently, TSP was done under fluoroscopic guidance. The initial TSP was performed posteroinferior to the ASD closure device, but the left atrium could not be accessed. However, transseptal access was obtained successfully through the anteroinferior part of the native septum, which was not covered by the ASD closure device. Then, an 8.5 F long sheath was increased to a 12 F FlexCath steerable sheath (Medtronic, Inc, Minneapolis, Minnesota) (Figure 1).

CB ablation was performed in deliveries of 180 seconds per pulmonary vein, and entrance and/or exit blockage was assessed by using pacing and a circular mapping catheter (Figure 2). During the cryoablation of the antrum of the right-sided pulmonary veins, the phrenic nerve was monitored by continuous phrenic nerve stimulation via a stimulation catheter placed within the superior vena cava. During a 12-month follow-up, the patient had no symptoms or AF recurrences, and echocardiography showed no residual shunts.

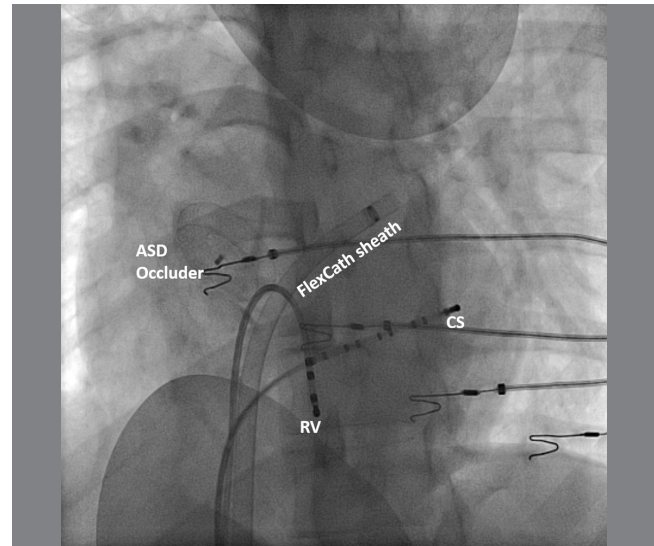


Figure 1. The left anterior oblique view angiogram illustrates transseptal access through the anteroinferior part of the native septum, which is not covered by the ASD closure device.

CS, Coronary sinus catheter; RV, Right ventricular catheter; ASD occluder, Atrial septal defect occluder

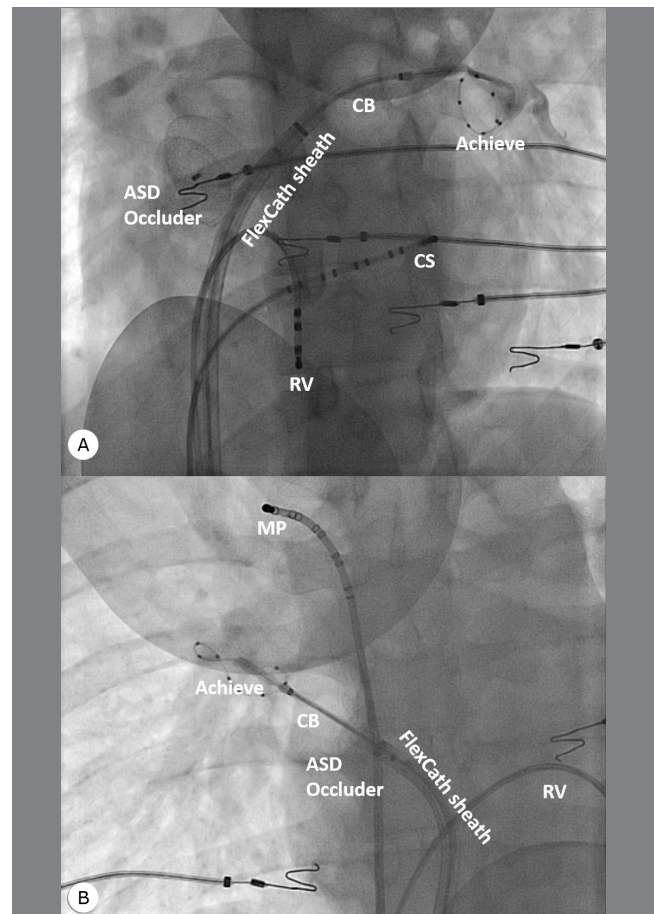


Figure 2. The image depicts pulmonary vein isolation via CB ablation. The CB is positioned and inflated at the antrum of the left upper pulmonary vein (Panel A, left anterior oblique view) and the right upper pulmonary vein

(Panel B, right anterior oblique view).

CS, Coronary sinus catheter; RV, Right ventricular catheter; MP, Multipolar catheter; CB, Cryoballoon; ASD occluder, Atrial septal defect occluder

## Discussion

AF is often found in association with an ASD,<sup>1</sup> but ASD closure rarely results in complete arrhythmia control.<sup>2</sup> A meta-analysis showed that while both percutaneous and surgical ASD closure procedures reduced the overall prevalence of atrial arrhythmias, the prevalence remained high during follow-up. The closure of an ASD halts volume overload and could lead to some reverse remodeling in the atrium, both structurally and electrically; nevertheless, it rarely confers the complete resolution of atrial arrhythmias once they have become established.

TSP after percutaneous ASD closure is technically feasible, but it can pose a significant challenge because of the issue of left atrial access. Prior studies have emphasized the need for intracardiac echocardiography monitoring as a means to assess the optimal site for TSP, to monitor the advancement of the dilator and sheath into the left atrium, and to detect such potential complications as device dislodgement promptly.

Two publications have demonstrated the feasibility of RF-PVI in patients with ASD closure devices. Xuping Li et al<sup>4</sup> reported the safety and feasibility of TSP and PVI in a series of 9 patients with AF at a median of 16 months after the index procedure with ASD occluder devices. They also showed that TSP posteroinferior to the ASD occluder device could be performed successfully if the maximum device diameter was 26 mm. For larger devices, Xuping Li and colleagues concluded that direct puncturing through the ASD occluder was feasible and safe if performed more than 6 months after the device implantation. Santangeli et al<sup>5</sup> demonstrated the feasibility, safety, and efficacy of TSP and AF ablation in 35 patients. Their results showed that TSP could be obtained in portions of the native septum in the majority of cases.

In the present study, we reported the feasibility, safety, and efficacy of TSP and CB-PVI in a young patient with an ASD closure device. The novelty of our report is that CB-PVI requires larger sheaths (12 F vs 8.5 F in RF-PVI guided by 3D mapping) for left atrial access and that the limited area of the native septum available for TSP may hinder the successful isolation of right-sided pulmonary veins. In addition, there is more concern over postprocedural residual shunting due to the larger CB sheath. During a 12-month follow-up, our patient had no symptoms, 72-hour ambulatory electrocardiography showed no AF recurrences, and contrast echocardiography demonstrated no residual interatrial shunts.

## Conclusion

Cryoballoon-pulmonary vein isolation can be performed successfully without residual shunts in patients with atrial septal defect closure devices.

## References

1. Craig RJ, Selzer A. Natural history and prognosis of atrial septal defect. *Circulation* 1968;37:805-815.
2. Murphy JG, Gersh BJ, McGoon MD, Mair DD, Porter CJ, Ilstrup DM, McGoon DC, Puga FJ, Kirklin JW, Danielson GK. Long-term outcome after surgical repair of isolated atrial septal defect. Follow-up at 27 to 32 years. *N Engl J Med* 1990;323:1645-1650.
3. Calkins H, Hindricks G, Cappato R, Kim YH, Saad EB, Aguinaga L, Akar JG, Badhwar V, Brugada J, Camm J, Chen PS, Chen SA, Chung MK, Nielsen JC, Curtis AB, Davies DW, Day JD, d'Avila A, de Groot NMSN, Di Biase L, Duytschaever M, Edgerton JR, Ellenbogen KA, Ellinor PT, Ernst S, Fenelon G, Gerstenfeld EP, Haines DE, Haissaguerre M, Helm RH, Hylek E, Jackman WM, Jalife J, Kalman JM, Kautzner J, Kottkamp H, Kuck KH, Kumagai K, Lee R, Lewalter T, Lindsay BD, Macle L, Mansour M, Marchlinski FE, Michaud GF, Nakagawa H, Natale A, Nattel S, Okumura K, Packer D, Pokushalov E, Reynolds MR, Sanders P, Scanavacca M, Schilling R, Tondo C, Tsao HM, Verma A, Wilber DJ, Yamane T. 2017 HRS/EHRA/ECAS/APHRS/SOLAECE expert consensus statement on catheter and surgical ablation of atrial fibrillation: Executive summary. *Heart Rhythm* 2017;14:e445-e494.
4. Santangeli P, Di Biase L, Burkhardt JD, Horton R, Sanchez J, Bailey S, Zagrodzky JD, Lakkireddy D, Bai R, Mohanty P, Beheiry S, Hongo R, Natale A. Transseptal access and atrial fibrillation ablation guided by intracardiac echocardiography in patients with atrial septal closure devices. *Heart Rhythm* 2011;8:1669-1675.
5. Li X, Wissner E, Kamioka M, Makimoto H, Rausch P, Metzner A, Mathew S, Rillig A, Richard Tilz R, Fürnkranz A, Chen Q, Zhang Q, Liu Q, Zhou S, Kuck KH, Ouyang F. Safety and feasibility of transseptal puncture for atrial fibrillation ablation in patients with atrial septal defect closure devices. *Heart Rhythm* 2014;11:330-335.