

Prenatal Diagnosis of a Rare Case of Double-Outlet Right Ventricle with Tricuspid Atresia

Dear Editor,

Double-outlet right ventricle (DORV) represents a rare group of cardiac anomalies characterized by both great arteries arising primarily from the RV. This disease is a conotruncal anomaly as a complex heart disease and comprises less than 1% of all congenital heart anomalies.^{1, 2} The first diagnostic criterion for DORV is the rise of both the aorta and the pulmonary artery from the morphologic RV. Other cardiac malformations are always present with the frequent coexistence of multiple abnormalities. These may include 1 or more ventricular septal defects, left ventricular outflow obstruction, and atrioventricular valve abnormalities.^{3, 4} DORV may occur with any atrial situs and many other variations; nonetheless, situs solitus and atrioventricular concordance are the most common findings.⁴

We herein present a very rare case of DORV, in tandem with tricuspid atresia, transposition of the great arteries, pulmonary stenosis, and ventricular septal defect.

A 35-year-old pregnant woman (gravida 2, para 1, and 1 living child with a history of congenital heart disease) was referred for fetal cardiac assessment at 18th weeks of gestational age.

A transabdominal 2D echocardiogram in the axial view showed viscera atrial situs solitus, levocardia, and levoposition. The 4-chamber view demonstrated prominent echo density in tricuspid valve location, expressive of tricuspid valve atresia. Also in this view, a small and hypoplastic RV was detected (Figure 1). The short-axis view of the great arteries determined dextro-malposition of the aorta (right and anterior aorta or D-malposed aorta) (Figure 2). The sagittal outlet view illustrated a small pulmonary diameter, representing pulmonary stenosis (Figure 3). The subcostal or septal view detected a large subpulmonic ventricular septal defect (Figure 4).

Karyotyping was performed on an amniotic fluid sample, but no chromosomal abnormality was detected. We informed the woman that the prognosis of this disease was poor, and she decided to terminate her pregnancy. Pregnancy termination was done at 19 weeks of gestational age.

VanPraagh et al⁵ proposed a segmental classification according to the involvement of the 3 major segments of

the heart: Group I, DORV with conotruncal anomalies only, involving 1 segment of the heart (great arteries); Group II, DORV associated with malformations of the atrioventricular canal and the ventricles, involving 2 segments (great arteries and ventricles); and Group III, DORV in the setting of heterotaxy syndromes and anomalies of the situs, involving the 3 segments (great arteries, ventricles, and atria). Our case was classified as Group II DORV. Research has shown a rise in the incidence of chromosomal abnormalities, especially chromosome 22q12 deletion, trisomy18, and trisomy 13.² In our case, the chromosomal karyotype was not abnormal.

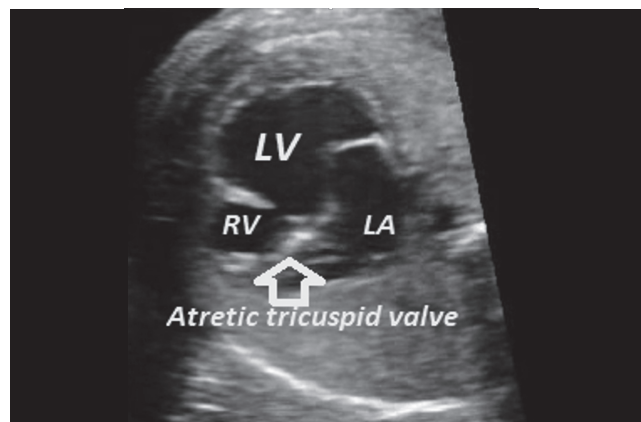


Figure 1. The fetal cardiac ultrasound in the axial view of the heart shows an atretic tricuspid valve, a small and hypoplastic RV, and a single-ventricle LV morphology.

RV, Right ventricle; LV, Left ventricle; RA, Right atrium

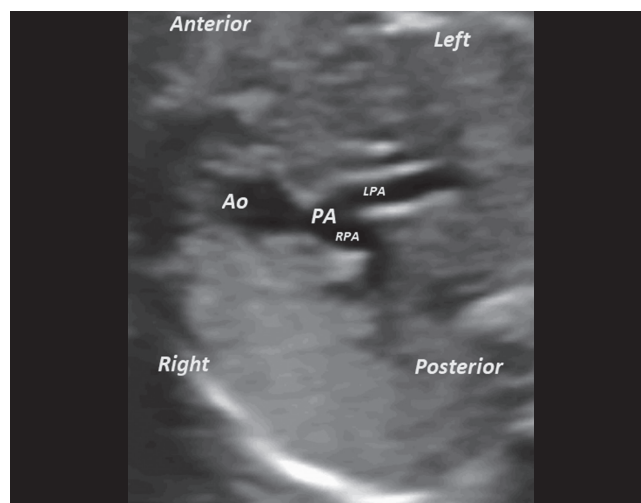


Figure 2. The fetal cardiac ultrasound in the short-axis view of the great arteries shows dextro (D) malposition or right and anterior positioning of the Ao, the PA, the RPA, and the LPA.

Ao, Aorta; PA, Small pulmonary artery; RPA, Right pulmonary artery; LPA, Left pulmonary artery

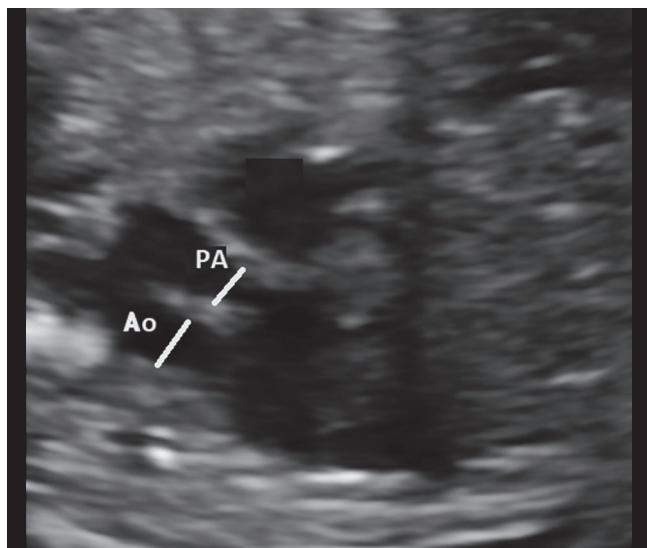


Figure 3. The fetal cardiac ultrasound in the sagittal view of the great vessels shows the anterior Ao, the PA, and the smaller pulmonary annulus, indicating pulmonary stenosis.

Ao, Aorta; PA, Posterior pulmonary artery

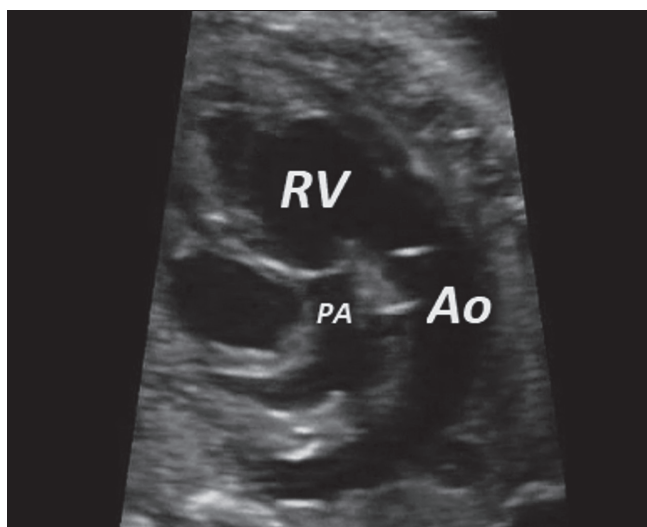


Figure 4. The fetal cardiac ultrasound in the sagittal view of the great arteries shows a small PA, representing pulmonary stenosis, and a dominant connection of the Ao and the pulmonary artery to the RV, demonstrating DORV.

PA, Small pulmonary artery; Ao, Aorta; RV, Right ventricle; DORV, Double-outlet right ventricle

The use of conventional echocardiography is adequate for the diagnosis of DORV. The essential part of the diagnosis, however, depends on the exact analysis of the origin of the 2 great arteries. Experienced fetal cardiologists can show 2 parallel great arteries, although sometimes it may be difficult to distinguish the exact origin. The challenge in particular may lie in distinguishing DORV from other conotruncal abnormalities such as tetralogy of Fallot, transposition of the great arteries, and ventricular septal defect.²⁻⁴

The prognosis in patients with DORV depends on the severity of associated lesions. Clinical presentation is influenced by the presence or absence of pulmonary stenosis, the position of the ventricular septal defect in relation to the great arteries, and other associated major defects⁴

Brown et al⁶ concluded that risk factors for DORV included aortic arch obstruction, multiple ventricular septal defects, a large ventricular septal defect, and ventricular outflow obstruction or hypoplasia. The rate of pregnancy termination due to DORV varies between 15.8% and 43.4%. These data suggest that the decision to terminate a pregnancy must be individualized for every patient. Further, more women carrying fetuses with DORV and extracardiac defects might choose to terminate if the diagnosis is made earlier.

Bhatla et al⁷ advocated prototyping in correctly selected cases of multifaceted congenital heart disease by positing that a meticulous anatomical understanding could help surgeons choose potential surgical and cardiac catheterization interventions. They utilized a 3D-printed model to better delineate the anatomy of their patient with DORV.

In conclusion, we presented a rare case of DORV and suggested that this kind of congenital heart disease could be diagnosed by experienced fetal echocardiographers with conventional 2D echocardiography. As the degree and nature of the hemodynamic disturbance will affect the prognosis of any conotruncal anomaly, an accurate prenatal description is important for the counseling of parents, particularly if termination is considered. The detection of serious fetal cardiac abnormalities allows the option of pregnancy termination if they are diagnosed early enough in gestation. The parents in our case opted for termination having been made aware of the poor prognosis. Ideally, fetuses at risk for structural cardiac defects should be scanned between 17 and 24 weeks of gestation. During this period of pregnancy, the heart is large enough for adequate visualization, and there is enough amniotic fluid surrounding the fetus to provide a good ultrasonic window.

References

1. Goo HW. Coronary artery anomalies on preoperative cardiac CT in children with tetralogy of Fallot or Fallot type of double outlet right ventricle: comparison with surgical findings. *Int J Cardiovasc Imaging* 2018;34:1997-2009.
2. Wu H, Cai A, Zhang Y, Sun W, Wang Y. Prenatal diagnosis of a fetal double-outlet right ventricle with tricuspid valve atresia, a straddling mitral valve, and a hypoplastic left ventricle. *J Ultrasound Med* 2012;31:654-656.
3. Lagopoulos ME, Manlhiot C, McCrindle BW, Jaeggi ET, Friedberg MK, Nield LE. Impact of prenatal diagnosis and anatomical subtype on outcome in double outlet right ventricle. *Am Heart J* 2010;160:692-700.
4. Obler D, Juraszek AL, Smoot LB, Natowicz MR. Double outlet right ventricle: aetiologies and associations. *J Med Genet* 2008;45:481-497.
5. Schallert EK, Danton GH, Kardon R, Young DA. Describing



- congenital heart disease by using three-part segmental notation. *Radiographics* 2013;33:E33-46.
6. Brown JW, Ruzmetov M, Okada Y, Vijay P, Turrentine MW. Surgical results in patients with double outlet right ventricle: a 20-year experience. *Ann Thorac Surg* 2001;72:1630-1635.
 7. Bhatla P, Tretter JT, Chikkabyrappa S, Chakravarti S, Mosca RS. Surgical planning for a complex double-outlet right ventricle using 3D printing. *Echocardiography* 2017;34:802-804.

Alireza Golbabaie, MD

Assistant Professor of Pediatric Cardiology,
Tehran University of Medical Sciences,
Shariati Hospital,
Jalal-e-Al-e-Ahmad Hwy,
Tehran,
Iran.
1411713135.
Tel: 098 21 84901000.
Fax: 098 21 88633039.
E-mail: alirezagolbabaie@yahoo.com.

Mohamad Taghi Majnoon, MD

Assistant Professor of Pediatric Cardiology,
Tehran University of Medical Sciences,
Children's Medical Center,
No 63, Gharib Ave,
Keshavarz Blv,
Tehran,
Iran.
1419733151.
Tel: 098 21 66929234.
Fax: 098 21 66930024.
E-mail: 107majnoon@gmail.com.

Ehsan Aghaei Moghadam, MD

Associate Professor of Pediatric Cardiology,
Tehran University of Medical Sciences,
Children's Medical Center,
No 63, Gharib Ave,
Keshavarz Blv,
Tehran,
Iran.
1419733151.
Tel: 098 21 66929234.
Fax: 098 21 66930024.
E-mail: Ehsan_ghaei1358@yahoo.com.

Azade Rastgar, MD

Assistant Professor of Perinatology,
Department of Obstetrics and Gynecology,

Tehran University of Medical Sciences,
Shariati Hospital,
Jalal-e-Al-e-Ahmad Hwy,
Tehran,
Iran.
1411713135.
Tel: 098 21 84901000.
Fax: 098 21 88633039.
E-mail: rastegar.a@yahoo.com.

Mahsa Naemi, MD*

Assistant Professor of Perinatology,
Department of Obstetrics and Gynecology,
Tehran University of Medical Sciences,
Shariati Hospital,
Jalal-e-Al-e-Ahmad Hwy,
Tehran,
Iran.
1411713135.
Tel: 098 21 84901000.
Fax: 098 21 88633039.
E-mail: mahsanaemi@yahoo.com.