

Hardware Failure as a Rare Complication of Percutaneous Coronary Intervention: A Case Report

PapaRao Veera Venkata Ayyappa Krishna Sanka, DNB^{1*}, Madhava Rao Bathala, Mch¹, Aayush Poddar, DNB¹, Karthik Ravindra Kumar Raman, DNB¹, Chakravarthi Paulraj Sudhakar Ignatius, DM², Chandrasekar Padmanabhan, DNB¹

¹Department of Cardiothoracic Surgery, G Kuppuswamy Naidu Memorial Hospital, Coimbatore, Tamil Nadu, India.

²Department of Cardiology, G Kuppuswamy Naidu Memorial Hospital, Coimbatore, Tamil Nadu, India.

Received 19 July 2021; Accepted 28 August 2021

Abstract

Percutaneous coronary intervention (PCI) is increasingly employed in the treatment of complex coronary artery disease. The entrapment or fracture of a coronary angioplasty guidewire is a rare complication of PCI. We herein describe a 61-year-old man who presented with chronic stable angina. The patient's coronary angiogram revealed triple-vessel coronary artery disease, and he was scheduled for primary PCI. During the procedure, the guidewire fractured within the right coronary artery. Despite multiple attempts, the wire could not be retrieved. The wire unraveled in its coils, and its stretching resulted in its eventual snapping in the right radial artery. The initial plan was to attempt guidewire retrieval through a brachial cut-down, and if successful, to manage the obtuse marginal lesion by PCI, thereby precluding general anesthesia and a sternotomy. Unfortunately, the guidewire snapped at the brachial level, necessitating its retrieval by coronary artery bypass surgery. The patient remained asymptomatic and event-free over 6 months of follow-up.

J Teh Univ Heart Ctr 2021;16(4):169-173

This paper should be cited as: Sanka PVVAK, Bathala MR, Poddar A, Raman K, Ignatius CPS, Padmanabhan C. Hardware Failure as a Rare Complication of Percutaneous Coronary Intervention: A Case Report. *J Teh Univ Heart Ctr 2021;16(4):169-173.*

Keywords: Coronary artery disease; Percutaneous coronary intervention; Catheterization; Foreign bodies; Coronary artery bypass

Introduction

Percutaneous coronary intervention (PCI) is increasingly drawn upon;¹ it is, however, not without complications. PCI paraphernalia entrapment or guidewire fracture is an infrequent complication (0.1%–0.8%).² Al-Moghairi et al³ reported a series of 67 cases of entrapped guidewires following PCI, with surgical removal needed in 43.4% of

the cases. There are many methods described to retrieve the entrapped and fractured guidewires in the coronary arteries, with surgery as the last resort.⁴

Case Report

A 61-year-old man, who suffered from diabetes and

*Corresponding Author: PapaRao Veera Venkata Ayyappa Krishna Sanka, Department of Cardiothoracic and Vascular Surgery, G Kuppuswamy Naidu Memorial Hospital, PB No: 6327, Nethaji Road, PN Palayam, Coimbatore 641037, Tamil Nadu, India. Tel: +91 9963700679. E-mail: aparao.sanka@gmail.com.

hypertension and was a known case of coronary artery disease on medical management from 2014, presented with chronic stable angina. On evaluation, the echocardiogram showed regional wall motion abnormalities in the inferior wall with mild left ventricular dysfunction (ejection fraction =45%) and no valvular abnormalities. A trans-right radial coronary artery angiogram revealed distal left anterior descending artery (LAD) disease (45%–50%), a 90% lesion in the first obtuse marginal artery (OM), and a chronic total occlusion in the mid-right coronary artery (RCA) (Figure 1 a-c). A discussion among the heart-team members led to the decision to perform PCI on the OM and the RCA.

The right radial approach was selected for PCI with the aid of an AL1 guidewire catheter (Amplatz Left, Launcher Guiding Catheter, Medtronic) and a Fielder XT guidewire (ASAHI PTCA). Attempts to cross the RCA lesion proved unsuccessful, so a GAIA-2 guidewire (ASAHI Gaia Series) was utilized. The guidewire then appeared to cross the lesion, possibly subintimally; hence, it was inflated to 12 atm. The

inability to cross the lesion any further, together with the buckling of the guidewire noticed proximally, prompted the retrieval of the guidewire. There were multiple attempts to retrieve the wire via the balloon inflation technique with a 2.0 × 9 mm catheter, but in vain. The wire unraveled in its coils, and its stretching led to its eventual snapping in the right radial artery.

As part of our open disclosure policy, the incident was discussed with the patient's family. A decision was made to perform the surgical retrieval of the guidewire and coronary artery bypass grafting (CABG). The patient was then started on a heparin infusion. He had no chest pain, arrhythmias, and new ST-T changes in the electrocardiogram during or after the attempted PCI procedure.

Our initial plan was to attempt guidewire retrieval through a brachial cut-down, and if successful, to manage the OM lesion by PCI, thereby precluding general anesthesia and a sternotomy. We hoped there would not be much fibrosis or adherence of the guidewire in the coronary artery and that traction on the wire in the brachial artery would help

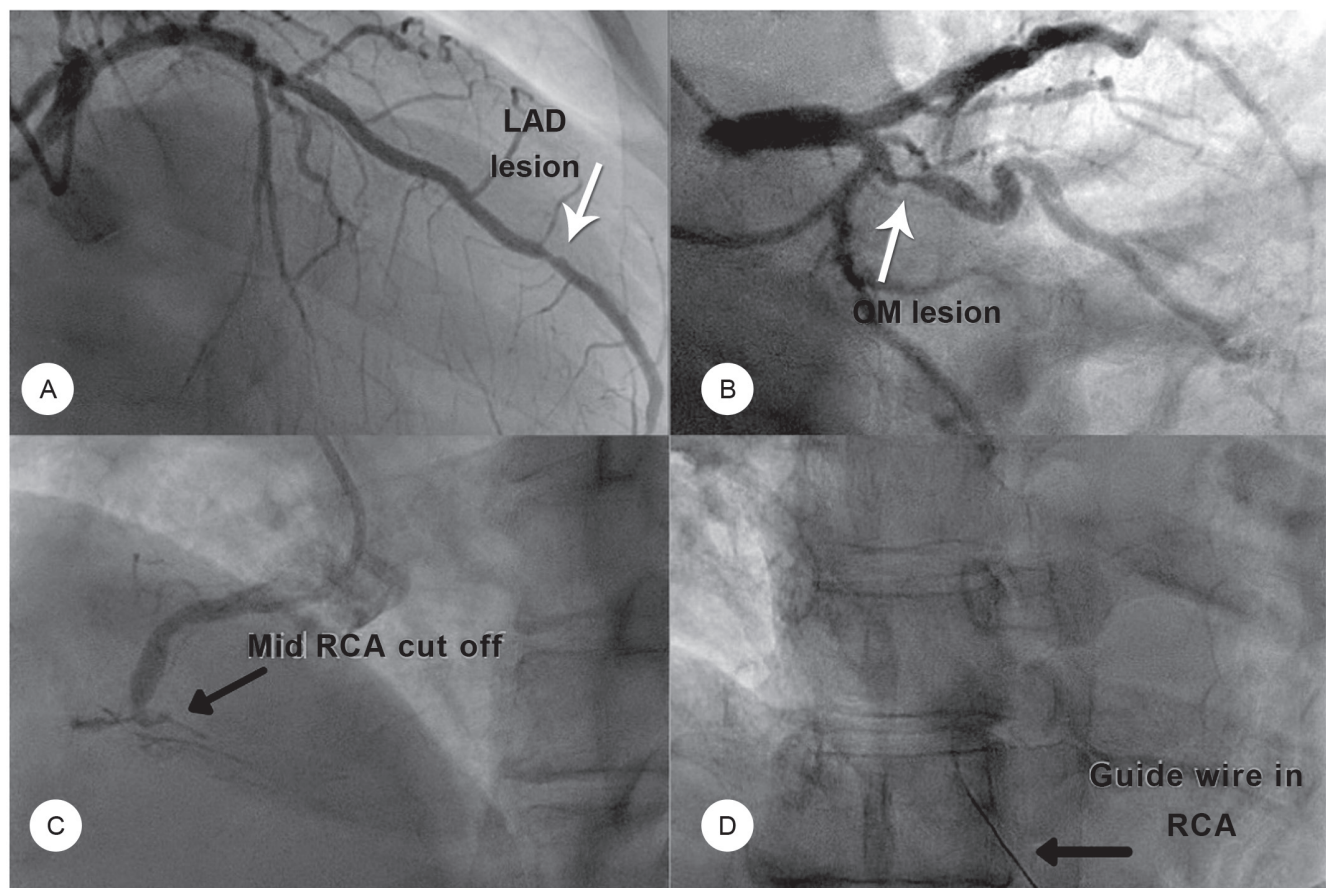


Figure 1. The coronary angiogram shows vessels involved with coronary artery disease, and the fluoroscopic image depicts the guidewire in the RCA.

- A) The RAO caudal angiographic view shows the LAD and distal atherosclerotic involvement. (The white arrow points at the lesion.)
B) The RAO cranial angiographic view depicts a tight proximal OM1 lesion. (The arrow points at the lesion.)
C) The RAO cranial angiographic image shows the chronic total occlusion of the mid-RCA. (The black arrow points at the mid-RCA cutoff.)
D) The fluoroscopy image illustrates the guidewire entrapped in the RCA (the black arrow).

RCA, Right coronary artery; RAO, Right anterior oblique; LAD, Left anterior descending artery; OM, Obtuse marginal

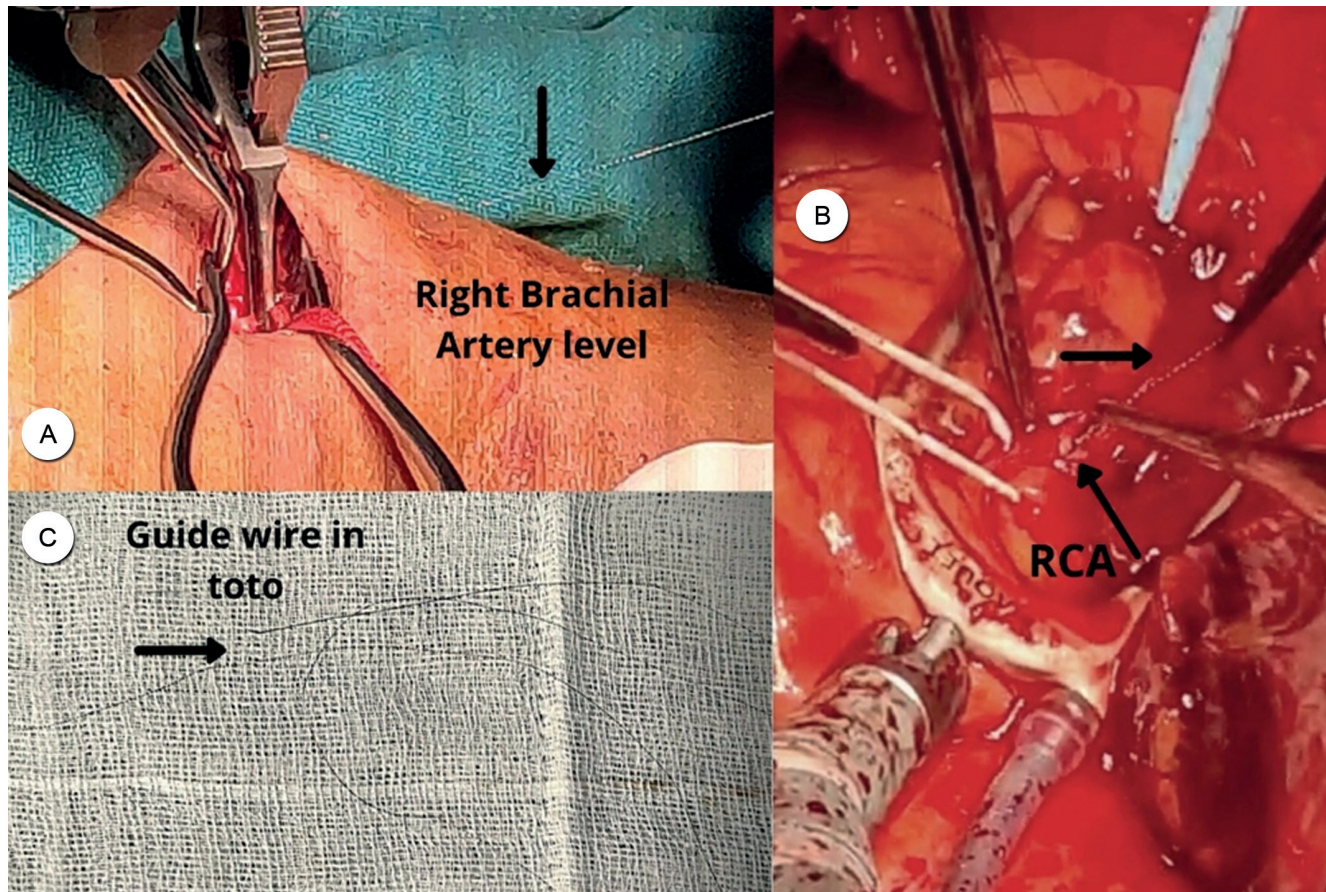


Figure 2. The intraoperative images show the retrieval of the guidewire at various levels and the guidewire in toto after its retrieval.

A) The image depicts an attempt to retrieve the guidewire through a brachial arteriotomy (the black arrow).

B) The intraoperative picture shows a distal RCA arteriotomy after stabilization with the aid of a MAQUET Acrobat-i Stabilizer and the retrieval of the guidewire (the small black arrow). The large arrow points to the RCA.

C) The guidewire is visualized after successful retrieval.

RCA, Right coronary artery

retrieval. The patient was prepped for CABG with the right arm in the surgical field after a right axillary nerve block. The right brachial artery was exposed via a small antecubital incision. Brachial arteriotomy was performed after systemic heparinization (1 mg/kg), the guidewire was identified, and the distal part of the wire was drawn into the wound.

Efforts to retrieve the guidewire's proximal portion, which was stuck in the coronary artery, proved ineffectual, and it snapped above the brachial artery incision (Figure 2a). Subsequently, a midline sternotomy was performed under general anesthesia, and the pericardium was opened. An area of significant contusion was observed over the right atrioventricular groove in the region of the distal RCA. A MAQUET Acrobat-i Stabilizer was used to position the heart for distal RCA grafting. From the mid-RCA onward, including the posterior descending artery and the posterior left ventricular branch artery, severe disease was detected, along with the scarring of the underlying myocardium. A heparin top-up was administered to achieve the dose of 2 mg/kg for off-pump CABG. The RCA was opened in the

region of maximum contusion with a view to locating the tip of the guidewire. Nonetheless, the severe calcific disease made the entry into the lumen of the RCA challenging.

Eventually, the guidewire was identified coursing further distally into the plaque of the RCA, where it might have become tightly entrapped. Accordingly, the arteriotomy was extended, and the guidewire was gently retrieved via cardiac contraction with *vis a fronte* and *vis a tergo* (similar to developing an endarterectomy plane in off-pump CABG). By careful dissection, the guidewire was separated from the surrounding plaque and removed under vision *in toto* (Figure 2b). An intact tip ensured the complete removal of the wire (Figure 2c). With no suitable target vessel to revascularize, the arteriotomy was closed through overrunning with a 6-0 polypropylene suture. Afterward, off-pump CABG ($\times 2$ grafts) was performed, and saphenous vein grafts were anastomosed to the OM¹ and the distal LAD (close to the apex) uneventfully. The left internal mammary artery was not chosen for grafting because of the borderline severity of the LAD lesion.

The patient made a stable recovery in the postoperative

period and was discharged home on the fifth postoperative day. On periodic follow-up, the patient remained asymptomatic (New York Heart Association functional class I) with mild left ventricular dysfunction (ejection fraction = 49%).

Discussion

In this stenting era, the reuse of guidewires or balloons is a common occurrence in various interventional units. Due to this reuse policy, the dislodgement of a stent from its delivery balloon and the failure of stent delivery balloon to inflate or deflate, especially in cases of severely calcified and tortuous coronary vessels, are increasing tremendously.⁵ Possible complications during PCI include coronary perforation, stent deformation, stent loss, wire fracture and/or loss, device embolization, and wire entrapment.

Concerning coronary perforation with an estimated incidence rate of 0.43%, the most important risk factors are rotatable devices and vigorous handling of stiff guidewires through complex calcified vessels. Management strategies include observation, heparin reversal, covered stents, pericardiocentesis, and surgery.⁶

Regarding stent deformation, longitudinal stent deformation (LSD), defined as the distortion of a stent in the longitudinal axis, is a significant complication of PCI. LSD usually occurs at the proximal stent edge owing to compression by guide catheters or catheter extensions, leading to stent thrombosis and death. LSD is challenging to detect angiographically, but the findings have important implications on current and future stent designs. Since prevention is better than cure, avoiding contact between the guide/catheter extensions during proximal vessel stenting is crucial to prevent guide-induced LSD.⁷

Device embolization is a rare complication resulting from the loss of stents, guidewires, or catheter fragments within the coronary vessels. Severely calcified vessels, extreme tortuosity, and angulation result in stent dislodgement and further embolization. Such devices are immediately retrieved to avoid the adverse effects of device embolization such as severe myocardial infarction and death. The use of additional guidewires and extension catheters, including gooseneck snares, comprises the interventional techniques to retrieve trapped devices, and if unsuccessful, emergency surgery is preferred.

PCI guidewire fracture and entrapment are not infrequent complications that may occur due to various reasons,⁴ predominantly because of the repeated use of the same guidewire. Recurrent usage leads to structural deformation, which increases the risk of entrapment in the coronary vessel. Vigorous handling, over-rotation, or entrapment of the distal tip of the guidewire in a coronary vessel can also lead to wire fracture.² The flexible tip of the wire can

accidentally enter a small branch vessel (especially the RCA with acute angulation [“Shepherd’s Crook” curve of the RCA]), leading to severe spasms. The wire may also become entrapped within the atheroma or an obstructed vessel, rendering its retrieval challenging (Panda BR, Thomson VS, Shankar R, Kuruvilla KT, Thankachen R, Shukla V. Stuck coronary angioplasty balloon: A surgical emergency. *Indian Journal of Thoracic and Cardiovascular Surgery* 2009;25:124–126.). Moreover, repeated attempts at crossing the same lesion multiple times with the same wire or when using 2 wires (the “Buddy wire” technique) to cross fresh stent struts may result in the entrapment of the wire.⁸

The failure to retrieve the entrapped coronary guidewire can be due to coronary vessels taking off at 90° of the side branch and its tortuosity; plaque shifting (both in the main and in the side branches), causing guidewire entrapment, especially in the bend of the vessel; and stent implantation in a curved segment of the main vessel, which can transmit a greater radial force on the stuck guidewire.⁴

PCI on complex, severely calcified vessels and bifurcating vessels could be risky; consequently, in such cases, it is best to avoid complications by selecting a guidewire appropriate for the target vessel.

For the retrieval of the retained pieces of wires, the mode of intervention can be either percutaneous or surgical (and conservative if neither is possible).³ The percutaneous techniques include the double- or triple-wire technique, the deep wedging of the guiding catheter and the traction of the system, retrieval using the balloon inflation technique, retrieval with snare loops, retrieval with microcatheters (eg, Tornus catheters), extraction with the Biotome catheter, and stenting against the vessel wall. The “child-in-a-mother catheter” technique may also be considered to improve support for coronary interventions. In this technique, a long, flexible, and lower profile (“child”) guide catheter is introduced into the conventional guide catheter (“mother”).⁹ Rotational atherectomy may be useful, particularly for severely complex calcific diseases such as the Kokeshi phenomenon.¹⁰

There are case reports where retained PCI guidewires stuck in coronaries or smaller distal vessels were managed conservatively on systemic anticoagulation and antiplatelet agents with close follow-ups.¹¹ In our case, the guidewire probably became stuck in the plaque of a heavily calcified and diseased RCA, and the use of force during removal resulted not only in the unraveling of the guidewire inside the RCA but also the fracture of the guidewire. Feeling that the LAD lesion was not very tight, and the circumflex lesion was amenable for PCI, we tried to grab the wire in the brachial artery level and retrieve it so that we could avoid a sternotomy. However, we failed to remove the guidewire at the peripheral arterial level, so we proceeded with a sternotomy for guidewire retrieval and a simultaneous



coronary revascularization procedure.

Conclusion

There are only anecdotal reports of the surgical retrieval of entrapped coronary guidewires. Surgical interventions are indicated to prevent the deleterious effects of arrhythmia, embolization, infection, and nidus for thrombus formation. In situations where the coronaries are severely diseased, the anticipation of complications associated with PCI is of paramount importance. A heart team at a comprehensive heart care center should ideally treat such complicated scenarios to achieve the best possible outcome by weighing the risks and benefits of every treatment modality, as was the case in the patient described herein.

References

1. Holmes DR, Jr, Williams DO. Catheter-based treatment of coronary artery disease: past, present, and future. *Circ Cardiovasc Interv* 2008;1:60-73.
2. Balbi M, Bezante GP, Brunelli C, Rollando D. Guide wire fracture during percutaneous transluminal coronary angioplasty: possible causes and management. *Interact Cardiovasc Thorac Surg* 2010;10:992-994.
3. Al-Moghairi AM, Al-Amri HS. Management of retained intervention guide-wire: a literature review. *Curr Cardiol Rev* 2013;9:260-266.
4. Balbi M, Bezante GP, Brunelli C, Rollando D. Guide wire fracture during percutaneous transluminal coronary angioplasty: possible causes and management. *Interact Cardiovasc Thorac Surg* 2010;10:992-994.
5. Singh J, Thingnam SK, Das D, Singh H, Sharma R, Vijayvergia R. Surgical removal of entrapped and broken percutaneous transluminal coronary angioplasty balloon catheter. *Interact Cardiovasc Thorac Surg* 2007;6:94-96.
6. Shimony A, Joseph L, Mottillo S, Eisenberg MJ. Coronary artery perforation during percutaneous coronary intervention: a systematic review and meta-analysis. *Can J Cardiol* 2011;27:843-850.
7. Ragkousis GE, Curzen N, Bressloff NW. Simulation of longitudinal stent deformation in a patient-specific coronary artery. *Med Eng Phys* 2014;36:467-476.
8. Vijayvergiya R, Swamy AJ, Grover A. Buddy wire technique: a simple technique for treating calcified lesion during percutaneous coronary intervention: a case report. *J Invasive Cardiol* 2006;18:E129-130.
9. Cunningham M, Egred M. GuideLiner, a child-in-a-mother catheter for successful retrieval of an entrapped rotablator burr. *Catheter Cardiovasc Interv* 2012;79:271-273.
10. Kaneda H, Saito S, Hosokawa G, Tanaka S, Hiroe Y. Trapped rotablator: Kokesi phenomenon. *Catheter Cardiovasc Interv* 2000;49:82-84.
11. Hartzler GO, Rutherford BD, McConahay DR. Retained percutaneous transluminal coronary angioplasty equipment components and their management. *Am J Cardiol* 1987;60:1260-1264.