

Evaluation of Right Ventricular Outflow Tract Stenting as Palliative Treatment in Severely Cyanotic Tetralogy of Fallot: A Systematic Review and Meta-analysis of Observational Studies

Andrea Laurentius, MD^{1*}, Lowilius Wiyono, MD¹, Anita Dominique Subali, MD², Sisca Natalia Siagian, MD³

¹Faculty of Medicine, Universitas Indonesia, Jakarta, Indonesia.

²Faculty of Medicine, Universitas Brwajaya, East Java, Indonesia.

³National Cardiovascular Center Harapan Kita, Jakarta, Indonesia.

Received 11 March 2021; Accepted 04 July 2021

Abstract

Background: Tetralogy of Fallot (ToF) is a cardiac malformation that accounts for up to 1/10 of all congenital diseases. Although surgical repair serves as a treatment of choice, it cannot be performed unless weight and anatomical key factors are favorable. The stenting of the right ventricular outflow tract (RVOT) has become an alternative palliative procedure for ToF as an option to alleviate infundibular obstruction with minimal invasion.

Methods: A literature search was conducted through 7 databases, followed by the screening and independent assessment of 6 final studies, using the Newcastle-Ottawa Quality Assessment Scale (NOS). Analysis was then conducted using inverse variance analysis, and cumulative data were presented with forest and funnel plots.

Results: Studied patients were referred for RVOT stenting due to the marked obstruction of the pulmonary blood flow, a low birth weight, or a small pulmonary artery size. The analysis revealed a significant increase in O₂ saturation (mean difference [MD]=18%; 13–23.78). The same trend was observed concerning an increase in the Nakata index (MD=54.59; 10.05–99.14), the right pulmonary artery diameter (MD=2.28; 1.20–3.36), and the left pulmonary artery diameter (MD=1.77; 0.22–3.32). Several complications were found, including tricuspid regurgitation and frequent premature beats.

Conclusion: RVOT stenting is considered a feasible palliative treatment for ToF, with its high effectiveness in improving patients' condition, especially their pulmonary flow. While complications are scarce, several conditions should be noted, particularly for fatal complications. Finally, this study has limitations as catheterization details in studies and diverse infants' conditions may have caused potential bias.

J Teh Univ Heart Ctr 2021;16(4):135-146

This paper should be cited as: Laurentius A, Wiyono L, Subali AD, Siagian SN. Evaluation of Right Ventricular Outflow Tract Stenting as Palliative Treatment in Severely Cyanotic Tetralogy of Fallot: A Systematic Review and Meta-analysis of Observational Studies. J Teh Univ Heart Ctr 2021;16(4):135-146.

Keywords: Tetralogy of Fallot; Palliative care, Safety; Postoperative complications; Ventricular outflow obstruction

*Corresponding Author: Andrea Laurentius, Universitas Indonesia (UI), Kampus Baru UI Depok, Jawa Barat – 16424, Jakarta, Indonesia. Tel: +62 21 786 7222. E-mail: laurentiusandrea@gmail.com.

Introduction

Tetralogy of Fallot (ToF), defined as a congenital cardiac malformation consisting of an interventricular communication, is commonly regarded as a ventricular septal defect, the obstruction of the right ventricular outflow tract (RVOT), the overriding of the ventricular outflow tract by the aortic root, and RV hypertrophy.¹ ToF is the most prevalent cause of cyanotic cardiac anomalies, which account for up to one-tenth of all congenital defects and uniformly affect males and females in 3 to 5 of every 10 000 live births.² The cyanotic manifestations of ToF are associated with limitations in the pulmonary blood flow as a result of a combination of stenotic pulmonary valves and significant RVOT infundibular obstruction.^{3,4}

In consideration of such conditions, the management of infants with ToF suffering from an excessively reduced pulmonary flow and cyanosis has been a palliative intervention until or unless a complete repair is feasible.⁵ Palliation involves procedures that augment the pulmonary flow, which supports a potentially more effective repair in the future.⁶ Blalock–Taussig–Thomas (BTT) shunts are the initial strategy in these patients.⁷ However, BTT shunts performed in high-risk infants are also associated with increased indices of complications, including pulmonary artery (PA) stenosis, excessive pulmonary blood flow, and, occasionally, mortality.⁸ RVOT stenting has become a proposed initial palliative procedure for ToF.⁹ It emerged as an attractive option to alleviate infundibular and pulmonary valve obstruction, promoting the anterograde pulsatile pulmonary blood flow and increasing oxygen saturation. The stenting of the RVOT not only results in a better physiological hemodynamic outcome but also promotes the growth of pulmonary arteries and delays the need for early surgery.^{3,7,10} Additionally, it is gaining popularity because it offers advantages such as alleviated cyanosis, enhanced pulmonary arteries, better weight increments, and finally, a better substrate for repair in the future.^{4,11}

Even though RVOT stenting has stood out as the main bridging procedure and its safety has been demonstrated, it is still a technically challenging procedure with significant risks for complications and susceptibility to procedure failures.^{3,9} Therefore, we performed a systematic review and meta-analysis to evaluate the safety and feasibility of the RVOT stenting procedure in high-risk pediatrics with cyanotic ToF. We hope that the results of this study will provide beneficial information regarding the feasibility and potential complications of performing palliation to manage preventive measures for improved clinical outcomes.

Methods

This systematic review was conducted following the Preferred Reporting Items for Systematic Review and Meta-Analysis (PRISMA) 2020 guidelines to properly search for relevant studies.¹² The protocol of this systematic review was registered in PROSPERO (registration number: CRD42021260350).

Search Strategy

The literature search was done through 7 electronic scientific databases in February 2021 independently by 4 investigators (LW, AL, ADS, and SNS). Five databases, consisting of PubMed, Cochrane, EMBASE, ScienceDirect, and Scopus, were used to screen for published and peer-reviewed articles, while the investigators also drew upon clinical trial protocols from ClinicalTrials.gov and preprint articles on medRxiv to find more unpublished studies on similar topics. The literature search strategies were developed using medical subject headings (MeSH) in scientific databases with keywords related to the RVOT stenting complications of cyanotic ToF. The used keywords of each database are listed in Table 1. Subsequently, the identified results were

Table 1. Keywords or queries used in each database for the literature search process

Database	Queries	Hits
PubMed	(((((fallot s tetralogy[MeSH Terms]) OR (fallot tetralogy[MeSH Terms])) OR (fallot's tetralogy[MeSH Terms])) OR (fallot[MeSH Terms]))AND ((right ventricular outflow tract) OR (RVOT)) AND ((stent[MeSH Terms]) OR (stenting[MeSH Terms])) AND (complication))	24
Cochrane	MeSH descriptor: [Tetralogy of Fallot] explode all trees AND MeSH descriptor: [Ventricular Outflow Obstruction] explode all trees AND MeSH descriptor: [Stents] explode all trees AND MeSH descriptor: [Postoperative Complications] explode all trees	0
ClinicalTrials.gov	((("Cyanotic" AND ("Tetralogy of Fallot" OR "ToF")) AND ("Right Ventricular Outflow Tract" OR "RVOT") AND "Stenting" AND ("Complication" OR "Complications"))	0
EMBASE	(Right ventricular outflow) AND (stent) AND (complication) AND (tetralogy of fallot)	0
ScienceDirect	(Right ventricular outflow) AND (stent) AND (complication) AND (tetralogy of fallot)	31
Scopus	TITLE-ABS-KEY ((cyanotic AND ("Tetralogy of Fallot" OR "ToF")) AND (("Right ventricular outflow tract" OR "RVOT") AND ("Stenting" OR "Stent")) AND ("Complications" OR "Complication"))	6
MedRxiv	((("Cyanotic" AND ("Tetralogy of Fallot" OR "ToF")) AND ("Right Ventricular Outflow Tract" OR "RVOT") AND "Stenting" AND ("Complication" OR "Complications"))	0



deduplicated, searched for retrieval, and screened against pre-specified eligibility criteria.

Study Eligibility Criteria

Inclusion criteria were arranged to filter primary studies investigating the complications of the RVOT stenting procedures on patients with cyanotic ToF using the PICO (Patient, Intervention, Comparison, Outcome) criteria (Table 2). This review included investigations consisting of prospective and retrospective cohort studies evaluating the acute outcomes (within the first 30 post-treatment days) of RVOT stenting in pediatric patients below 18 years old with cyanotic conditions only due to ToF and indicated for RVOT stenting as a palliative intervention. Studies were excluded if any one of the following criteria was fulfilled: 1) review articles or letters to editors, 2) articles on patients with other congenital heart defects or comorbidities, 3) articles with inadequate endpoint data, and 4) non-English articles.

Table 2. PICO criteria, consisting of 4 parameters: patient, intervention, comparison, and objective criteria

Parameter of PICO	Inclusion Criteria
Patient	Cyanotic tetralogy of Fallot, pediatrics (0-18 years old)
Intervention	RVOT stenting
Comparison	-
Outcome	Post-RVOT stenting complication

PICO, Patient/intervention/comparison/outcome; RVOT, Right ventricular outflow tract

Study Selection

Having completed the search and screening process in the proposed databases, the authors manually checked and removed duplicate articles. Primarily, the titles and abstracts of the identified articles were screened to exclude irrelevant studies. The reviewers mentioned the underlying reason to exclude any items in a spreadsheet. Studies were included for the following step if there was any uncertainty. Subsequently, the authors read the full text in order to exclude studies that did not meet the inclusion criteria. A data extraction form was designed to compile information from the included studies. The selection process and data extraction were conducted by 3 independent investigators (LW, AL, and ADS). The results were then confirmed and cross-checked by the chief investigator (SNS). All discrepancies were discussed before the next step.

Data Extraction and Quality Assessment

All 4 reviewers extracted data from full-text articles independently. The following study details were extracted:

studies' authors, publication years, median patients' age and weight, sample sizes, follow-up periods, reasons for stenting indications, comorbidities, RVOT stenting characteristics, and procedural outcomes. The reviewers also recorded pre-catheterization and post-catheterization report details such as the Nakata index, the right pulmonary artery (RPA) diameter, the left pulmonary artery (LPA) diameter, the McGoon ratio, and the O₂ saturation level to provide comparable conditions before and after the procedure.

The eligible studies were subjected to methodological quality assessment so as to minimize systematic biases and inferential errors from the extracted data using the Newcastle-Ottawa Quality Assessment Scale (NOS).¹³ The NOS evaluates nonrandomized studies on systematic reviews across 3 quality parameters: study selection, population comparability, and determination of whether the exposure or the outcome includes the risk of bias.¹² The NOS evaluated each study quality and yielded a maximum score of 9 points. Studies with NOS scores equal to or greater than 7 are considered high quality. Studies with NOS scores of 5 or 6 represent fair or moderate quality, whereas studies with NOS scores less than 5 indicate a high risk of bias. (Higgins J, Thomas J, Chandler J, Cumpston M. Cochrane handbook for systematic reviews of interventions. 2nd ed. Hoboken: The Cochrane Collaboration; 2019. p.1–539) The 4 reviewers conducted the quality assessment independently, and the results were then discussed to obtain conclusions on the quality of each included study.

Quantitative Analysis

Quantitative analysis was conducted by AL, using the software Review Manager 5.4 (the Cochrane Collaboration). A meta-analysis was conducted via random-effect pairwise with the mean difference as the variable for the analysis (with a 95% confidence interval and $P < 0.05$ indicating a significant correlation/comparison). The extracted data for the quantitative analysis were inputted to the software with inverse-variance analysis. The pooled analysis was thereafter extrapolated into a forest plot and publication bias using a funnel plot. Six studies were used for the meta-analysis with 5 variables for the analysis: systematic oxygen saturation, pre- and postprocedural diameters of the LAP and the RPA, the McGoon criteria, and the Nakata index to describe the cumulative outcome of RVOT stenting.

Results

Study Selection and Characteristics

The literature search and screening process are summarized in Figure 1 with the aid of the PRISMA 2020 Guideline flowchart.¹² Following deduplication, screening, and careful assessment of the full texts based on the

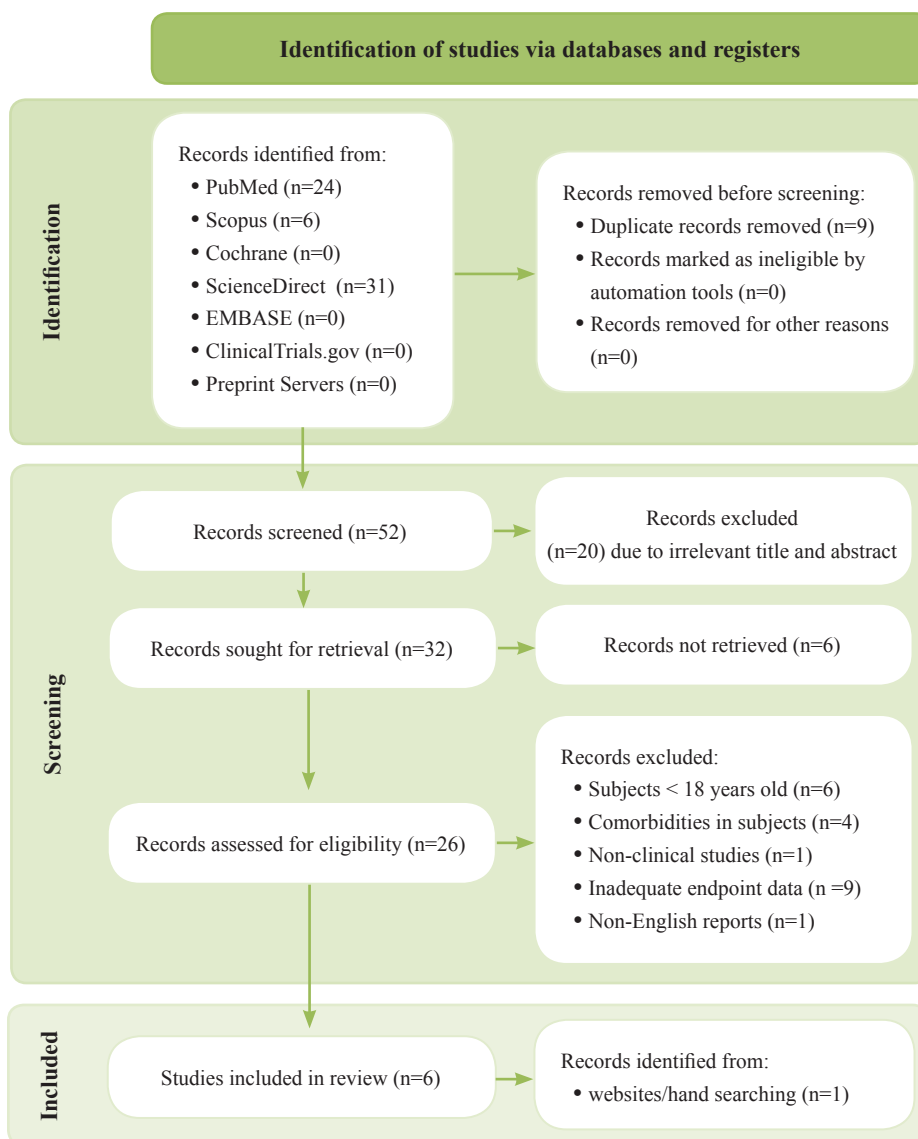


Figure 1. The image illustrates the literature search and screening strategy flowchart based on the PRISMA Guideline.¹²

inclusion and exclusion criteria, we included 5 final articles. Four of the studies were retrospective studies, consisting of case series on RVOT stenting, while one of them (Bigdelian et al) was a case-control study.¹¹ One additional article (Sandoval et al) was found in the PubMed database via the hand-searching process.¹⁴ Each article featured an observational study ranging from 11 months to 24 months on all RVOT stenting procedures in its respective healthcare facilities. The outcomes of each study compared pre- and post-catheterization results with respect to the pulmonary blood flow index and the O₂ saturation level.

Risk of Bias Assessment Results

The 6 selected articles were critically appraised for their criteria, comprising sample selection, comparability, and outcome. All the studies exhibited good quality

based on quantitative scoring summarized in Table 3 and visually represented in Figure 2, except for the article by Peirone et al. The fair quality of this study was due to the involvement of different sources of samples, as well as displaying outcome interests at the beginning of the study. In terms of loss during follow-up, 1 infant in the article by Bigdelian et al suffered acute respiratory distress syndrome and died, whereas 2 infants in the article by Bertram et al experienced stenting failure and the embolization of the balloon stent to the RV, respectively. However, we have described any missing information in the reports related to complications in the review, thus not adding significant bias to the respective studies.

Patients' Demographic Data

All patients in the studies (Table 4) were referred for



palliative RVOT stenting due to various concerns such as ToF with marked limitations in the pulmonary blood flow, premature birth with significant lung abnormalities, birth with other noncardiac comorbidities, and low body weight (< 5 kg). Additional criteria included the small anatomical size of the PA confirmed with a McGoon ratio below less than 1.5 or a Nakata index less than 120 mm²/m² (z-score of the PA growth < -2.5).³ Other ToF comorbidities such as double-outlet RVs, PA stenosis, and atrioventricular septal defects were still indicated for palliative stenting if there was oligemia with deep cyanosis.¹¹ Most patients required prostaglandin infusions to maintain the recirculation of the deoxygenated blood from the aorta to the PA as duct closure might result in a grave prognosis. Several patients' comorbidities were discovered in the article by Bertram et al such as malformation sequences, chronic liver disease,

and acute respiratory infections.¹⁴ In the studies, congenital heart defects causing severe hypoxemia with cyanotic spells (especially ToF) and low birth weight were the main indications for RVOT stenting as palliative treatment.^{3,4,7,11,1} While other forms of congenital heart disease were excluded, most studies included infants with other comorbidities, including intrauterine growth restriction, cleft lip palate, and prematurity. Nonetheless, the article by Peirone et al did not include any comorbidities.^{3,4,7,11}

Catheterization Details

The procedure is conducted under general anesthesia with antegrade access. The insertion of the catheter via the Seldinger technique begins from the femoral vein. Subsequently, heparin is administered to attain an activated

Table 3. Results of the Newcastle-Ottawa Quality Assessment Scale of the included studies

Assessments	Subpoints	Studies					
		Castleberry et al	Bigdelian et al	Valderrama et al	Sandoval et al	Peirone et al	Bertram et al
Selection	Representative of the exposed cohort	Somewhat representative	Truly representative	Truly representative	Truly representative	Truly representative	Somewhat representative
	Selection of the non-exposed cohort	Drawn from the same community of the exposed cohort	Drawn from the same community of the exposed cohort	Drawn from different sources	Drawn from different sources	Drawn from different sources	Drawn from different sources
	Ascertainment of exposure	Secure record	Secure record	Secure record	Secure record	Secure record	Structured interview
Comparability	Demonstration that outcome of interest was not present at start of study	No	Yes	Yes	No	No	Yes
	Comparability of cohorts on the basis of the design or analysis controlled for confounders	Studies control for other factors, such as age, sex, and weight	Studies control for other factors, such as age, sex, and weight	Studies control for other factors, such as age, sex, and weight	Studies control for other factors, such as age, sex, and weight	Studies control for other factors, such as age, sex, and weight	Studies control for other factors, such as age, sex, and weight
	Assessment of outcome	Record linkage	Independent blind assessment	Self-report	Independent blind assessment	Independent blind assessment	Record linkage
Outcome	Was follow-up long enough for outcomes to occur	Yes, 24 months are enough for follow-up definitive treatment	Yes, 17 months are enough for follow-up definitive treatment	Yes, 11 months are enough for follow-up definitive treatment	Yes, 13 months are enough for follow-up definitive treatment	Yes, 13 months are enough for follow-up definitive treatment	Yes, 7.5 months are enough for follow-up definitive treatment
	Adequacy of follow-up of cohorts	Complete follow-up- all subject accounted for	Subjects lost to follow-up unlikely to introduce (lost less than 20%)	Complete follow-up- all subject accounted for	Complete follow-up- all subject accounted for	Complete follow-up- all subject accounted for	Subjects lost to follow-up unlikely to introduce (lost less than 20%)
	Overall Score	Good	Good	Good	Fair	Fair	Good

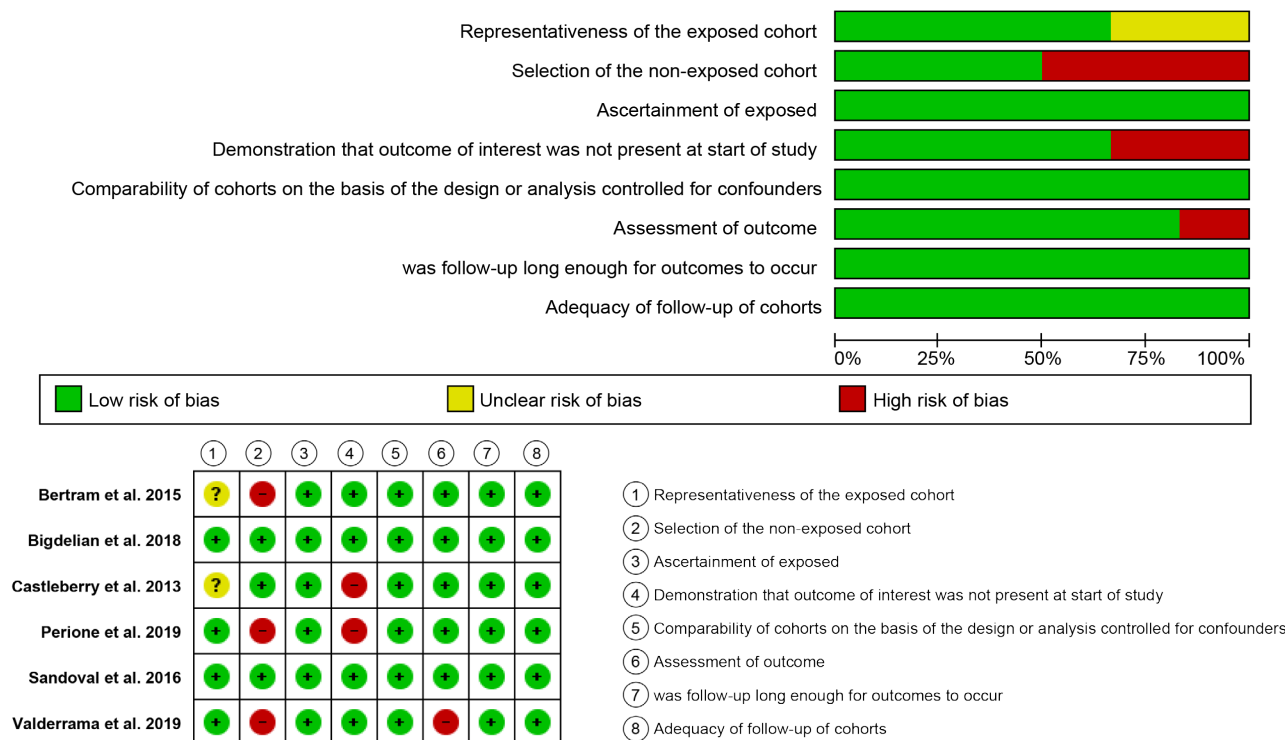

Figure 2. The images illustrate a summary of the Newcastle Ottawa Scale (NOS) risk of bias and a summary of the authors' judgment regarding each risk of bias item for each included study.

partial thromboplastin time longer than 180 seconds. Wire positioning across the infundibulum as part of the RVOT is confirmed with a pressure tracker and/or contrast-guided fluoroscopy. Wire passage through the RVOT is facilitated with a right coronary catheter featuring a 1.5 to 2 cm curve.³ Patients have prostaglandin E1 infusions during the procedure. Furthermore, the periventricular hybrid approach is an alternative to the classic percutaneous technique concerning RVOT stent placement.⁴ Choosing the correct stent size is based on the weight of infants or neonates, the infundibular length of the RVOT, and the anticipated length of palliation. A larger dimension, between 1 and 2 mm, than the pulmonary annulus is one of the criteria for size selections.¹¹

Post-Stenting Results and Meta-analysis

For the description of the feasibility of RVOT stenting in infant candidates for future corrective repair, 4 quantitative variables were mentioned as the endpoints of the studies: oxygen saturation, the PA diameter, the Nakata index, and the McGoon ratio. Post-RVOT stenting in the article by Sandoval et al led to a significant rise in the pulmonary valve annulus z-score up to +4.6 (SD=3.6–5.5).¹⁵ Nonetheless, there was a lack of data on the pulmonary valve annulus and the RVOT infundibular diameter in the included studies, except for the article by Sandoval et al. We, consequently, excluded the

variables as part of the pooled analysis. A meta-analysis of the random effect was then conducted to obtain information regarding the feasibility of RVOT stenting in high-risk infants (Figure 3). All the studies reported the benefits of RVOT stenting in terms of increasing the mean percentage of systemic oxygen saturation up to 18% (95% CI, 13–23.78; P<0.01). An increase in the McGoon ratio from 0.8 to 1.4 was found in studies by Castleberry et al and Bigdelian et al, indicating marked blood flow to the pulmonary circulation. Furthermore, accelerated increases of 2.28 mm in the RPA diameter (95% CI, 1.2–3.36; P<0.01) and 1.17 mm in the LAP diameter (95% CI, 0.22–3.32; P=0.02) before and after the placement of stents in the RVOT, respectively, were well noted in the articles by Castleberry et al, Bigdelian et al, and Valderrama et al. In addition, another pulmonary blood flow index, the Nakata index, increased for up to 54.64 mm²/m² the body surface area (95% CI, 10.02–99.26; P=0.02) during the post-RVOT stenting follow-up in all the studies, except for the articles by Peirone et al, Sandoval et al, and Bertram et al. Further, the article by Peirone et al failed to show any catheterization-related details as the follow-up sequence was not done until complete ToF repair, whereas such details were provided by both Sandoval et al and Bertram et al.^{3, 4, 7, 11, 15} Our meta-analysis of all the variables exhibited significant heterogeneity (I² >50%), thus emphasizing the variety in RVOT stenting results. Our sensitivity analysis revealed that articles by Bigdelian et al



Table 4. Summary of data extraction and patient characteristics

Author	Median Patients' Age (Median weight)	Sample Size	Observation Period	Stenting Indications	Comorbidities	RVOT Stent Characteristics	Complications	
							Live	Death
Castleberry et al (2014)	15 days old (2.6 kg)	5 neonates	24 months (retrospective study)	<ul style="list-style-type: none"> Severe cyanotic ToF Hyper cyanotic spells Prostaglandin-dependent pulmonary blood flow 	<ul style="list-style-type: none"> Intrauterine growth restriction (n=2) Cleft lip palate (n=1) Prematurity (n=3) 	<ul style="list-style-type: none"> 4 mm diameter Multi-Link Vision stentTM 4.5 – 6 mm diameter EV3 ParaMount Mini GPS stentTM <p>All stents are balloon expandable</p>	<ul style="list-style-type: none"> Tricuspid regurgitation / flail anterior TV leaflets (n=1; 10 days) Iliofemoral vein occlusion (n=1; immediately) 	None
Bigdelian et al (2018)	48 days old (3.28 kg)	15 infants	17 months (case control)	<ul style="list-style-type: none"> Active cyanotic tetralogy of Fallot Low birth weight (<5 kg) with hyper cyanotic spell Small PAs size (McGoon ratio < 1.5; Nakata Index < 120 mm²/m²) 	<ul style="list-style-type: none"> Prematurity (n=1) 	<ul style="list-style-type: none"> 6-7 mm diameter / 12 – 16 mm length peripheral RVOT stents 	None	<ul style="list-style-type: none"> Acute respiratory distress syndrome (n=1; immediately)
Valderrama et al (2020)	20 days old (2.18 kg)	12 neonates	11 months (retrospective study)	<ul style="list-style-type: none"> Symptomatic ToF with deep cyanosis and hypoxic spell Severe pulmonary flow obstruction/atresia Prostaglandin-dependent infusion 	<ul style="list-style-type: none"> Prematurity (n=7) 	<ul style="list-style-type: none"> Multi-Link Vision stentTM Kaname stentTM Palmaz blue stentTM Palmaz genesis 2420 stentTM Median stent diameter was 5.25 mm with 15 mm median length 	<ul style="list-style-type: none"> Partial stent migration (n=1; 1 day) 	None
Peirone et al (2019)	40 days old (3.6 kg)	6 neonates	13 months (retrospective study)	<ul style="list-style-type: none"> Small PAs anatomy (z score < -2.5) Cardiogenic shock Cyanotic ToF at presentation Low birth weight Prostaglandin-dependent pulmonary blood flow 	N/A	<ul style="list-style-type: none"> Rebel 4.0 - 4.5 x 16 – 20 stentTM Express Vascular 6 x 18TM Integrity 4.0 x 22TM 	<ul style="list-style-type: none"> Frequent premature beats (n=1; immediately) 	None
Bertram et al (2015)	8 weeks old (3.3 kg)	33 infants	7.5 months (retrospective study)	<ul style="list-style-type: none"> Low birth weight (<3 kg) Hypoplasia of pulmonary arteries with coarctation of pulmonary artery MAPCA collateral arteries Cyanotic ToF 	<ul style="list-style-type: none"> Prematurity (n=8) Acute respiratory infection (n=2) Malformation syndromes VACTERL (n=2) Large Omphalocele (n=2) Chronic liver disease (n=2) 	<ul style="list-style-type: none"> Palmaz Blue stentTM Palmaz Genesis stentTM Median stent diameter was 6 mm with 15 mm 	None	None
Sandoval et al (2016)	21 days old (2.8 kg)	42 infants	15 months (retrospective study)	<ul style="list-style-type: none"> Low birth weight <2.5 kg Prematurity < 37 weeks' gestational age Pulmonary artery hypoplasia (z score < -2) Other non-cardiac comorbidities 	<ul style="list-style-type: none"> Sepsis (n=2) Neurological disorder (n=3) GI disorder (n=1) 	N/A	N/A	N/A

ToF, Tetralogy of Fallot; TV, Tricuspid valve; PA, Pulmonary artery; RVOT, Right ventricular outflow tract; MAPCA, Major aortopulmonary collateral arteries; VACTERL, Vertebral defects/anal atresia/cardiac defects/tracheoesophageal fistula/renal anomalies/limb anomalies; GI, Gastrointestinal

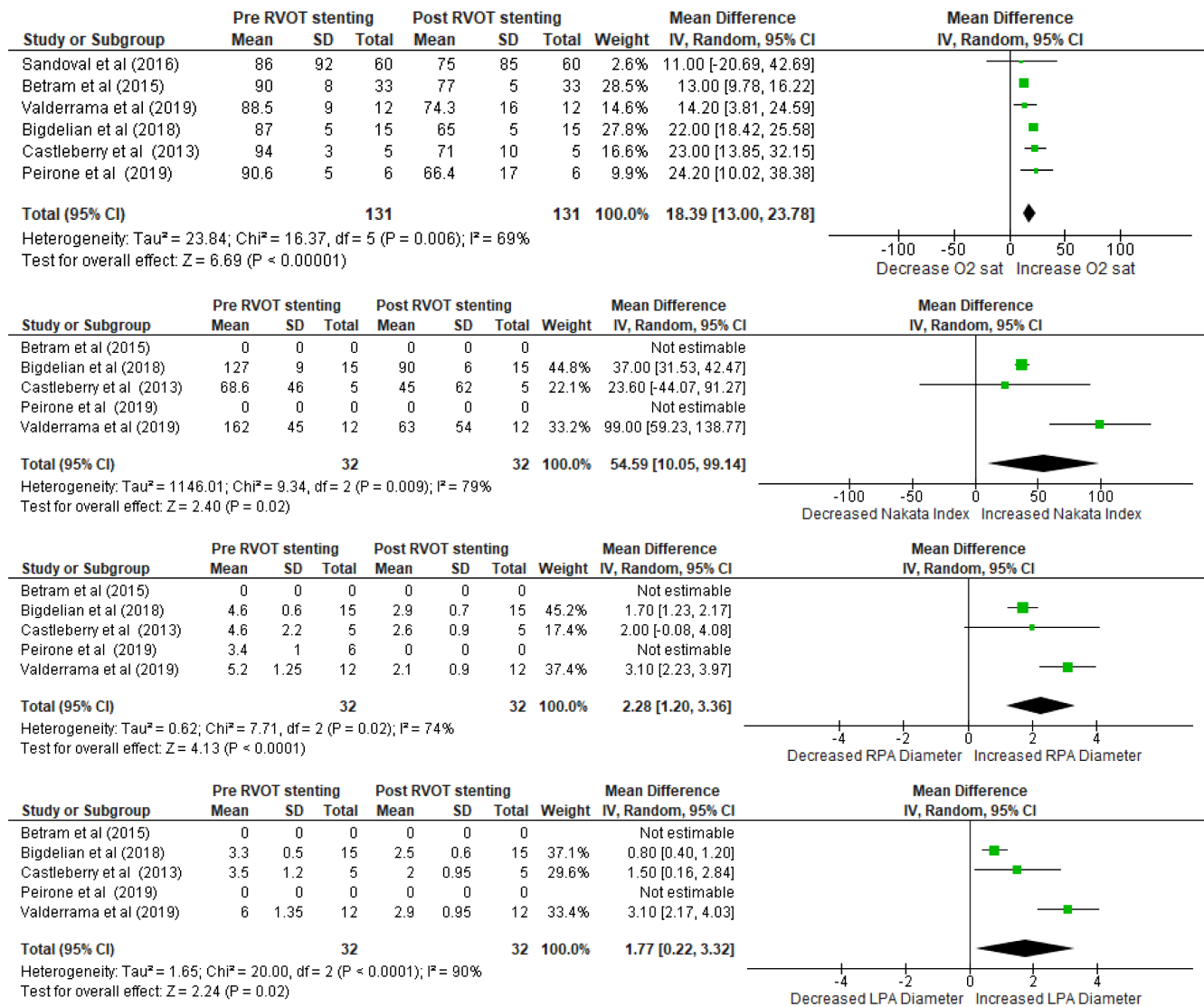


Figure 3. The image depicts the Forest plot of comparison with average value differences. The outcome is comprised of oxygen saturation, the Nakata index, the right pulmonary artery (RPA) diameter, and the left pulmonary artery (LPA) diameter. df, Degree of freedom; RVOT, Right ventricular outflow tract; SD, Standard deviation; CI, Confidence interval; IV, Interval variable; sat, Saturation

and Bertram et al both caused heterogeneity in the pooled analysis of oxygen saturation endpoint data; nevertheless, both studies had larger sample sizes and presented clear criteria for the chosen infants. Moreover, the sensitivity analysis also demonstrated that the article by Valderrama et al contributed to the heterogeneity of the pooled data concerning the PA diameter and the Nakata index. No difference was found regarding the procedure; still, the mean age of infants undergoing RVOT stenting was lower in the article by Valderrama et al than in the other studies, which explains such an accelerated post-stenting increase in the PA diameter during the follow-up. Analytically, it was clear that RVOT stenting conferred progressive improvements in all the variables significantly. The results implied greater

aspects of RVOT therapeutic effects vis-à-vis survivability and readiness of infants to face corrective surgical repair at a later age. The procedural catheterization results are summarized in Table 5.

Complications

Complications were observed after the catheterization process. None of the articles reviewed mentioned the exact time of the occurrence of the complications; nevertheless, most of the studies kept their patient population under observation for 7 days. Peirone et al mentioned a mean time of 108 days for the follow-up period.⁷ Patients with



Table 5. Comparison of RVOT characteristics before and after stenting

Author	Nakata Index (mm ² /m ²)		RPA* Diameter (mm)		LPA* Diameter (mm)		McGoon Ratio		O ₂ Saturation (%)	
	Before	After	Before	After	Before	After	Before	After	Before	After
Castleberry et al (2014)	45 (30-113)	68.6 (28.5- 120)	2.6 (1.8-3.7)	4.6 (3-6.8)	2.0 (1.6-3.5)	3.5 (2.3-5.7)	0.8 (0.71-1.24)	1.4 (1-1.8)	71 (62-2)	94 (91-97)
Bigdelian et al (2015)	90 (84-96)	127 (118-136)	2.9 (2.1-3.5)	4.6 (4-5.2)	2.5 (1.9- 3.1)	3.3 (2.8-3.8)	0.82 (0.79-0.92)	1.4 (1.36-1.44)	65 (64-70)	87 (84-94)
Valderrama et al (2020)	63 (35-143)	162 (107-197)	2.1 (1.8-3.6)	5.2 (4.2-6.7)	2.9 (1.9- 3.8)	6.0 (3.8-6.5)	N/A	N/A	74.3 (55-88)	88.5 (80-98)
Peirone et al (2019)	N/A	N/A	3.4 (2.9-4)	N/A	3 (2-3.8)	N/A	N/A	N/A	66.4 (42-77)	90.6 (86-96)
Bertram et al (2015)	N/A	N/A	N/A	N/A	N/A	N/A	N/A	N/A	77 (68-83)	90 (82-98)
Sandoval et al (2016)	N/A	N/A	N/A	N/A	N/A	N/A	N/A	N/A	75 (60-85)	86 (60-92)

RPA, Right pulmonary artery; LPA, Left pulmonary artery.

*Unit information are enclosed in brackets.

“Numeric results were expressed in terms of median (followed by range).

N/A, not available

cyanotic ToF undergoing palliative treatment to relieve RVOT obstruction might experience post-catheterization complications. Castleberry et al described the emergence of tricuspid regurgitation as a manifestation of flailing anterior leaflets of the valve 7 days following the procedure, for the supporting cords were abutted by the stents. In addition, iliofemoral vein occlusion from a dislodged stent immediately postprocedurally was mainly caused by human failure to predilate the pulmonary valve and to use a shorter sheath. Nevertheless, no death was recorded.³ Studies conducted by Peirone et al reported no significant postprocedural complications, except for frequent premature beats after the intervention requiring antiarrhythmic agents.⁷ The early death of a patient was reported in the article by Bigdelian et al due to acute respiratory distress syndrome after palliation. No marked complications, including shunt failure, postoperative tachyarrhythmia, complete heart block, ventricular failure, and stent fracture, were observed in the studies by Bigdelian et al and Bertram et al.^{11, 15} The article by Valderrama et al showed no detrimental vital state in the studied patients after the procedure, although partial stent migration occurred 24 hours after catheterization.⁴ In contrast, no post-stenting complications were mentioned in the article by Sandoval et al.

Discussion

ToF is the most prevalent cyanotic congenital cardiac anomaly and comprises the ventricular septal defect, RVOT obstruction, the overriding of the ventricular outflow tract by the aortic root, and RV hypertrophy.^{1,2} The manifestation of cyanosis depends on the presence and degree of RVOT obstruction and the development of pulmonary arteries.¹¹ There is still controversy concerning the initial management

of severely cyanotic ToF patients with unfavorable anatomy and significantly reduced pulmonary blood flow.⁷ Although complete primary surgical repair serves as the treatment of choice, it cannot be performed unless weight and anatomical key factors are favorable.⁴ The BTT shunt, as the initial palliative therapy, remains a high-risk surgery as it is associated with an increased risk of shunt failure and elevated early morbidity and mortality in neonates or infants with high-risk conditions such as low or very low birth weight, prematurity, small diameters of pulmonary arteries, complex cardiac anatomy, and noncardiac comorbidities.^{8, 9, 15} The method is also associated with fatal complications such as shunt thrombosis and decreased pulmonary blood flow, elevating the risk of sudden death and morbidity. Furthermore, it is considered to be infeasible to perform shunting in infants with underdeveloped pulmonary arteries with a history of hypercyanotic spells during the neonatal period.¹¹ This situation raises problems in determining the appropriate methods of early interventions for high-risk infants prior to corrective surgery.

Recently, RVOT stenting was introduced as an alternative bridging option to obtain more favorable conditions for high-risk infants born with ToF.^{4,7,11} It is well recognized and has been performed as an alternative to palliative surgical relief of RVOT stenosis in ToF since the 1990s. The stenting of the RVOT is one of the treatment options provided for infants carefully considered for BTT shunts as risks may outweigh its benefits. Furthermore, RVOT stenting is suggested as an initial palliative procedure for infants born with ToF who present with cyanosis, atrioventricular canal defects, small or hypoplastic pulmonary arteries, complex anatomical variants of ToF, and significant comorbidities such as additional congenital heart lesions or other congenital anomalies.^{9,10} It is a treatment of choice for high-risk cyanotic infants with low birth weight, prematurity,

and other noncardiac comorbidities.¹⁵ To obtain insights, in this systematic review, we included articles in the form of observational methodology in evaluating the feasibility and safety of RVOT stenting among heart centers in the world. The samples included infants with RVOT stenting indications, thoroughly described as regard to the severity of the cyanosis, the size of the RPA and the LPA, and other bodily conditions. While the studies reviewed herein reported heterogeneous data with small patient populations, all the results mentioned showed improvements regarding blood flow in the PA for all the studied patients following RVOT stenting. Differences in catheterization methods such as choosing appropriate device size and intervention technique, post-stenting care, and the natural characteristics of patients themselves may explain the varieties of RVOT stenting results.^{3,4,7,11}

All the articles reviewed in the present study showed that RVOT stenting conferred significant feasibility in the management of symptomatic cyanotic ToF. The reported results showed a positive correlation concerning a significant increase in PA size due to dramatic improvements in post-catheterization results concerning increased values of the Nakata index, the RPA diameter, and the LPA diameter.^{3,4,11} The results also demonstrated an improvement in the McGoon ratio in an almost similar manner following the stenting procedure, implying the robust growth of the LPA and the RPA compared with the aortic diameter during the follow-up period.^{3,11} This is because RVOT stenting augments the antegrade pulmonary blood flow, which promotes the efficient supply of the pulmonary blood flow by ensuring the entrance of the systemic venous blood into pulmonary arteries.^{7,16} Therefore, it lessens ventricular volume load, enhances the resultant rise in arterial oxygen saturation per unit of volume load, and ameliorates hemodynamic conditions.^{11,16} The improvement of the circulation of pulmonary arteries allows cyanosis stabilization, which explains why the comparison of the O₂ saturation level before and after stenting showed a significant difference concerning enhanced systemic blood oxygenation in infants.¹¹ Hence, RVOT stenting prepares the high-risk subgroup with better clinical conditions, permitting them to undergo a less risky surgical procedure despite their original risk factors.⁴

For all its desirable outcomes, RVOT stenting comes with some potential threats. In general, the reviewed studies agreed that RVOT stenting was still a technically challenging procedure with considerable risks of complications and procedural failure. The reports of tricuspid valve regurgitation as an adverse outcome days after the procedure were mainly due to procedural failure in terms of the inability to obtain an appropriate wire position, leading to stent dislodgement and stent malposition.^{3,4} Stents extended too far into the RV body and inlet may provoke progressive tricuspid valve injury and regurgitation. Therefore, optimal

placement is crucial to secure an appropriate position in the RVOT and across the pulmonary valve. However, some instances of tricuspid valve regurgitation were not directly caused by RVOT stenting. In the article by Paulo et al, tricuspid valve regurgitation occurred after surgical stent removal during corrective surgery. It may be precipitated by subvalvular tricuspid apparatus alteration as a result of injury during surgical RVOT stent removal.^{4,17}

Another complication is distal stent migration with or without iliofemoral vein occlusion. The latter case results from the inability to cross the pulmonary valve with a pre-mounted stent due to failure to predilate the pulmonary valve or utilize a longer sheath. Thus, the stent might dislodge during retraction into the sheath. Furthermore, the iliofemoral vein could be damaged with a subsequent femoral venous occlusion during an attempt to remove the migrated stent.^{3,4} The adequate selection of the stent length is emphasized in order to reduce adverse outcomes during RVOT stenting.^{3,4,7,16} Selected implanted stents must follow the guidance of the underlying anatomy and the measurement from angiography and echocardiography. The stent length was recommended to be ample and exceed the measured length due to the possibility of foreshortening in standard angiographic projections. Guidewire usage with distance markers is beneficial in the verification of angiographic length measurements.¹⁶ Stent dislodgement can be managed by the use of a longer sheath, which improves the stability across the RVOT and allows appropriate positioning.³

Some clinical issues were noted after the intervention, namely frequent ventricular premature beat and convulsion.⁷ Infants who developed convulsion shared similar traits such as low body weight and cyanotic spells with severe hypoxemia requiring mechanical ventilation and prostaglandin infusions. The severity of the clinical presentation of the infants was mainly associated with their functional neurological disorder.⁷ Nevertheless, these complications exhibited a lack of association with post-RVOT stenting conditions.

Findings related to immediate death during early postoperative monitoring were suspected to be a consequence of acute respiratory distress syndrome (ARDS). There was a dearth of information explaining the possible etiologies of ARDS after RVOT stenting in infants.¹¹ However, recent updates clarify that ARDS may occur as a simultaneous event during sepsis in infants, especially after some invasive procedures. Apropos of definition, ARDS is a group of clinical symptoms characterized by the increased permeability of the blood-air barrier in pulmonary capillaries. It begins with capillary endothelial damage and sequential inflammatory cascades, followed by plasma leakage into alveoli or interstitial tissues. Systemic inflammation due to sepsis triggers widespread endothelial damage, including pulmonary vasculatures.¹⁸



The manifestation of ARDS can be explained by lung injury after cardiopulmonary bypass, which may be associated with the ischemia-reperfusion mechanism, leading to reperfusion pulmonary edema. This association may have significant clinical implications for infants who undergo congenital heart surgeries. The result of capillary leakage and the development of hydrostatic pulmonary edema is over perfusion within previously restricted vascular beds. Narrow pulmonary arteries lead to reduced blood flow and pressure inside pulmonary microvasculature. Corrective surgery increases blood flow through previously stenotic vessels and raises blood pressure. Hydrostatic pulmonary edema develops when microvasculature is not able to immediately restrict the flow as a response to the increment after surgery.¹⁹ Considering that pediatric patients indicated for palliative stenting predominantly have high-risk presentations, sepsis may happen immediately after the procedure.¹⁸ Alternatively, pediatric patients undergoing the placement of RVOT stents could experience ARDS from the wide inflammation of pulmonary vasculatures, called “postperfusion lung syndrome.” It is, albeit rare, considered a lethal complication. This group of clinical symptoms exhibit similar characteristics to sepsis-induced ARDS; nonetheless, they happen mainly because of a sudden uncontrollable increase in the pulmonary blood flow after the dilation of the obstructed RVOT. High blood flow damages the endothelial lining of capillaries and induces the formation of reactive species, thus initiating cascades of inflammation and worsening the prognosis of postoperative cyanotic infants.²⁰ Therefore, sepsis and postperfusion lung syndrome are 2 possible etiologies of ARDS that should be anticipated as the worst complications following RVOT stenting.

The present study has several limitations. Firstly, different catheterization centers may implement distinguished catheterization techniques, devices, or details, which could result in different patient outcomes. Secondly, only a few studies discussed the real case situation of RVOT stenting in the articles (Figure 4), which may have resulted in bias in the review due to inadequate evidence. Lastly, diverse comorbid conditions of high-risk infants indicated for stenting might affect survivability rates or complications during the follow-up in a study. Some episodes of RVOT stenting result in complications; still, such adverse outcomes are considered rare compared with the successful performance. An understanding of the possible problems assists clinicians in taking preventive measures on risk management that will reduce adverse events and improve the safety of RVOT stenting.

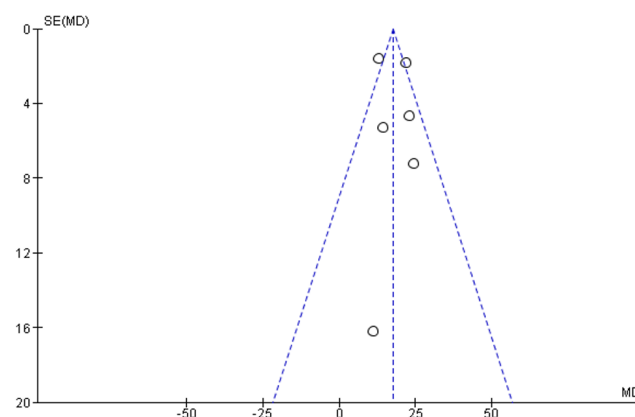


Figure 4. The image presents the Funnel plot distribution of 6 articles based on the commonest variable of analysis. The horizontal axis indicates study results, the vertical axis indicates study precision (in the form of standard error reporting), the funnel axis indicates the overall effect, and the hypotenuse line indicates the 95% confidence interval. The studies (point) from top to bottom consecutively are by Bertram et al (2015), Bigdelian et al (2018), Castleberry et al (2013), Valderrama et al (2019), Peirone et al (2019), and Sandoval et al (2016).

SE, Standard error; MD, Mean difference

Conclusion

Right ventricular outflow tract stenting is deemed a feasible palliative treatment for tetralogy of Fallot, with its high effectiveness in improving patients' condition, especially their pulmonary flow. While complications are scarce, several conditions should be noted, in particular fatal complications in several cases. More studies should be conducted to improve the safety of right ventricular outflow tract in the treatment of children with tetralogy of Fallot.

Acknowledgments

The authors would especially like to thank the Division of Pediatric Cardiology and Congenital Heart Diseases in National Cardiovascular Center Harapan Kita for providing extensive personal and professional guidance and teaching the authors a great deal about scientific research in cardiovascular medicine.

References

1. Bailliard F, Anderson RH. Tetralogy of Fallot. *Orphanet J Rare Dis* 2009;4:2.
2. Antonová P, Zatočil T, Žáková D, Rohn V. Fallotova tetralogie. *Interv Akut Kardiol* 2019;18:11-14.
3. Castleberry CD, Gudausky TM, Berger S, Tweddell JS, Pelech AN. Stenting of the right ventricular outflow tract in the high-risk infant with cyanotic tetralogy of Fallot. *Pediatr Cardiol*

- 2014;35:423-430.
4. Valderrama P, Garay F, Springmüller D, Briones Y, Aguirre D, González R, Becker P, Zamora G, Sánchez L, Castillo G, Palominos G, Cárdenas L. Initial experience in Chile with stent implantation in the right ventricle outflow tract in high-risk patients with tetralogy of Fallot. *Pediatr Cardiol* 2020;41:837-842.
 5. Bugeja J, Grech V, DeGiovanni JV. Right ventricular outflow tract stenting - effective palliation for Fallot's tetralogy. *Images Paediatr Cardiol* 2015;17:3-10.
 6. Barron DJ, Ramchandani B, Murala J, Stumper O, De Giovanni JV, Jones TJ, Stickley J, Brawn WJ. Surgery following primary right ventricular outflow tract stenting for Fallot's tetralogy and variants: rehabilitation of small pulmonary arteries. *Eur J Cardiothorac Surg* 2013;44:656-662.
 7. Peirone A, Contreras A, Guadagnoli AF, Francucci V, Juaneda I, Cabrera M. Right ventricular outflow tract stenting in severe tetralogy of Fallot: an option to the Blalock-Taussig shunt. *Rev Argent Cardiol* 2019;87:125-130.
 8. Sasikumar N, Hermuzi A, Fan CS, Lee KJ, Chaturvedi R, Hickey E, Honjo O, Van Arsdell GS, Caldarone CA, Agarwal A, Benson L. Outcomes of Blalock-Taussig shunts in current era: a single center experience. *Congenit Heart Dis* 2017;12:808-814.
 9. Lee J, Sivalingam S, Alwi M. Stenting of right ventricular outflow tract in tetralogy of Fallot with subarterial ventricular septal defect: A word of caution. *Ann Pediatr Cardiol* 2017;10:281-283.
 10. Quandt D, Penford G, Ramchandani B, Bhole V, Mehta C, Stumper O. Stenting of the right ventricular outflow tract as primary palliation for Fallot-type lesions. *J Congenit Heart Dis* 2017;1:1-6.
 11. Bigdelian H, Ghaderian M, Sedighi M. Surgical repair of Tetralogy of Fallot following primary palliation: right ventricular outflow track stenting versus modified Blalock-Taussig shunt. *Indian Heart J* 2018;70(Suppl 3):S394-S398.
 12. Page MJ, McKenzie JE, Bossuyt PM, Boutron I, Hoffmann TC, Mulrow CD, Shamseer L, Tetzlaff JM, Akl EA, Brennan SE, Chou R, Glanville J, Grimshaw JM, Hróbjartsson A, Lalu MM, Li T, Loder EW, Mayo-Wilson E, McDonald S, McGuinness LA, Stewart LA, Thomas J, Tricco AC, Welch VA, Whiting P, Moher D. The PRISMA 2020 statement: an updated guideline for reporting systematic reviews. *BMJ* 2021;372:n71.
 13. Wells GA, Shea B, O'Connell D, Peterson J, Welch V, Losos M, Tugwell P. The Newcastle-Ottawa Scale (NOS) for assessing the quality of nonrandomised studies in meta-analyses. *Ottawa Hosp Res Institute* 2014;3:2-4.
 14. Bertram H, Emmel M, Ewert P, Grohmann J, Haas NA, Jux C, Kehl HG, Kitzmüller E, Kretschmar O, Müller G, Wiebe W; Investigators of The Working Group Interventional Cardiology of The German Society of Pediatric Cardiology. Stenting of native right ventricular outflow tract obstructions in symptomatic infants. *J Interv Cardiol* 2015;28:279-287.
 15. Sandoval JP, Chaturvedi RR, Benson L, Morgan G, Van Arsdell G, Honjo O, Caldarone C, Lee KJ. Right ventricular outflow tract stenting in tetralogy of Fallot infants with risk factors for early primary repair. *Circ Cardiovasc Interv* 2016;9:e003979.
 16. Stumper O, Ramchandani B, Noonan P, Mehta C, Bhole V, Reinhardt Z, Dhillon R, Miller PA, de Giovanni JV. Stenting of the right ventricular outflow tract. *Heart* 2013;99:1603-1608.
 17. McGovern E, Morgan CT, Oslizlok P, Kenny D, Walsh KP, McMahon CJ. Transcatheter stenting of the right ventricular outflow tract augments pulmonary arterial growth in symptomatic infants with right ventricular outflow tract obstruction and hypercyanotic spells. *Cardiol Young* 2016;26:1260-1265.
 18. Kim WY, Hong SB. Sepsis and acute respiratory distress syndrome: recent update. *Tuberc Respir Dis (Seoul)* 2016;79:53-57.
 19. Yuan SM. Postperfusion lung syndrome and related sequelae. *J Thorac Dis* 2016;8:E340-344.
 20. Asija R, Roth SJ, Hanley FL, Peng L, Liu K, Abbott J, Zhuo H, Matthay M. Reperfusion pulmonary edema in children with tetralogy of Fallot, pulmonary atresia, and major aortopulmonary collateral arteries undergoing unifocalization procedures: a pilot study examining potential pathophysiologic mechanisms and clinical significance. *J Thorac Cardiovasc Surg* 2014;148:1560-1565.