



# Successful Endovascular Rescue Using the Brockenbrough Needle Following Inadvertent Stent-Graft Deployment in the False Lumen

Pavan Rasalkar, MD, DM<sup>1</sup>, Krishna Santosh Vemuri, MD, DM<sup>2</sup>, Dinakar Bootla, MD, DM<sup>1</sup>, Pruthvi C Revaiah, MD, DM<sup>1</sup>, Anand Kumar Mishra, MS, Mch<sup>3</sup>, Neelam Dahiya, MD, DM<sup>1</sup>, Soumitra Ghosh, MD<sup>1</sup>, Parag Barwad, MD, DM, FESC, FSCAI\*

<sup>1</sup>Department of Cardiology, Postgraduate Institute of Medical Education and Research, Chandigarh, India.

<sup>2</sup>Departement of Cardiology, Institute of Medical Sciences, Banaras Hindu University, Varanasi, Uttar Pradesh, India.

<sup>3</sup>Department of Cardiothoracic Surgery, Postgraduate Institute of Medical Education and Research, Chandigarh, India.

Received 27 May 2021; Accepted 05 June 2022

## Abstract

Inadvertent deployment of stent grafts into the false lumen during thoracic endovascular aortic repair (TEVAR) is rare and is associated with catastrophic consequences. We present a case of accidental stent-graft deployment from the true lumen into the false lumen during TEVAR, resulting in hemodynamic collapse and visceral malperfusion. We successfully performed a bailout using the Brockenbrough needle to create new access from the true lumen to the false lumen and implanted another overlapping stent graft.

*J Teh Univ Heart Ctr* 2022;17(3):147-151

**This paper should be cited as:** Rasalkar P, Vemuri KS, Bootla D, Revaiah PC, Mishra AK, Dahiya N, et al. Successful Endovascular Rescue Using the Brockenbrough Needle Following Inadvertent Stent-Graft Deployment in the False Lumen. *J Teh Univ Heart Ctr* 2022;17(3):147-151.

**Keywords:** Thoracic endovascular aortic repair (TEVAR); False lumen implantation; Brockenbrough needle; Endovascular rescue

## Introduction

Thoracic endovascular aortic repair (TEVAR) is now considered the first-line treatment to manage Type B aortic dissection and abdominal aortic aneurysms. It is associated with lower perioperative mortality and morbidity than open surgery.<sup>1,2</sup> However, the main disadvantage of TEVAR is the requirement for reintervention.<sup>3</sup> One of the most dreaded

and catastrophic complications of TEVAR, especially in patients with Type B aortic dissection, is the implantation of the endovascular graft into the false lumen. We report a case in which the endovascular graft was erroneously deployed from the true lumen into the false lumen, resulting in distal hemodynamic collapse due to the obliteration of the true lumen. An emergency bailout was performed using the Brockenbrough needle to create fenestration between the

\*Corresponding Author: Parag Barwad, Associate Professor of Cardiology, Advanced Cardiac Center, Postgraduate Institute of Medical Education and Research, Chandigarh, India, 160012. Tel: +91 8968732470. E-mail: paragaims@gmail.com.



true lumen and the false lumen, followed by the deployment of another stent graft to allow the blood to flow from the false lumen into the true lumen.

## Case Report

Our patient was a 55-year-old hypertensive, nondiabetic, nonsmoking, and nonalcoholic man who was a known case of polycystic kidney disease (serum creatinine =2.6 mg/dL). The patient presented with symptoms of retrosternal chest pain radiating to the back intermittently for the preceding 6 months. His symptoms were unresponsive to medical therapy and gradually increased in severity, for which he sought medical care.

The patient's vital signs at admission were blood pressure of 180/100 mm Hg and heart rate of 96 bpm. He had a history of poorly controlled blood pressure for the last 6 months despite being on 3 antihypertensive drugs in adequate dosages. His electrocardiogram showed normal sinus rhythm with no dynamic changes, and his cardiac biomarkers were negative. Echocardiography showed left ventricular hypertrophy and an aortic dissection flap in the descending aorta. A contrast-enhanced computed tomography (CT) scan of the aorta and its branches showed a Stanford Type B dissection of the aorta, with the entry point

at 25 mm distal to the left subclavian artery (Figure 1A & Figure 1B), extending distally up to the aortoiliac bifurcation but not involving the iliac arteries. No evidence of a distal re-entry tear for dissection was detected, and the false lumen was aneurysmally dilated with a maximum dimension of 60 mm. Among the visceral arteries, the celiac artery originated from the false lumen (Figure 1C), whereas the superior mesenteric artery, the inferior mesenteric artery, and both renal arteries originated from the true lumen (Figure 1D and Figure 1E). The diameter of the aortic arch proximal to the dissection was 33 mm, and the flap had entered the left subclavian artery.

After a heart team approach, the endovascular repair procedure was selected as the patient also suffered from chronic kidney disease with a serum creatinine level of 2.6 mg/dL. Hypertension was managed with intravenous nitroprusside and oral drugs, and heart rate was controlled prior to TEVAR.

The procedure was done under general anesthesia with hemodynamic monitoring and systemic heparinization. The size of the left common iliac artery was larger than that of the right common iliac artery, and the left femoral artery was chosen for intervention via surgical exposure. The right femoral artery and right brachial artery access points were used to obtain angiograms by using 6F pigtail catheters. The aortograms confirmed the CT scan findings. A 0.035-

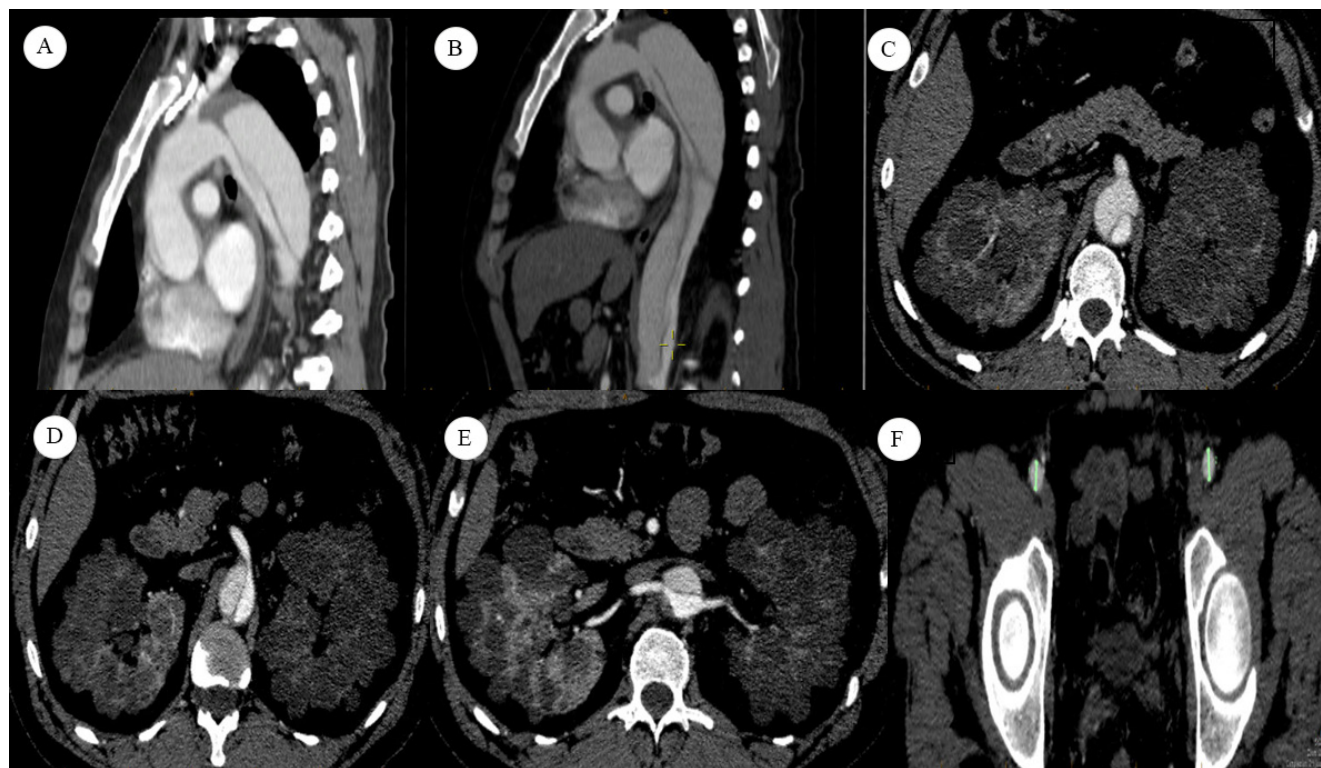


Figure 1. A & B) The preoperative computed tomography (CT) angiograms are presented herein. The preoperative CT angiogram shows a Type B aortic dissection with the entry tear close to the left subclavian artery, C) With the significant compression of the true lumen. The celiac artery originates from the false lumen, D) The superior mesenteric artery originates from the true lumen, E) Both renal arteries originate from the true lumen. F) The right common femoral artery is 7.8 mm in diameter, and the left common femoral artery is 8.4 mm in diameter.

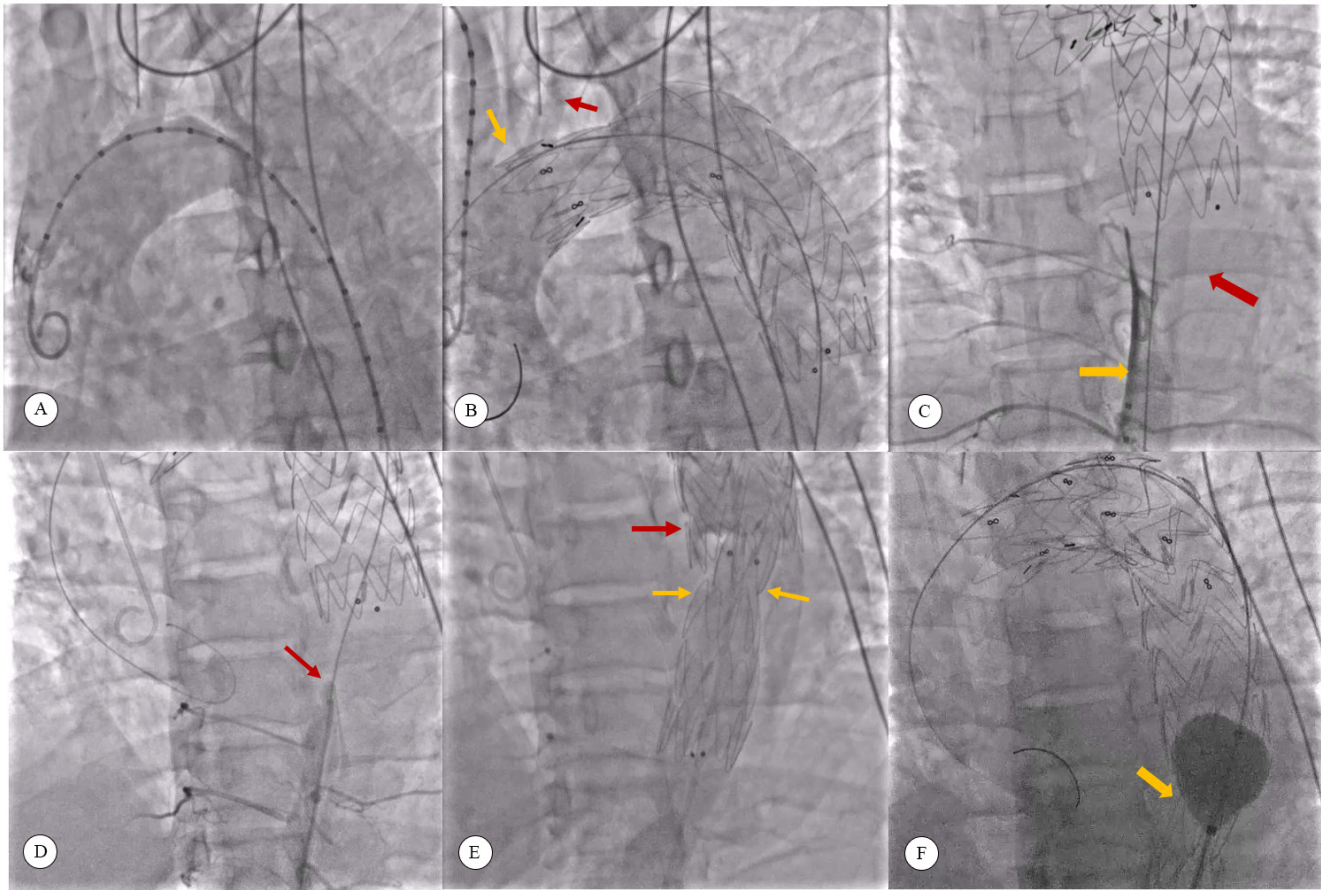


Figure 2. The images present the angiographically guided thoracic endovascular aortic repair. A) The aortic angiogram using a marked pigtail shows an aneurysmal false lumen, with the dissection entry point close to the left subclavian artery. B) A 34/38×150 mm Valiant Captivia (Medtronic Inc, Minneapolis, Minn) is deployed distal to the left common carotid artery (the orange arrow), but it covers the left subclavian artery (the red arrow) using access from the left femoral artery. C) The pigtail cannot be negotiated into the stent graft from the right femoral artery (the orange arrow). The angiogram shows opacification of the intercostal arteries but not the stent graft (the red arrow), confirming false lumen implantation of the stent graft. D) The septum between the true and false lumina is penetrated with a Brockenbrough needle, followed by the passage of a 0.035-inch wire using a Judkins Right catheter from the true lumen to the stent graft in the false lumen. E) Another stent graft is deployed from the true lumen (the orange arrow) to the false lumen (the red arrow), F) Followed by the dilatation of the stent graft with a 24 mm TYSHAK (Numed) peripheral balloon (the orange arrow).

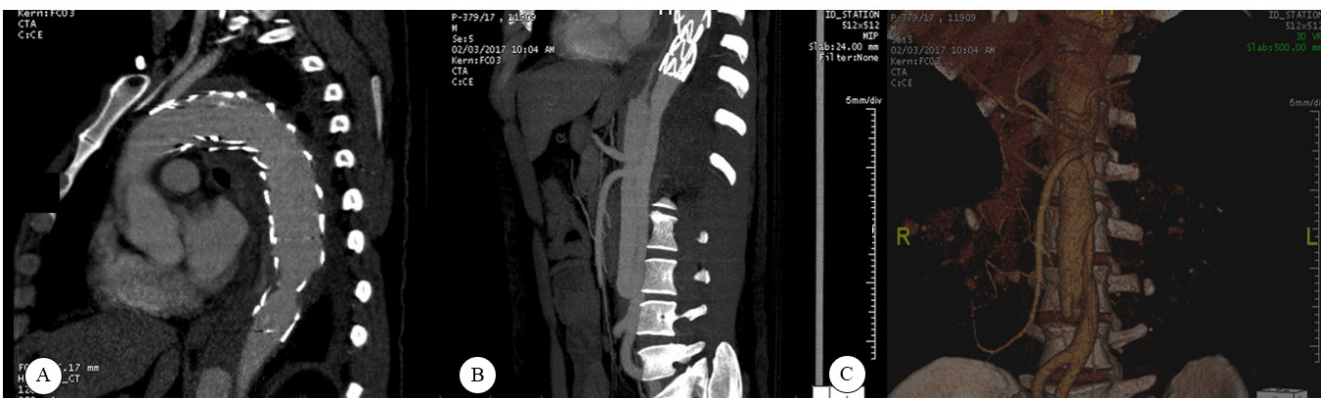


Figure 3. The images depict the follow-up computed tomography (CT) angiography. A & B) The CT angiogram shows a patent true lumen with no significant endoleak. B) The origin of the celiac and superior mesenteric arteries is from the true lumen. C) The image presents a 3D reconstruction.

inch Lunderquist extra-stiff guidewire (Cook Medical Inc, Bloomington, Ind) was placed in the ascending aorta. With the use of a 26F sheath through the left femoral artery, a 34/38×150 mm stent graft (Valiant Captivia, Medtronic Inc,

Minneapolis, Minn) was deployed distal to the left common carotid artery, covering the origin of the left subclavian artery using arch aortography (Figure 2B). However, just after the deployment of the stent graft, the systolic blood pressure of



the lower limbs dropped suddenly to 30 mm Hg with a non-pulsatile flow, whereas the systolic blood pressure of the upper limbs was 150 mm Hg. We thought that the stent graft had been deployed from the true lumen into the false lumen, causing the compression of the true lumen distally. We were not able to negotiate the guidewire or the pigtail from right femoral artery access into the stent-graft lumen to confirm the placement of the distal end of the graft in the false lumen (Figure 2C). A check angiogram from the brachial artery pigtail was done, and it showed no flow distal to the stent graft into the true lumen, confirming the obliteration of the true lumen. Intravascular imaging was not used in view of borderline hemodynamics and diagnosis being evident on aortograms.

The most plausible explanation for this catastrophic event could be that the guidewire traversed from the true lumen to the false lumen through an unrecognized distal tear of the dissection and reentered the true lumen through the proximal dissection entry tear. An emergency surgical consultation was done for open surgical repair; nonetheless, given the patient's worsening hemodynamics and compromise of the visceral arterial supply and the bilateral renal arteries, the percutaneous approach was chosen as a bailout.

Via the left femoral artery, a 10F Fast Cath™ (St Jude Medical) introducer with a Brockenbrough needle was placed into the suprarenal aorta just below the endovascular graft. The dissection flap was punctured from the true lumen to enter the false lumen and the distal end of the graft. The needle was removed, and a 0.035-inch guidewire was introduced all the way to the ascending aorta (Figure 2D). The course of this current guidewire was from the true lumen (distal to the stent graft) to the false lumen (within the stent graft) and then into the true lumen (proximal to the stent graft) (Figure 2D). Balloon dilation at the site of fenestration was performed with a 12×40 mm peripheral angioplasty balloon (Bard Co, Karlsruhe, Germany).

Following balloon angioplasty, the systolic blood pressure of the lower limbs rose to 110 mm Hg. Before the second stent-graft deployment, lumen tracking was performed to ensure that the stent graft was deployed across the dissection flap from the true lumen to the false lumen and into the proximal graft. In this technique, a guiding Judkins Right (JR 4, Medtronic Launcher 6F) was advanced over the present guidewire, and the course of this wire on which further stent deployment was planned was doubly confirmed by giving repeated contrast injections and delineating the entire course of this guidewire. After the confirmation of the course of the wire, the guidewire was exchanged with a Lunderquist guidewire. Another 32/34×200 mm stent graft (Valiant Captivia, Medtronic Inc, Minneapolis, Minn) was deployed from the proximal end of the previous stent to 5 cm distal to the previous stent graft. The distal end of this second stent was in the true lumen (Figure 2E). The overlapping stent zone and the distal portion of the second stent graft

that crossed the fenestration and entered the true lumen were postdilated with a 33 mm equalizer balloon (Boston Scientific, Marlborough, Massachusetts, US) (Figure 1F). Following the deployment of the stent graft, the lower limb pressure normalized, approaching that of the upper limb pressure. Repeat aortography showed flow preservation in the arch vessels and patent stent grafts with the blood flow successfully drawn back from the false lumen to the true lumen (the homing technique) with good distal perfusion of the renal and inferior mesenteric arteries and the bilateral iliac arteries.

The overall procedure time was 155 minutes, and the fluoroscopic time was 33 minutes, with an estimated blood loss of 250 mL. The surgical repair of arterial access was done. The patient was extubated later, with no evidence of neurological deficits. He was discharged 1 week after the procedure. The postoperative course was uneventful. Repeat CT angiography after 3 months showed patent and well apposed stent grafts with complete obliteration of the false lumen and no evidence of endoleak (Figure 3). He has been hemodynamically stable and under regular follow-ups for the last 3 years.

## Discussion

The management of patients with thoracic and abdominal aortic dissection and aneurysms encompasses both surgical and endovascular repair procedures. Recent years have seen a rise in the use of TEVAR to manage this group of patients, such that it is currently the preferred modality as it decreases perioperative mortality and morbidity.<sup>2,3</sup>

Inadvertent deployment of the stent graft into the false lumen during TEVAR is rare and is associated with dire consequences due to either rupture of the vessel wall or the compromise of the true lumen and visceral vessels. In our case, stent-graft deployment was followed by a sudden fall in lower limb blood pressure due to the obliteration of the true lumen. The emergency management of such events is necessary to establish the distal flow in the true lumen by creating urgent artificial fenestration of the aorta distal to the stent graft. It can be done via both surgical and endovascular approaches. Emergency surgical management of these patients is challenging and is associated with increased mortality and morbidity. Only a few such cases have been reported thus far.<sup>4,5</sup>

The literature contains only 2 cases of percutaneous rescue.<sup>6,7</sup> Xiang Ma et al<sup>6</sup> performed reentry from the true lumen to the false lumen using an Outback LTD reentry catheter (Cordis, Johnson & Johnson Co, Bridgewater, NJ). They, too, performed fenestration in their third attempt 3 weeks after the index procedure. Han et al<sup>7</sup> reported a similar case to ours insofar as the stent-graft deployment in the false lumen resulted in the compression of the true lumen, and the



patient presented with symptoms a day after the procedure. In their case, Han and colleagues managed to cannulate both true and false lumina and perform reentry from the true lumen to the false lumen via snaring. Our patient's true lumen was obliterated, which was recognized on the catheterization table.

We did not have a dedicated catheter for reentry from the true lumen to the false lumen. At that moment, we could only think of puncturing the dissection flap with the Brockenbrough needle. While considering the blind puncture of this type dangerous, we took every precaution so as not to perforate the aorta during our attempt to enter the distal part of the stent. This complication could have been prevented with the use of transesophageal echocardiography or intravascular ultrasound (IVUS) imaging to detect true and false lumina. IVUS may also assist in reducing the contrast volume, selecting the optimal size for the dilated aorta, and selecting the landing zone.<sup>8</sup>

To our knowledge, this case was the first of its kind where an emergency intraprocedural bailout of true lumen compression was performed using the Brockenbrough needle, thereby avoiding emergent surgery and its attendant risks.

## Conclusion

Inadvertent deployment of the endovascular graft into the false lumen, albeit rarely encountered, is associated with catastrophic complications unless addressed urgently. There are very few case reports regarding this complication.

## References

1. Lee WA, Matsumura JS, Mitchell RS, Farber MA, Greenberg RK, Azizzadeh A, Murad MH, Fairman RM. Endovascular repair of traumatic thoracic aortic injury: clinical practice guidelines of the Society for Vascular Surgery. *J Vasc Surg* 2011;53:187-192.
2. Karthikesalingam A, Holt PJ, Hinchliffe RJ, Nordon IM, Loftus IM, Thompson MM. Risk of reintervention after endovascular aortic aneurysm repair. *Br J Surg* 2010;97:657-663.
3. Hiratzka LF, Bakris GL, Beckman JA, Bersin RM, Carr VF, Casey DE Jr, Eagle KA, Hermann LK, Isselbacher EM, Kazerooni EA, Kouchoukos NT, Lytle BW, Milewicz DM, Reich DL, Sen S, Shinn JA, Svensson LG, Williams DM; American College of Cardiology Foundation/American Heart Association Task Force on Practice Guidelines; American Association for Thoracic Surgery; American College of Radiology; American Stroke Association; Society of Cardiovascular Anesthesiologists; Society for Cardiovascular Angiography and Interventions; Society of Interventional Radiology; Society of Thoracic Surgeons; Society for Vascular Medicine. 2010 ACCF/AHA/AATS/ACR/ASA/SCA/SCAI/SIR/STS/SVM guidelines for the diagnosis and management of patients with Thoracic Aortic Disease: a report of the American College of Cardiology Foundation/American Heart Association Task Force on Practice Guidelines, American Association for Thoracic Surgery, American College of Radiology, American Stroke Association, Society of Cardiovascular
4. Follis F, Filippone G, Stabile A, Montalbano G, Floriano M, Finazzo M, Follis M. Endovascular graft deployment in the false lumen of type B dissection. *Interact Cardiovasc Thorac Surg* 2010;10:597-599.
5. Watanabe Y, Kuratani T, Shirakawa Y, Torikai K, Shimamura K, Sawa Y. Hybrid endovascular repair of a dissecting thoracoabdominal aortic aneurysm with stent graft implantation through the false lumen. *J Vasc Surg* 2014;59:264-267.
6. Ma X, Fu W, Ma YT, Karmacharya U, Zhao J. Successful endoluminal rescue of an endovascular graft unintentionally deployed in the false lumen of Stanford type B aortic dissection. *J Thorac Cardiovasc Surg* 2016;151:e41-e45.
7. Han SM, Gasper WJ, Chuter TA. Endovascular rescue after inadvertent false lumen stent graft implantation. *J Vasc Surg* 2016;63:518-522.
8. Garret HE, Jr, Abdullah AH, Hodgkiss TD, Burgar SR. Intravascular ultrasound aids in the performance of endovascular repair of abdominal aortic aneurysm. *J Vasc Surg* 2003;37:615-618.