

A Patient with Repeated Carotid Stent Thrombosis

Introduction

Carotid artery stenting (CAS) is a suitable choice for resolving carotid artery stenosis and can be used in lieu of carotid endarterectomy in carefully selected patients.¹ CAS is less invasive than carotid endarterectomy, and its use is on the increase.^{2,3} Carotid stent thrombosis (CST) is a rare, albeit life-threatening, complication of CAS,^{4,5} with an incidence rate higher than that of carotid endarterectomy complications.⁶ Based on the time of intervention, CST can be classified into 4 categories: early acute stent thrombosis, which happens in the first 24 hours; early subacute stent thrombosis, which occurs after 24 hours and in the first 30 days; late stent thrombosis, which happens after 30 days; and very late stent thrombosis, which can occur after 1 year.⁴

The risk factors for early stent thrombosis are classified into 2 groups. The first group encompasses patient-related factors, including resistance to antiplatelet medications, noncompliance, long-lesion development in the artery, emergent procedures, and hypercoagulable states (eg, uncontrolled diabetes mellitus and malignancies).⁷⁻¹⁰ The second group involves technical risk factors, including dual-layer stent use, multiple stent use, and bailout procedures.⁷

Early diagnosis and prompt revascularization are essential since they can reduce neurological damage in patients as much as possible. CST can be treated via several strategies: surgery, stenting, thromboaspiration, thrombectomy, and thrombolytic therapy.⁴ In this article, we present a case of repeated early stent thrombosis in an endovascular approach.

Case Report

A 72-year-old woman presented to our center with a decreased consciousness level and in a stupor status. The patient had a history of an elective left internal carotid artery (LICA) stenting procedure for a transient ischemic attack (TIA) 72 hours earlier with a 7×40 mm carotid stent. She had a history of diabetes mellitus, hypertension, and ischemic heart disease but no history of previous coronary stenting. Her drug history included the consumption of aspirin, clopidogrel, statins, amlodipine, valsartan, and

antidiabetics. The patient resided in a rural area and had undergone the carotid stenting procedure in a large city far from her residence.

Forty-eight hours after discharge from the first center, the patient suffered a sudden fall in her consciousness level at home. On physical examination in our center, the patient was in a stupor state and had right hemiplegia (1/5–2/5). Given her history and symptoms, a brain computed tomography (CT) scan without contrast was performed, and the findings ruled out a hemorrhagic stroke. Afterward, Doppler sonography on the carotid arteries revealed a totally occluded LICA on the site of the recent stenting. Due to the patient's unstable status and her considerable distance from the nearest hospital in the neighboring province, she became a candidate for emergent LICA catheterization in our center. Pre and intraprocedurally, a neuro-interventionalist was consulted by phone. In less than 2 hours, the patient was transferred to the catheterization laboratory.

The first angiography view confirmed CST and demonstrated a total cut off in the LICA (Figure 1). Unfractionated heparin (5000 units) was injected preprocedurally. Proximal protection was not available. The carotid artery was wired through the thrombosis with a 0.014-inch BMW wire, and thrombosuction was performed repeatedly throughout the occluded artery. Alteplase (30 mg) was injected into the site of the CST, and the blood flow became normal. In this phase, CST reoccurred unexpectedly (Figure 2), requiring thrombosuction for a second time at the occlusion site. In addition, carotid filtering for distal protection was performed. A second carotid stenting procedure was done with an 8×6 mm Xact Carotid Stent because an edge dissection in the distal part of the stent or stent malposition was considered the differential diagnosis (Figure 3). Subsequently, the occurrence of an iatrogenic edge dissection (Figure 4) at the distal border of the second stent necessitated LICA stenting at the overlapping site of the 2 previous stents with a 4×12 mm XIENCE Alpine Coronary Stent (the only stent available to us at the time) (Figure 5). Postdilation was done with a 4.5×12 mm noncompliant TREK Balloon. The last angiography view demonstrated the patency of the LICA flow. Additionally, the M1 and M3 branches of the middle cerebral artery (MCA) were normal, while the M2 branch was occluded (Figure 6).

Following the procedure, the patient was transferred to the intensive care unit (ICU), where she received intravenous nitroglycerin to prevent reperfusion-induced brain edema, and her systolic blood pressure was maintained between 120 mmHg and 130 mmHg. A control brain CT scan, performed 48 hours after the procedure, revealed a massive infarction in the MCA area.

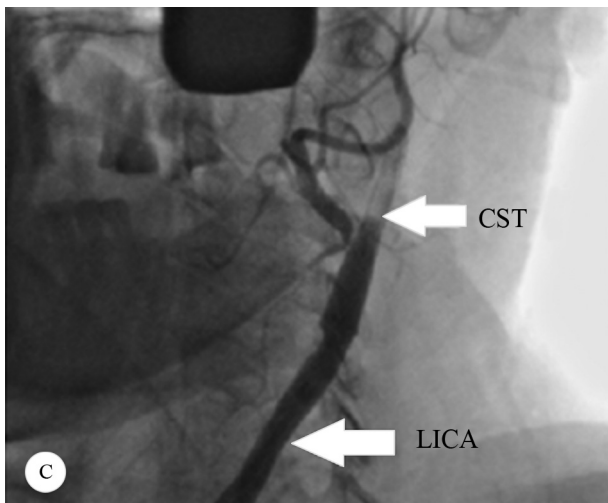
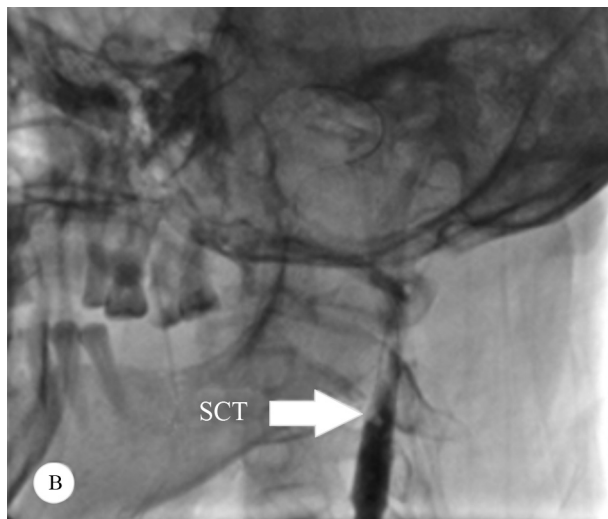
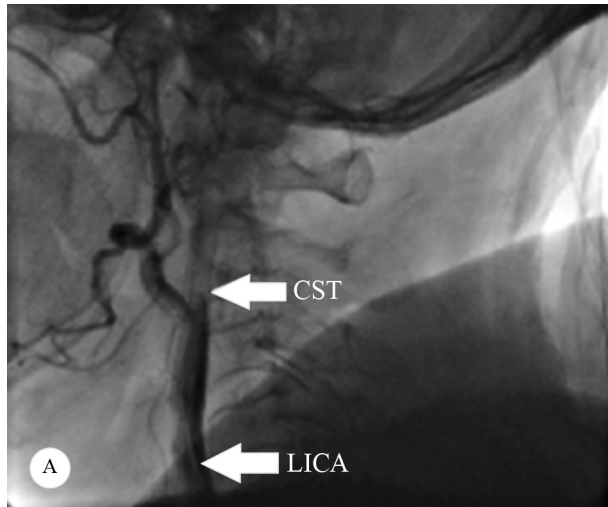


Figure 1. A, B & C) The images illustrate the lateral angiographic view of the LICA on the patient's admission to our center. The first CST can be seen with a total cut off in the mid-part of the LICA (sub-acute CST). LICA, Left internal carotid artery; CST, Carotid stent thrombosis

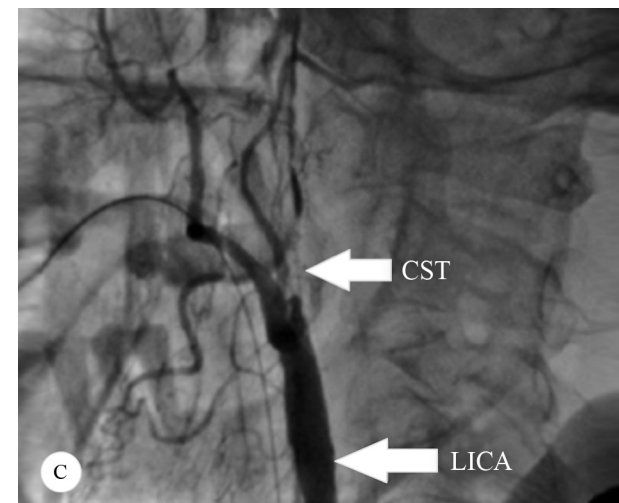
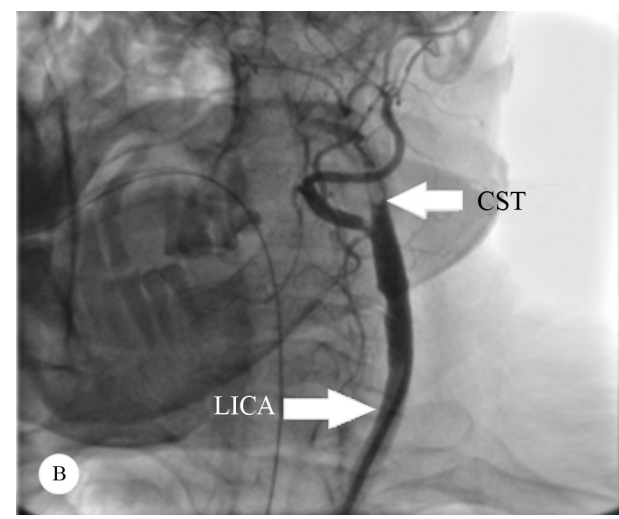
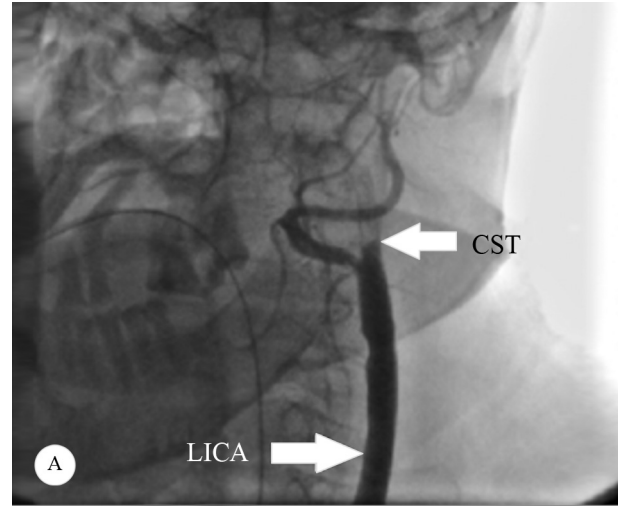


Figure 2. A, B & C) The lateral angiographic view of the LICA shows the second CST, which happened acutely during the procedure (acute CST). LICA, Left internal carotid artery; CST, Carotid stent thrombosis

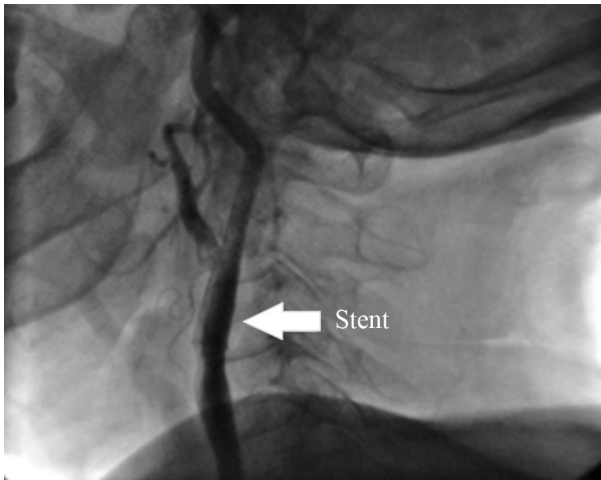


Figure 3. The lateral angiographic view of the LICA shows carotid stenting with a 7×40 mm carotid stent after the acute CST during the procedure. LICA, Left internal carotid artery; CST, Carotid stent thrombosis

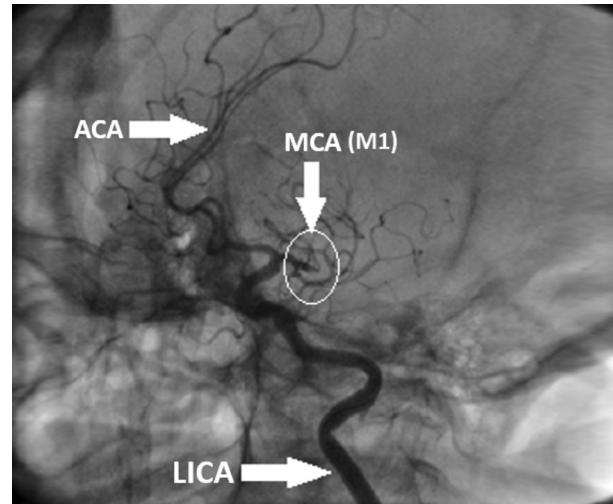


Figure 6. The image shows the lateral angiographic view of the LICA and the cerebral arteries. At the end of the procedure, the carotid artery was opened, but the MCA from the M2 branch was still occluded. LICA, Left internal carotid artery; MCA, Middle cerebral artery; ACA, Anterior cerebral artery

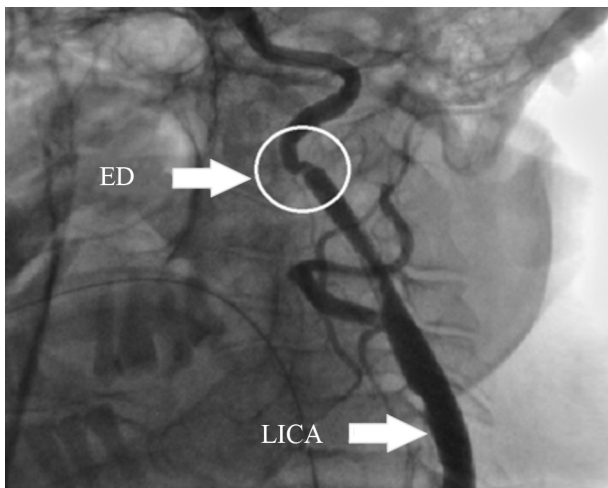


Figure 4. The lateral angiographic view of the LICA shows a suspected iatrogenic ED after the delivery of the carotid stent. LICA, Left internal carotid artery; ED, Edge dissection

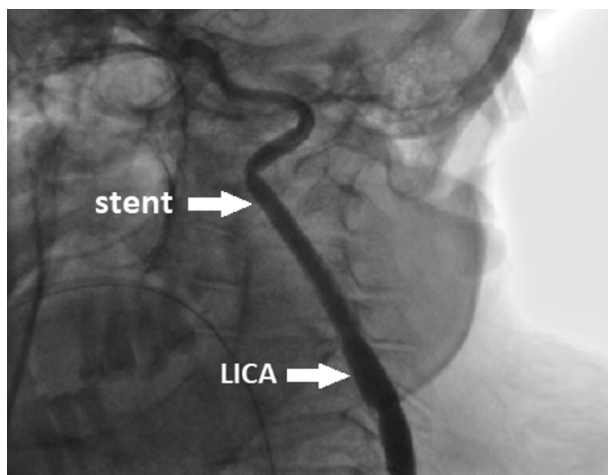


Figure 5. The lateral angiographic view of the LICA shows the resolution of the second carotid stent thrombosis with the aid of a XIENCE Alpine Coronary Stent. LICA, Left internal carotid artery

Regrettably, 4 days later, the patient expired due to sepsis, ventilator-associated pneumonia, and disseminated intravascular coagulation.

Discussion

Endovascular procedures for treating carotid atherosclerotic lesions are increasingly used, hence the significance of attention to potential complications. Stent thrombosis can be a fatal complication and requires immediate prevention and management.

The approach to a patient with CST depends on the experience of each center and the availability of an expert surgeon, a neuro-intervention team, and adequate equipment. In a systematic review and meta-analysis, Andreia Pires Coelho et al⁷ concluded that the surgical approach was the best choice in unstable patients provided that the emergence of complications be considered. Endovascular treatment is another option, but the results of long-term follow-ups are not clear yet. Setacci et al¹¹ posited that due to such concerns over endovascular complications as intraprocedural embolization, surgery was the best approach to the treatment of patients with CST. Xiromeritis et al¹² recommended facilitated thrombolysis as the best approach, with thrombosuction as the second choice in unsuccessful procedures. Other studies have favored a percutaneous approach using mechanical thrombectomy plus intravenous abciximab.^{13,14} Several other investigations have also suggested abciximab as an adjuvant therapy for the endovascular intervention in patients with CST.¹⁵⁻¹⁷ Antman et al¹⁸ recommended a half dose of the fibrinolytic regimen. In a case reported by

Steiner-Boker et al,¹⁹ the use of facilitated thrombolysis using intra-arterial abciximab and a recombinant tissue plasminogen activator by catheterization was successful. Murray et al²⁰ suggested aspiration thrombectomy plus angioplasty as a suitable approach to patients with CST.

Our patient underwent the first carotid stenting procedure in another center; accordingly, the exact severity of the carotid stenosis was not clear to us. What further complicated the case was a lack of data regarding the procedure. According to the patient's history, she presented with a TIA to the first center, where evaluations made her a candidate for elective carotid stenting. Based on such limited data, the carotid stenosis seemed significant. Our first approach to the patient was thrombosuction in the occluded carotid stent following consultations with a neuro-intervention expert in another city. Unfortunately, we had no access to thrombectomy facilities for the cerebral arteries; therefore, given the high mortality rate in such patients, we injected alteplase into the carotid artery. Immediately after the thrombosuction and the alteplase injection, the patient suffered a second thrombosis. We considered edge dissection in the distal part of the stent or stent malposition as the differential diagnosis. In this phase, we performed a second stenting procedure. To our chagrin, the distal edge of the second stent was dissected, forcing us to deploy a third stent on the overlapping area of the previous 2 stents. Our first approach was thrombectomy alone, and we did not consider using a stent in the carotid artery. Nonetheless, the aforementioned complications in the carotid artery rendered the use of second and third stents inevitable. We succeeded in resolving the occlusion in the carotid artery and restoring a normal blood flow. She was transferred to our ICU, where she expired due to ventilator-associated pneumonia 4 days later.

As we mentioned above, our patient resided in a rural area and underwent the first stenting procedure in a large city by a neuro-interventional expert. She was discharged 24 hours after the first procedure. When she suffered the complication, her unstable status and the considerable distance to the first center precluded her transfer. We did what was feasible to save the patient, including consulting a neuro-intervention expert in another city over the phone before and several times during the procedure. We wish to emphasize that the aim of this case presentation is to share our experience with others with a view to preventing CST in the future.

Our patient received alteplase as adjuvant therapy and underwent an endovascular approach. She suffered 2 episodes of thrombosis. The first one was a subacute CST without a clear cause. Nevertheless, despite the appropriate administration of dual antiplatelet therapy, stent thrombosis occurred, likely due to resistance to clopidogrel, noncompliance, and the use of an under-expansion stent. The second thrombosis was acute and happened during the

procedure. In addition to resistance to clopidogrel, the use of an oversized stent, the unavailability of an appropriate carotid stent, the lack of proximal protection, and suspected iatrogenic edge dissection may have played significant roles in this complication. It is deserving of note that our center lacked a vascular surgeon. Moreover, although a history of poorly-controlled diabetes mellitus was not mentioned, the patient's high glucose levels at admission suggested that she was in a hypercoagulable state.

Conclusion

Stent thrombosis is a serious complication of CAS, and the following measures are recommended to prevent its occurrence. After carotid procedures, patients need long hospital lengths of stay in comparison with those undergoing other types of interventions. Sufficient heed should be paid to patients with the abrupt closure of the stent or those at high risk for any type of complication. In addition, P2Y12 platelet function tests should be considered in high-risk patients, such as diabetic or morbidly obese patients. Further, patients should be evaluated in terms of hypercoagulable states. To that end, the treating physician should pay special attention to blood sugar control in patients with diabetes mellitus. Elective procedures should even be postponed in high-risk patients, if possible. Moreover, clopidogrel (150 mg) should be administered daily for at least 1 month. In this regard, patients should receive information about compliance with the regimen. Finally, centers should feature well-equipped ICUs suitable for the provision of due care for this group of patients.

References

1. Naylor AR, Ricco JB, de Borst GJ, Debus S, de Haro J, Halliday A, Hamilton G, Kakisis J, Kakkos S, Lepidi S, Markus HS, McCabe DJ, Roy J, Sillesen H, van den Berg JC, Vermassen F, Esvs Guidelines Committee, Kolh P, Chakfe N, Hinchliffe RJ, Koncar I, Lindholt JS, Vega de Ceniga M, Verzini F, Esvs Guideline Reviewers, Archie J, Bellmunt S, Chaudhuri A, Koelemay M, Lindahl AK, Padberg F, Venermo M. Editor's Choice - Management of Atherosclerotic Carotid and Vertebral Artery Disease: 2017 Clinical Practice Guidelines of the European Society for Vascular Surgery (ESVS). *Eur J Vasc Endovasc Surg* 2018;55:3-81.
2. Hobson RW 2nd. Update on the Carotid Revascularization Endarterectomy versus Stent Trial (CREST) protocol. *J Am Coll Surg* 2002;194(1 Suppl):S9-14.
3. Featherstone RL, Brown MM, Coward LJ; ICSS Investigators. International carotid stenting study: protocol for a randomised clinical trial comparing carotid stenting with endarterectomy in symptomatic carotid artery stenosis. *Cerebrovasc Dis* 2004;18:69-74.
4. Moulakakis KG, Mylonas SN, Lazaris A, Tsivgoulis G, Kakisis J, Sfyroeras GS, Antonopoulos CN, Brountzos EN, Vasdekis SN. Acute Carotid Stent Thrombosis: A Comprehensive Review. *Vasc Endovascular Surg* 2016;50:511-521.



5. Kasper GC, Wladis AR, Lohr JM, Roedersheimer LR, Reed RL, Miller TJ, Welling RE. Carotid thromboendarterectomy for recent total occlusion of the internal carotid artery. *J Vasc Surg* 2001;33:242-249.
6. Eckstein HH, Ringleb P, Allenberg JR, Berger J, Fraedrich G, Hacke W, Hennerici M, Stingle R, Fiehler J, Zeumer H, Jansen O. Results of the Stent-Protected Angioplasty versus Carotid Endarterectomy (SPACE) study to treat symptomatic stenoses at 2 years: a multinational, prospective, randomised trial. *Lancet Neurol* 2008;7:893-902.
7. Coelho AP, Lobo M, Nogueira C, Gouveia R, Campos J, Augusto R, Coelho N, Semiao AC, Canedo A. Overview of evidence on risk factors and early management of acute carotid stent thrombosis during the last two decades. *J Vasc Surg* 2019;69:952-964.
8. Juhan-Vague I, Alessi MC, Vague P. Thrombogenic and fibrinolytic factors and cardiovascular risk in non-insulin-dependent diabetes mellitus. *Ann Med* 1996;28:371-380.
9. Kanemaru K, Nishiyama Y, Yoshioka H, Satoh K, Hashimoto K, Hanihara M, Horikoshi T, Ozaki Y, Kinouchi H. In-stent thrombosis after carotid artery stenting despite sufficient antiplatelet therapy in a bladder cancer patient. *J Stroke Cerebrovasc Dis* 2013;22:1196-1200.
10. Markatis F, Petrosyan A, Abdulamit T, Bergeron P. Acute carotid stent thrombosis: a case of surgical revascularization and review of treatment options. *Vascular* 2012;20:217-220.
11. Setacci C, de Donato G, Setacci F, Chisci E, Cappelli A, Pieraccini M, Castriota F, Cremonesi A. Surgical management of acute carotid thrombosis after carotid stenting: a report of three cases. *J Vasc Surg* 2005;42:993-996.
12. Xiromeritis K, Dalainas I, Stamatakos M, Katsikas V, Martinakis V, Stamatelopoulos K, Psarros V. Acute carotid stent thrombosis after carotid artery stenting. *Eur Rev Med Pharmacol Sci* 2012;16:355-362.
13. Tong FC, Cloft HJ, Joseph GJ, Samuels OB, Dion JE. Abciximab rescue in acute carotid stent thrombosis. *AJNR Am J Neuroradiol* 2000;21:1750-1752.
14. Bush RL, Bhamra JK, Lin PH, Lumsden AB. Transient ischemic attack due to early carotid stent thrombosis: successful rescue with rheolytic thrombectomy and systemic abciximab. *J Endovasc Ther* 2003;10:870-874.
15. Kopp CW, Steiner S, Nasel C, Seidinger D, Mlekusch I, Lang W, Bartok A, Ahmadi R, Minar E. Abciximab reduces monocyte tissue factor in carotid angioplasty and stenting. *Stroke* 2003;34:2560-2567.
16. Kapadia SR, Bajzer CT, Ziada KM, Bhatt DL, Wazni OM, Silver MJ, Beven EG, Ouriel K, Yadav JS. Initial experience of platelet glycoprotein IIb/IIIa inhibition with abciximab during carotid stenting: a safe and effective adjunctive therapy. *Stroke* 2001;32:2328-2332.
17. Abciximab in Ischemic Stroke Investigators. Abciximab in acute ischemic stroke. A randomized, double-blind, placebo-controlled, dose-escalation study. *Stroke* 2000;31:601-609.
18. Antman EM, Giugliano RP, Gibson CM, McCabe CH, Coussement P, Kleiman NS, Vahanian A, Adgey AA, Menown I, Rupprecht HJ, Van der Wieken R, Ducas J, Scherer J, Anderson K, Van de Werf F, Braunwald E. Abciximab facilitates the rate and extent of thrombolysis: results of the thrombolysis in myocardial infarction (TIMI) 14 trial. The TIMI 14 Investigators. *Circulation* 1999;99:2720-2732.
19. Steiner-Böcker S, Cejna M, Nasel C, Minar E, Kopp CW. Successful revascularization of acute carotid stent thrombosis by facilitated thrombolysis. *AJNR Am J Neuroradiol* 2004;25:1411-1413.
20. Murray NM, Wolman DN, Marks M, Dodd R, Do HM, Lee JT, Heit JJ. Endovascular Treatment of Acute Carotid Stent Occlusion: Aspiration Thrombectomy and Angioplasty. *Cureus* 2020;12:e7997.

Arash Amin, MD

Assistant Professor of Interventional Cardiology and CT angiography,
Lorestan University of Medical Sciences (LUMS),
Lorestan Heart Center (Madani Hospital),
Imam-Hosseini Square,
Khorramabad,
Lorestan Province,
Iran.
6814713115.
Tel: +98 066 33436997.
Fax: +98 066 33437164.
E-mail: arash.amiin@gmail.com.

Majid Maleki, MD, FACC, FESC, FAPSC

Professor of Interventional Cardiology and Echocardiography,
Rajaie Cardiovascular,
Medical and Research Center,
Vali-e-Asr Avenue,
Hashemi Rafsanjani (Niayesh) Highway,
Tehran,
Iran.
1995614331.
Tel: +98 21 23922192.
Fax: +98 21 22042026.
E-mail: majid33@yahoo.com.

Zeinab Norouzi, MD*

Cardiac Rehabilitation Department,
Rajaie Cardiovascular Medical and Research Center,
Vali-e-Asr Avenue,
Hashemi Rafsanjani (Niayesh) Highway,
Tehran,
Iran.
1995614331.
Tel: +98 21 23923066.
Fax: +98 21 22042026.
E-mail: zeinab.norouzi.md@gmail.com.

Mohammad Almasian, PhD

Lorestan University of Medical Sciences (LUMS),
Anooshirvan Rezaei Square,
Khorramabad,
Lorestan,
Iran.
6813833946.
Tel: +98 66 33302033.
Fax: +98 66 33302030.
E-mail: almasian26@gmail.com.



Mina Ghorbanpoor Kohnaki, MD

Rajaie Cardiovascular Medical and Research Center,

Vali-e-Asr Avenue,

Hashemi Rafsanjani (Niayesh) Highway,

Tehran,

Iran.

1995614331.

Tel: 02123921.

Fax: 02122042026.

E-mail: minaghorbanpoor2020@gmail.com.