

## Coronary Artery Perforation after Guidewire Removal

Hosein Vakili, MD\*, Roxana Sadeghi, MD, Mohammad Reza Biranvand, MD, Mohammad Hasan Namazi, MD, Habibollah Saadat, MD, Morteza Safi, MD, Mohammad Reza Motamedi, MD

Cardiovascular Research Center, Modarres Hospital, Shaheed Beheshti University of Medical Sciences, Tehran, Iran.

Received 13 July 2008; Accepted 18 November 2008

### Abstract

Coronary artery perforation is a rare, but potentially serious, complication of percutaneous coronary intervention and is associated with a high incidence of death, Q-wave myocardial infarction, and emergency coronary bypass surgery. Management is different but requires prompt recognition and treatment.

We describe a case of coronary perforation only after guidewire removal and also review the management of vessel rupture and perforation.

*J Teh Univ Heart Ctr* 4 (2009) 248-252

**Keywords:** Coronary vessels • Cardiac tamponade • Pericardiocentesis • Angioplasty, transluminal, percutaneous coronary

### Introduction

Coronary perforation, albeit rare, is one of the most dreaded complications occurring in the catheterization laboratory mainly because it has historically been associated with a high rate of major adverse outcomes.<sup>1</sup> We describe a case of right coronary artery perforation just after guidewire removal and review the management of vessel rupture and perforation.

### Case Report

A 666-year-old woman with long-standing hypertension and dyslipidemia referred to our hospital with progressive exertional angina of six months' duration. ECG showed inverted T-wave in the inferior leads. On echocardiography, left ventricular (LV) systolic function was preserved. She underwent selective coronary angiography, which revealed that the LM was normal, Left Anterior Descending Artery

(LAD) had 60% stenosis at mid portion, Left Circumflex Artery (LCX) had 90% stenosis at mid portion, and Right Coronary Artery (RCA) had long stenotic lesion up to 80% (Figure 1).

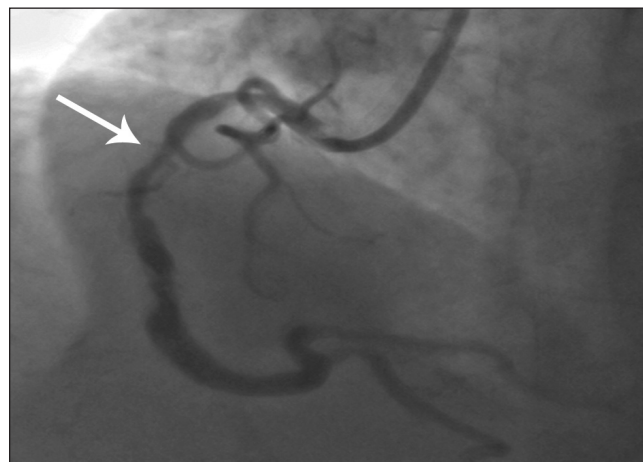


Figure 1. Right coronary artery before angioplasty (arrow)

\*Corresponding Author: **Hosein Vakili**, Associate Professor of Cardiology, Shaheed Beheshti University, Modarres Hospital, Tehran, Iran. Tel: +98 21 22083106. Fax: +98 21 22083106. E-mail: Hosavak@yahoo.com.



Given her symptoms, coronary angioplasty was decided upon. Percutaneous coronary intervention (PCI) on the LCX was done at the same session with a 2.75-16 mm Taxus stent, but PCI on the RCA was performed 35 days later.

The RCA was engaged using a 7-Fr JR 3.5 guide (Cordis, Miami, USA). The patient received weight-based heparin (100U/Kg) bolus. An ASAHI intermediate guidewire was advanced into the distal RCA and another ASAHI soft guidewire in the side branch of the RCA.

A 4-32 Liberte stent was deployed at the mid portion of the RCA and another 4-28 Liberte stent at the proximal part of the RCA with some overlapping with the previous stent. Post dilatation of the overlapping site of the stents was performed with a 4-28 mm balloon. Although a good result was seen with contrast injection before guidewire removal (Figure 2), angiography just after guidewire removal (Figure 3) showed coronary artery perforation with a free flow of the contrast into the pericardial space (Type III of coronary artery perforation).

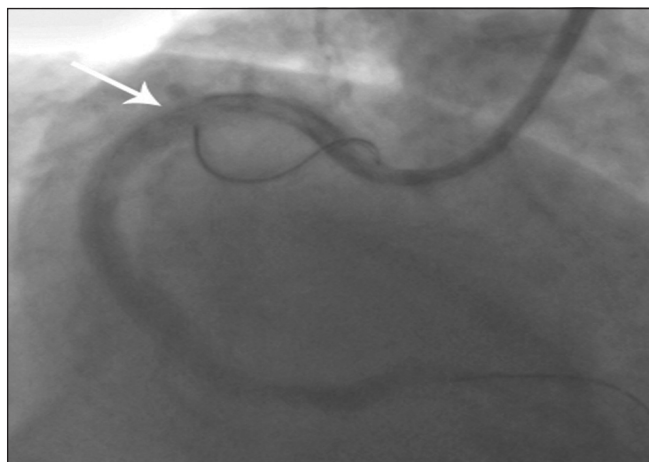


Figure 2. Right coronary artery after angioplasty and before the guidewire removal (arrow)

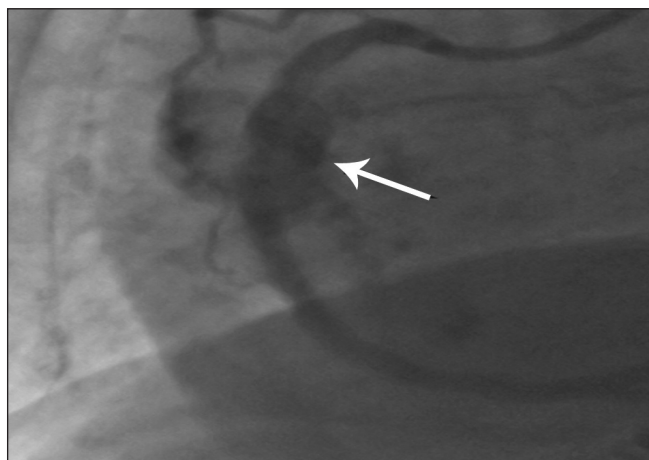


Figure 3. Right coronary artery after guidewire removal (coronary artery perforation-type III)

Balloon inflation at the site of the perforation with a 4-28 mm balloon at 6 atm was done immediately, which was unsuccessful. Cardiovascular collapse, tamponade, and apnea occurred. The effect of heparin was reversed with 30 mg of intravenous Protamine. Cardiac surgery was consulted. Pericardiocentesis was performed, and a 16 mm Jomed coronary stent graft sealed the perforation site successfully.

Angiogram performed immediately and at 10 minutes subsequently showed no further leakage with good results (Figure 4). The patient had an uneventful post-operative course. A Pigtail drainage catheter was left in the pericardial space for 3 days, and the patient was discharged on the 7th day after PCI without any ECG changes.

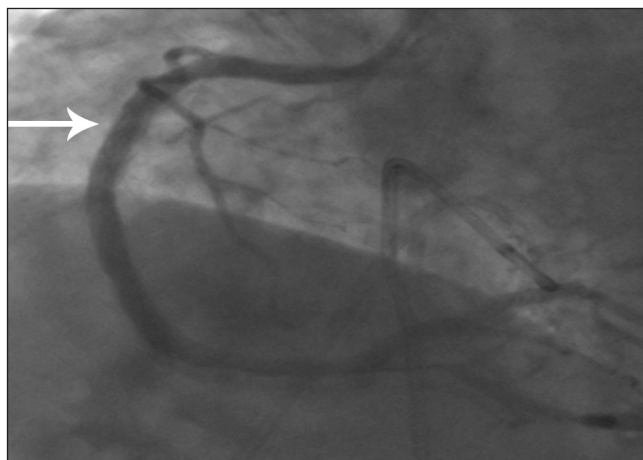


Figure 4. Final result after covered Stent deployment (arrow)

## Discussion

Angiographically documented perforations were graded according to the Ellis et al classification.<sup>1</sup> In brief, perforation grade 1 refers to an extraluminal crater without contrast extravasation; perforation grade 2 indicates the presence of pericardial or myocardial blush without contrast jetting; and perforation grade 3 involves a frank perforation with contrast jetting. Perforation resolution was considered when no residual contrast extravasation was observed. Procedure success was defined as attainment of final thrombolysis in myocardial infarction grade 3 flows in the target vessel with perforation resolution or a grade 1 residual perforation after baseline perforation grade 2 or worse, and absence of in-hospital major adverse cardiac events.<sup>2</sup>

Perforation with balloon angioplasty is rare, occurring in 0.1% of cases. Treatment with ablative devices such as the excimer laser and rotablator, has been associated with a higher incidence of coronary artery perforation (0.5-3.0%).<sup>3</sup> Procedural characteristics that have been associated with an increased risk of vessel perforation include device oversizing (in balloon angioplasty or stenting) and use of

an atheroablative device (directional atherectomy, excimer laser, rotablaters, and extraction catheters).<sup>4</sup>

In the Dippel et al.,s report of more than 6,000 interventions, ablative procedures were accorded a 6.8-fold risk of perforation.<sup>5</sup> In addition, the perforations associated with these technologies were often Ellis type III. However, atheroablative devices are often indicated for severe lesion calcification, which is also a risk factor associated with perforation.

Guidewire-induced perforation has also been well described, particularly using stiff hydrophilic wires when employed in tortuous anatomy and chronic total occlusions. Severe perforation is found in 31% of cases of guidewire perforation,<sup>5</sup> and wire perforation during PCI for chronic total occlusion causes 62% of cases of delayed cardiac tamponade.<sup>6</sup> In a recent trial, coronary perforation in 38,559 procedures was 0.19%. The precipitating events just prior to perforation included atheroablation in 29%, wire perforation in 21%, Plain Old Balloon Angioplasty (POBA) in 28%, and stenting in 25%.<sup>7</sup>

More recent reports, which had a higher proportion of stent usage, did not show the use of stents as being associated with a higher incidence of perforation.<sup>4,7</sup> Interestingly, the use of glycoprotein IIb/IIIa antagonists does not appear to affect the incidence, severity, and outcome of coronary perforation.<sup>5</sup>

Usually, coronary artery perforation becomes apparent immediately after PCI. However, its delayed appearance has been reported following the implantation of stent and PCI using a debulking device<sup>8,9</sup> or a cutting balloon catheter.<sup>10</sup>

The treatment for vessel perforation or rupture include prompt recognition of vessel perforation, immediate balloon tamponade of the injured vessel, rapid reversal of anticoagulation or antiplatelet therapy, addressing hemodynamic instability, involvement of surgeons if appropriate, and specific treatment of the vessel perforation or rupture with a bailout device such as a covered stent or embolization coils for distal vessel perforation or rupture.<sup>11</sup>

Specifically, balloon tamponade of the perforation should be performed immediately. Perfusion balloons (e.g., the SURPASS balloon, Boston Scientific, Natick, and MA) are no longer manufactured and, therefore, not currently a therapeutic option.<sup>11</sup>

The manner of anticoagulation reversal depends on the agent used. Heparin is easily reversed by the use of protamine to an activated clotting time of <150 seconds<sup>12</sup> but should be avoided in diabetic patients with a history of protamine-insulin use. Glycoprotein IIb/IIIa inhibitors should be discontinued when a vessel perforation occurs.<sup>13</sup>

Abciximab effects can be reversed by platelet transfusion. Platelet transfusions are of little efficacy in patients receiving eptifibatide or tirofiban as these drugs have a much higher free plasma concentrations. Eptifibatide and tirofiban have shorter half-lives, and their antiplatelet effects resolve within a few hours unless significant renal impairment is present.<sup>9</sup>

The direct thrombin inhibitor, bivalirudin, does not have a specific antidote but has a short half-life with the return of coagulation 1-2 hours after the discontinuation of the drug.<sup>14</sup>

Cessation of these pharmacologic agents and reversal of anticoagulation with protamine is recommended only with frank rupture and hemopericardium. If at all possible, it is preferable to continue these agents while intracoronary balloons and wires are in place to prevent coronary thrombosis.<sup>15</sup>

Hemodynamic instability can be caused by cardiac tamponade. Management of these complications will include pericardiocentesis and timely blood transfusions, respectively.

The JOSTENT coronary stent graft (CSG) device (Abbott Vascular Devices, Abbott Park, Illinois) consists of an ultra thin, biocompatible, and expandable polytetrafluoroethylene (PTFE) layer sandwiched in between two coaxial 316L stainless steel, slotted-tube, balloon-expandable stents.<sup>2</sup> Overall wall thickness reaches 0.30 mm, and the device crossing profile is 1.6 mm. Diameters from 2.5 to 5.0 mm may be achieved.

Several reports have described the use of the PTFE-covered CSG in treating coronary perforations with favorable results.<sup>16-19</sup> A retrospective international registry reports the outcomes of the polytetrafluoroethylene-coated JOSTENT coronary stent graft in 41 cases of coronary perforations. The perforations were relatively severe: 16.7% Ellis grade 1, 54.2% grade 2, and 29.1% grade 3. Of the 41 patients, >1/3 (n=14) experienced life-threatening complications before stent graft implantation, including pericardial tamponade (12.2%), cardiogenic shock (9.8%), and cardiac arrest (2.4%). A total of 52 CSGs were used to treat the 41 perforations (mean 1.3 per lesion). All the CSGs were placed successfully, with 92.9% of the perforations sealed completely and 7.1% partially. One patient developed abrupt vessel closure after CSG deployment, resulting in an overall procedure success rate of 96.4%. No in-hospital Q-wave myocardial infarctions, emergency coronary bypass surgeries, or deaths resulted. The CSG may be a reliable and highly effective treatment option for sealing coronary perforations complicating PCI.<sup>2</sup>

It is accepted that these covered stents have a higher risk of thrombosis. In a retrospective analysis of 70 patients treated with the Jomed TM covered stent for a variety of indications (e.g. vein grafts, coronary perforation, and in-stent restenosis), there were a total of four (5.7%) patients with subacute (7-10 days post-implantation) thrombosis, despite dual antiplatelet therapy with aspirin and thienopyridines.<sup>20</sup> Hence, the use of long-term (minimum 1 year) antiplatelet therapy would be advisable.<sup>21</sup>

If a life-threatening perforation occurs while working with a smaller guide requiring the CSG for sealing, a balloon angioplasty catheter (or stent delivery balloon) should immediately be inflated across the tear in the coronary



vessel to provide temporary hemostasis. A 7Fr catheter guide should then be introduced by way of the contralateral femoral artery access and used to cannulate the coronary ostium after gently disengaging the smaller guide. The CSG should be introduced into the 7Fr guide over a second guidewire and passed just proximal to the occluding balloon, which is thereafter deflated and retracted, allowing the passage of the new guidewire and CSG for the definitive closure of the perforation.<sup>2</sup>

Autologous vein-covered stents have been described as an effective treatment option for successful percutaneous sealing of perforations.<sup>22</sup> However, isolating the graft (typically a cephalic vein) by cut down and mounting and suturing it onto a metallic stent is logistically impossible in patients with a free-flowing perforation and incipient cardiac arrest.

Other techniques include the use of thrombin injection,<sup>23</sup> fibrin glue,<sup>24</sup> and embolization with autologous clots,<sup>25</sup> subcutaneous tissue,<sup>26</sup> microcoils,<sup>27</sup> and polyvinyl alcohol<sup>28</sup> or gelfoam,<sup>29</sup> which are intended to form thrombi in vessels.

In a retrospective analysis of 12,900 patients who underwent coronary interventions between 1990 and 1991, 62 (0.5%) perforations were documented. In that series, 13 (21%) cases were classified as grade 1, 31 (50%) as grade 2, and 16 (26%) as grade 3.<sup>1</sup> Emergency bypass surgery after failed conventional treatment was needed in 15%, 10%, and 56% of the patients with grade 1, 2, and 3 perforations, respectively. The rate of death, myocardial infarction, and pericardial tamponade was 0%, 0%, and 8% for grade 1 perforations, 0%, 14%, and 13% for grade 2 perforations, and 19%, 50%, and 63% for grade 3 perforations, respectively. The clinical outcomes resulting from coronary perforation correlated directly with the perforation grade.<sup>30,31</sup>

Close observation is strongly advised on account of the fact that small leaks or late tear extension can lead to sudden deterioration and the development of cardiac tamponade up to 48 hours later. Serial echocardiography and careful monitoring in an intensive care environment should be performed after stabilization.

## Conclusion

We herein described one case of RCA perforation following percutaneous intervention only after guidewire removal. A potentially fatal complication, the case was successfully managed by the deployment of a PTFE-covered stent, without the need for surgical intervention. In summary, be ready to deal with any unexpected exigencies in the cath lab.

## Acknowledgments

This case was supported by Shaheed Beheshti University of Medical Sciences.

## References

1. Ellis SG, Ajluni S, Arnold AZ, Popma JJ, Bittl JA, Eigler NL, Cowley MJ, Raymond RE, Safian RD, Whitlow PL. Increased coronary perforation in the new device era. Incidence, classification, management, and outcome. *Circulation* 1994;90:2725-2730.
2. Lansky AJ, Yang YM, Khan Y, Costa RA, Pietras C, Tsuchiya Y, Cristea E, Collins M, Mehran R, Dangas GD, Moses JW, Leon MB, Stone GW. Treatment of coronary artery perforations complicating percutaneous coronary intervention with a poly tetrafluoroethylene-covered stent graft. *Am J Cardiol* 2006;98:370-374.
3. Roguin A, Beyar R. Coronary perforation 2006-Watch for the wire. *J Invasive Cardiol* 2005;17:606-608.
4. Gunning MG, Williams IL, Jewitt DE, Shah AM, Wainwright RJ, Thomas MR. Coronary artery perforation during percutaneous intervention: incidence and outcome. *Heart* 2002; 88:495-498.
5. Dippel EJ, Kereiakes DJ, Tramuta DA, Broderick TM, Shimshak TM, Roth EM, Hattemer CR, Runyon JP, Whang DD, Schneider JF, Abbottsmith CW. Coronary perforation during percutaneous coronary intervention in the era of abciximab platelet glycoprotein IIb/IIIa blockade: an algorithm for percutaneous management. *Catheter Cardiovasc Interv* 2001;52:279-286.
6. Fukutomi T, Suzuki T, Popma JJ, Hosokawa H, Yokoya K, Inada T, Hayase M, Kondo H, Ito S, Suzuki S, Itoh M. Early and late clinical outcomes following coronary perforation in patients undergoing percutaneous coronary intervention. *Circ J* 2002;66:349-356.
7. Javadi A, Buch AN, Satler LF, Kent KM, Suddath WO, Lindsay J Jr, Pichard AD, Waksman R. Management and outcomes of coronary artery perforation during percutaneous coronary intervention. *Am J Cardiol* 2006;98:911-914.
8. Suylen RJ, Serruys PW, Simpson JB, de Feyter PJ, Strauss BH, Zondervan PE. Delayed rupture of right coronary artery after directional atherectomy for bail-out. *Am Heart J* 1991;121:914-916.
9. Abhyankar AD, England D, Bernstein L, Harris PJ. Delayed appearance of distal coronary perforation following stent implantation. *Cathet Cardiovasc Diagn* 1998;43:311-312.
10. Maruo T, Yasuda S, Shunichi Miyazaki Sh. Delayed appearance of coronary following cutting balloon angioplasty. *Catheter Cardiovasc Interv* 2002;57:529-531.
11. Yeo K, Rogers J, Laird J. Use of stent grafts and coils in vessel rupture and perforation. *J Intervent Cardiol* 2008;21:86-99.
12. Stoelting RK. Allergic reactions during anesthesia. *Anest Analg* 1983;62:341-356.
13. Scarborough RM, Kleiman NS, Phillips DR. Platelet glycoprotein IIb/IIIa antagonists: what are the relevant issues concerning their pharmacology and clinical use? *Circulation* 1999;100:437-444.
14. Nutescu EA, Wittkowsky AK. Direct thrombin inhibitors for anticoagulation. *Ann Pharmacother* 2004;38:99-109.
15. Klein LW. Coronary artery perforation during interventional procedures. *Catheter Cardiovasc Interv* 2006;68:713-717.
16. Briguori C, Nishida T, Anzuini A. Emergency polytetrafluoroethylene-covered stent implantation to treat coronary ruptures. *Circulation* 2000;102:3028-3031.
17. Ramsdale DR, Mushahwar SS, Morris JL. Repair of coronary artery perforation after rotastenting by implantation of the Jostent covered stent. *Cath Cardiovasc Diagn* 1998;45:310-313.
18. Welge D, Haude M, von Birgelen C. Management of coronary perforation after percutaneous balloon angioplasty with a new membrane stent. *Z Kardiol* 1998;87:948-953.
19. Von Birgelen C, Haude M, Herrmann J. Early clinical experience with the implantation of a novel synthetic coronary stent graft. *Cath Cardiovasc Inter* 1999;47:496-503.
20. Gercken U, Lansky AJ, Buellesfeld L, Desai K, Badereldin M, Mueller R, Selbach G, Leon MB, Grube E. Results of the Jostent coronary stent graft implantation in various clinical settings: procedural and follow-up results. *Catheter Cardiovasc Interv* 2002;56:353-360.
21. Gamma R, Thomas MR. Successful nonsurgical treatment of left



- main Stem perforation by sacrifice of the LAD. *Catheter Cardiovasc Interv* 2006;69:845-849.
22. Colombo A, Itoh A, Di Mario C. Successful closure of a coronary vessel rupture with a vein graft stent: case report. *Cathet Cardiovasc Diagn* 1996;38:172-174.
  23. Jamali AH, Lee MS, Makkar RR. Coronary perforation after percutaneous coronary intervention successfully treated with local thrombin injection. *J Invasive Cardiol* 2006;18:E143-145.
  24. Storger H, Ruef J. Closure of guide wire-induced coronary artery perforation with a two-component fibrin glue. *Catheter Cardiovasc Interv* 2007;70:237-240.
  25. Hadjimiltiades S, Paraskevaides S, Kazinakis G, Louridas G. Coronary vessel perforation during balloon angioplasty: a case report. *Cathet Cardiovasc Diagn* 1998;45:417-420.
  26. Oda H, Oda M, Makiyama Y, Kashimura T, Takahashi K, Miida T, Higuma N. Guidewire-induced coronary artery perforation treated with transcatheter delivery of subcutaneous tissue. *Cathet Cardiovasc Diagn* 2005;66:369-374.
  27. Aslam MS, Messersmith RN, Gilbert J, Lakier JB. Successful management of coronary artery perforation with helical platinum microcoil embolization. *Catheter Cardiovasc Interv* 2000;51:320-322.
  28. Yoo BS, Yoon J, Lee SH, Kim JY, Lee HH, Ko JY, Lee BK, Hwang SO, Choe KH. Guidewire-induced coronary artery perforation treated with transcatheter injection of polyvinyl alcohol form. *Catheter Cardiovasc Interv* 2001;52:231-234.
  29. Dixon SR, Webster MW, Ormiston JA, Wattie WJ, Hammett CJ. Gelfoam embolization of a distal coronary artery guidewire perforation. *Catheter Cardiovasc Interv* 2000;49:214-220.
  30. Liu F, Erbel R, Haude M, Ge J. Coronary arterial perforation: prediction, diagnosis, management, and prevention. In: Ellis SG, Holmes DR Jr, eds. *Strategic Approaches in Coronary Intervention*, 2nd ed. Philadelphia: Lippincott Williams and Wilkins; 2000. p. 501-514.
  31. Rogers JH, Lasala JM. Coronary artery dissection and perforation complicating percutaneous intervention. *J Invasive Cardiol* 2004;16:493-499.