

# Management of Iatrogenic Rupture of Profunda Femoris Artery after Femoral Fracture Fixation with Stent Graft Implantation

Hamidreza Varastehrahan, MD, Hossein Nough, MD, Zahra Ansari, MD\*

*Afshar Hospital, Shaheed Sadoughi Medical University, Yazd, Iran.*

Received 09 August 2008; Accepted 24 December 2008

## Abstract

*Vascular injuries with acute or chronic arterial hemorrhage after femoral shaft fractures are a rare but a life-threatening complication. We observed a case of iatrogenic rupture of the profunda femoris artery after the internal fixation of a femoral shaft fracture. The pseudoaneurysm, presenting with painful expansile swelling and hemodynamic instability, together with the rupture was evident on femoral angiography. Endovascular stent graft placement was performed successfully, and there was no sign or symptom at 9 months' follow-up.*

*J Teh Univ Heart Ctr 1 (2010) 42-44*

**Keywords:** Stents • Pseudoaneurysm • Iatrogenic disease

## Introduction

Acute or late rupture of arteries after femoral fracture is rare and usually caused by iatrogenic trauma<sup>1</sup> or rarely by bone spikes.<sup>2,3</sup> The profunda femoris pseudoaneurysms following various orthopedic surgical procedures have previously been described.<sup>1</sup> The diagnosis is usually delayed because of nonspecific clinical features such as pain, anemia, fever, and hematoma.<sup>1</sup>

Management of a profunda femoris artery pseudoaneurysm has changed from surgical intervention<sup>4</sup> to radiological intervention<sup>1</sup> because of difficult access to the deep muscle compartment of the thigh, where the profunda femoris artery is located.

We herein present a case of a profunda femoris pseudoaneurysm after the fixation of a femoral shaft fracture which was managed via stent grafting.

## Case report

An 18-year-old man with a close fracture of the mid shaft of the right femur, sustained in a car accident, underwent an open reduction internal fixation. On physical examination, the distal pulses and sensation of the right leg were normal and there were no signs of nerve or artery damage.

After surgery, the patient was discharged with normal vital signs. On the same day, however, the patient returned to the hospital with a markedly painful, expansible swelling at the medial aspect of his right thigh as well as anemia (Hb = 7). This was initially diagnosed as a post-operative hematoma, so the patient underwent surgical hematoma drainage. The following day, the patient's clinical condition exacerbated with the painful swelling recurring; he was referred for angiography in the cath lab in conscious state.

Selective arteriography of the superficial artery and profunda femoris artery via the contralateral approach showed a pseudoaneurysm of the right thigh with a maximum

\*Corresponding Author: Zahra Ansari, Shaheed Sadoughi University of Medical Sciences, Cardiovascular Research Center, Afshar Hospital, The Islamic Republic Boulevard, Yazd, Iran. Postal cod: 8917945556. Tel: +98 351 5231421. Fax: +98 351 5253335. Email: nedansari@yahoo.com.

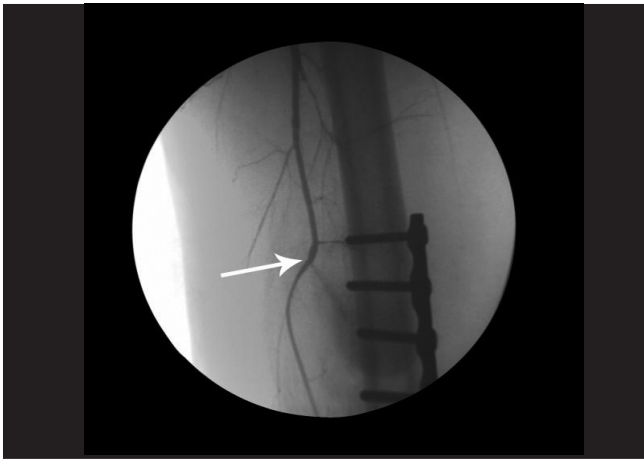


Figure 1. Arteriography of the superficial and profunda femoris arteries via the contralateral approach. The arrow shows the rupture of the profunda femoris and dye jetting from the rupture before stenting. The pseudoaneurysm of the right thigh, originating from the pinpoint perforation of the distal right profunda femoris artery and dye jetting into the pseudoaneurysm, is shown

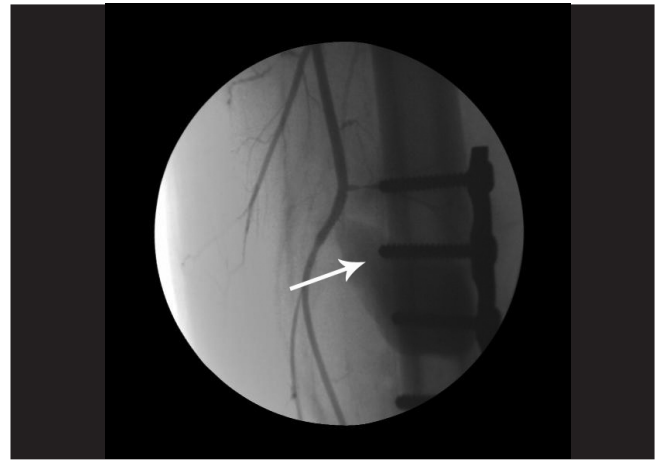


Figure 2. The arteriography of the superficial and profunda femoris arteries via the contralateral approach after stenting. The arteriogram shows complete cessation of the blood and dye jetting from the profunda into the pseudoaneurysm. The arrow shows the aspects of the pseudoaneurysm

diameter of 9 cm, originating from a pinpoint perforation of the distal right profunda femoris artery with a diameter of about 3 mm and jetting of the dye to the pseudoaneurysm (Figure 1). The superficial femoral artery and run-off were normal.

Given the potential difficulties of open surgical repair, the patient was candidate for transcatheter stent graft placement, to be performed simultaneously with angiography in the cat lab and without anesthesia. After selective engagement of the right SFA via the contralateral approach with a multi-purpose 6F guiding catheter and administration of 5000 U IV Heparin and 2 gr IV Keflin, a 0.018 v-18 control wire was passed along the right profunda femoris. The diameter of the artery was estimated at 3mm; a 3.25 × 16 mm Jomed coronary graft stent was, therefore, passed through in order to cover the perforation and it was subsequently inflated at 14 atm. Injection into the right profunda femoris artery showed the sealing and complete cessation of the blood and dye jetting from the profunda into the pseudoaneurysm (Figure 2). In Figure 1, dye is jetting from the rupture but in Figure 2 after stent graft inflation there is no dye jetting. Aspects of the pseudoaneurysm are marked in Figure 2.

Heparin was not reversed, and 325 mg Aspirin and 600 mg Plavix were prescribed stat with Keflin 1gr IV QID for 24 hours and Aspirin 80 mg/d and Plavix 75 mg/d for one month. The patient's general condition and vital signs rapidly improved, and sonography 2 days later was indicative of a reduction in the mass diameter in the right thigh (about 3-4 cm) with the patency of the right profunda femoris artery. After discharge on the fourth day, the patient was prescribed Aspirin (80 mg/day) and Plavix (75 mg/day) for one month. At one month's follow-up, sonography was completely normal and there was no sign or symptom on physical examination.

## Discussion

The profunda femoris artery is the largest branch of the femoral artery. Injuries to the proximal part of the profunda femoris artery may cause external hemorrhage because of the artery's superficial location. But more distal injuries such as injuries due to mid-shaft fracture of the femur may produce silent lesions<sup>5</sup> on account of the fact that peripheral pulses are not affected unless the superficial femoral artery is injured or compromised by a compressing hematoma. Pseudoaneurysms and arteriovenous fistulae are the probable complications of these silent lesions.<sup>6</sup>

Iatrogenic pseudoaneurysms of the femoral artery after the fracture of the femur are rare.<sup>3,7</sup> Detection of pseudoaneurysms tends to be delayed usually because a progressive swelling is painless in most cases,<sup>8</sup> unless hemodynamic instability and high clinical suspicion of active bleeding prompts a diagnosis of the rupture of the artery and pseudoaneurysm.<sup>7</sup> Pain, hematoma, swelling, occasional fever, unexplained anemia, and hemodynamic instability are non-specific clinical signs.<sup>4</sup> It is worthy of note that the thigh compartment syndrome has also been observed after pseudoaneurysm formation.<sup>9</sup>

Planning the line of management in cases with the rupture of the artery or pseudoaneurysms depends on the length and size of lesions.<sup>10</sup> Also in such cases, open surgical repair is rendered difficult by the presence of a hematoma. Moreover, active bleeding reduces access to the deep muscle compartment of the thigh, where the profunda femoris artery is located adjacent to the proximal femoral shaft. A review of the existing medical literature shows that the successful transcatheter treatment of penetrating injuries to the profunda femoris artery has already been reported.<sup>11,12</sup>

## Conclusion

Profunda femoris artery rupture is a rare iatrogenic complication of femoral shaft fracture fixation. Clinical suspicion can be confirmed by angiography. Be that as it may, whereas the surgical treatment of such cases is usually hampered by the relative inaccessibility of the anatomical compartment involved, transcatheter stent graft placement performed simultaneously with angiography is now the first of choice of management.

## References

1. Tiwary SK, Kumar S, Khanna R, Khanna AK. Iatrogenic femoral artery aneurysm in orthopedic practice. *ANZ J Surg* 2007;77:899-901.
2. Murphy PG, Geoghegan JG, Austin O, More-O'Ferrall R, Quinlan WR, Keaveny TV. Pseudoaneurysm of the profunda femoris artery due to intertrochanteric fracture of the hip. *Arch Orthop Trauma Surg* 1999;119:117-118.
3. Sethuraman V, Hozack WJ, Sharkey PF, Rothman RH. Pseudoaneurysm of femoral artery after revision total hip arthroplasty with a constrained cup. *J Arthroplasty* 2000;15:531-534.
4. Sarwar CM, Riaz S, Lukhadwala RH. Postfixation pseudoaneurysm of the superficial femoral artery in femoral shaft fracture. *J Coll Physicians Surg Pak* 2004;14:687-688.
5. Montales E, Yao ST, Silva YJ. Management of traumatic peripheral arteriovenous fistulas. *J Trauma* 1973;13:161-165.
6. Sclafani SJ, Shaftan GW. Transcatheter treatment of injuries to the profunda femoris artery. *AJR* 1982;138:463-466.
7. Entwisle JJ, De Nunzio M, Hinwood D. Transcatheter embolization of pseudoaneurysm of the profunda femoris artery complicating fracture of the femoral neck. *Clin Radiol* 2001;56:424-427.
8. D'Angelo F, Piffaretti G, Carrafiello G, Tozzi M, Caronno R, Castelli P, Zatti G. Endovascular repair of a pseudo-aneurysm of the common femoral artery after revision total hip arthroplasty. *Emerg radiol* 2007;14:233-236.
9. Nadeem RD, Clift BA, Martindale JP, Hadden WA, Ritchie IK. Acute compartment syndrome of the thigh after joint replacement with anticoagulation. *J Bone Joint Surg Br* 1998;80:866-868.
10. Diethrich EB. Endoluminal grafting in the treatment of iliac and superficial femoral artery disease. *Tex Heart Inst J* 1997;24:185-192.
11. Mitchell DG, Needleman L, Bezzi M, Goldberg BB, Kurtz AB, Pennell RG, Rifkin MD, Vilaro M, Baltarowich OH. Femoral artery pseudoaneurysm: diagnosis with conventional and colour Doppler us. *Radiology* 1987;165:687-690.
12. Smejkal K, Zvák I, Trlica J, Raupach J, Neumann J. Traumatic pseudoaneurysm of arteria femoralis profunda: the case report. *Rozhl Chir* 2007;86:116-119.