



## Ablation of Focal Right Upper Pulmonary Vein Tachycardia Using Retrograde Aortic Approach

Ahmad Yamini Sharif, MD\*, Gholamreza Davoodi, MD, Ali Vasheghani Farahani, MD, Hadi Fadavi, MD, Ali Kazemi Saeed, MD, Saeed Sadeghian, MD, Fatemeh Ghazachai, MSc, Mehrdad Sheikhvatan, MD

Tehran Heart Center, Tehran University of Medical Sciences, Tehran, Iran.

Received 10 July 2009; Accepted 23 February 2010

*The use of diagnostic and therapeutic methods for assessing pulmonary vein due to its status as a main source of ectopic beats for the initiation of atrial dysrhythmias is strongly recommended. We report the case of a 13-year-old girl who was admitted to our hospital with the electrocardiogram manifestation of an ectopic atrial tachycardia. The focus of arrhythmia was inside the right upper pulmonary vein. The patient underwent successful ablation with a conventional electrophysiology catheter via the retrograde aortic approach. We showed that when the origin of atrial tachycardia is in the right upper pulmonary vein, it is possible to advance the catheter into this vein via the retrograde aortic approach and find the focus of arrhythmia. This case demonstrates that right upper pulmonary vein mapping is feasible through the retrograde aortic approach and it is also possible to ablate the arrhythmia using the same catheter and approach.*

*J Teh Univ Heart Ctr 3 (2010) 146-149*

**Keywords:** Catheter ablation • Tachycardia, ectopic atrial • Pulmonary veins

### Introduction

Pulmonary veins (PV) were found to be important sources of ectopic beats for the initiation of atrial dysrhythmias.<sup>1</sup> Therefore, using diagnostic and therapeutic methods for assessing PV is recommendable. The present case demonstrates the feasibility of advancing a conventional electrophysiology (EP) catheter into the right upper pulmonary vein (RUPV) via the retrograde aortic approach.

### Case report

A 13-year-old girl was admitted to our hospital in September 2008 with the electrocardiogram (ECG) manifestation of an

ectopic atrial tachycardia (AT) with a cycle length (cl) of 300 m sec. The tachycardia was incessant.

A P-wave morphology evaluation in standard 12-lead ECG revealed positive P-waves in D1, inferior leads, and all precordial leads. P-wave was negative in aVL and aVR (Figure 1).

Echocardiography showed an ejection fraction of 35% and left atrium size of 27 mm with no evidence of valvular heart disease.

Electrophysiological study was performed using two quadripolar catheters in the right atrium and right ventricle: one decapolar in the coronary sinus and one Halo catheter in the right atrium.

Intracardiac recording was obtained using a Bard EP lab system. Bipolar electrograms were filtered at 30 to 500 HZ.

During AT, the earliest right atrial activation was recorded

\*Corresponding Author: Ahmad Yamini Sharif, Associate Professor of Cardiology, Tehran University of Medical Sciences, Tehran Heart Center, Jalal Al Ahmad & North Kargar Cross, Tehran, Iran. 1411713138. Tel: +98 21 88029600-69. Fax: +98 21 88029731. E-mail: yaminisharif.a@doctor.com.

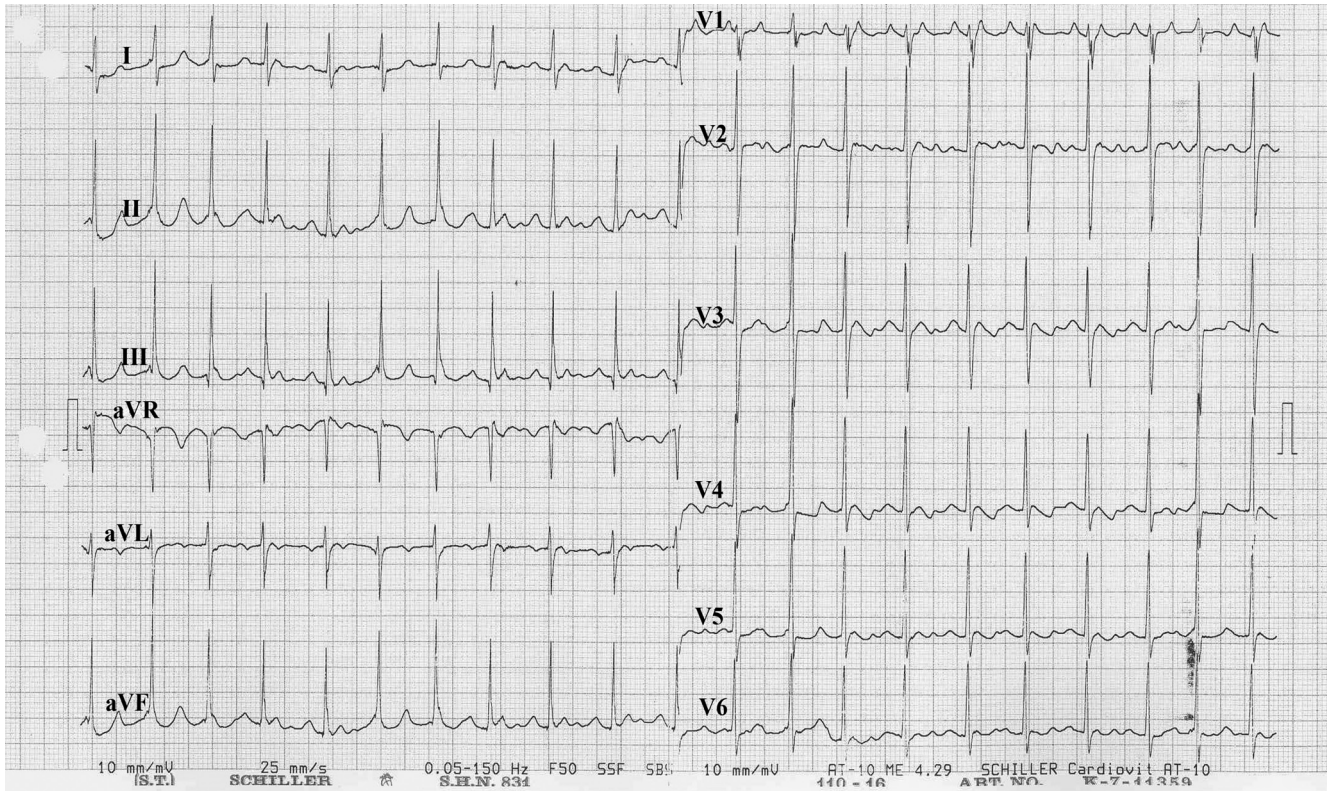


Figure 1. Surface 12-lead electrocardiogram shows atrial tachycardia with positive P-waves in D1, inferior leads, and all precordial leads and negative P-waves in aVL and aVR

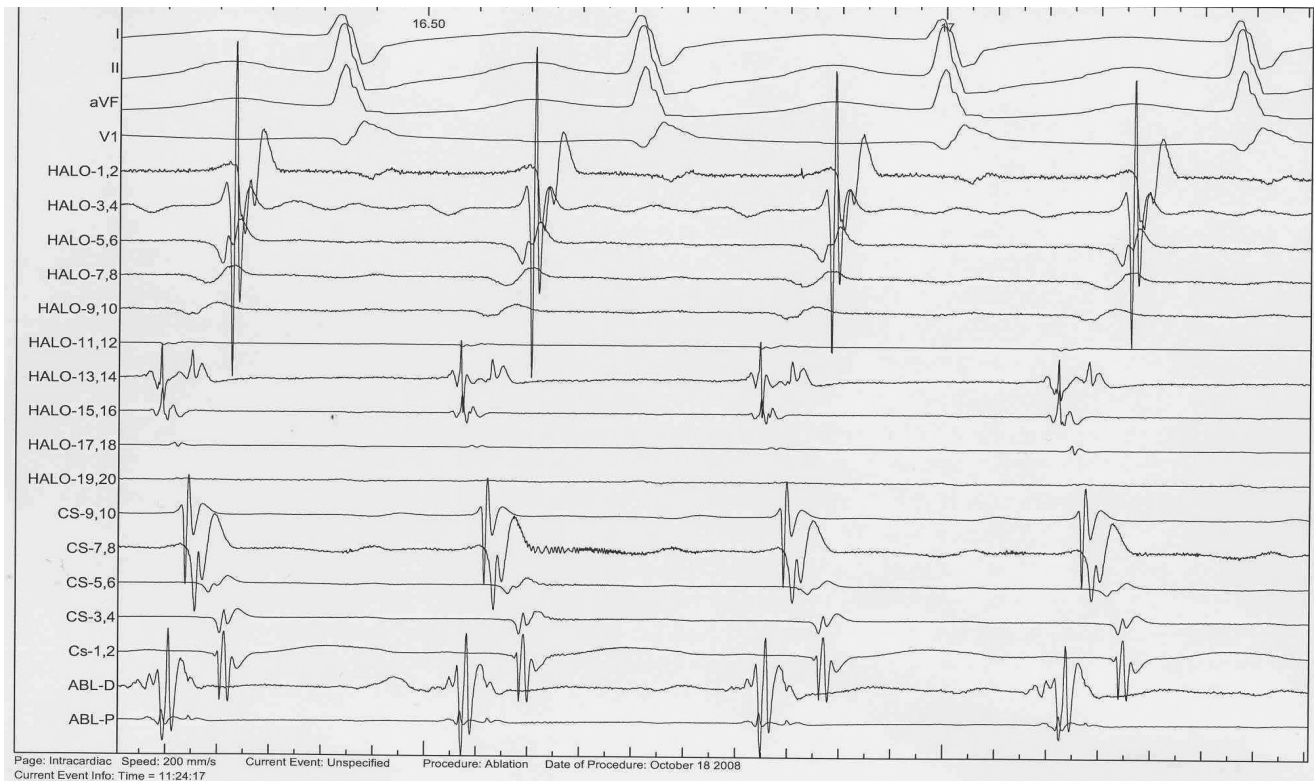

Figure 2. Surface electrocardiogram I, II, aVF, and V<sub>1</sub> and intra-cardiac recording during atrial tachycardia shows double potential in Halo 13, 14. Ablating catheter was at the orifice of right upper pulmonary vein



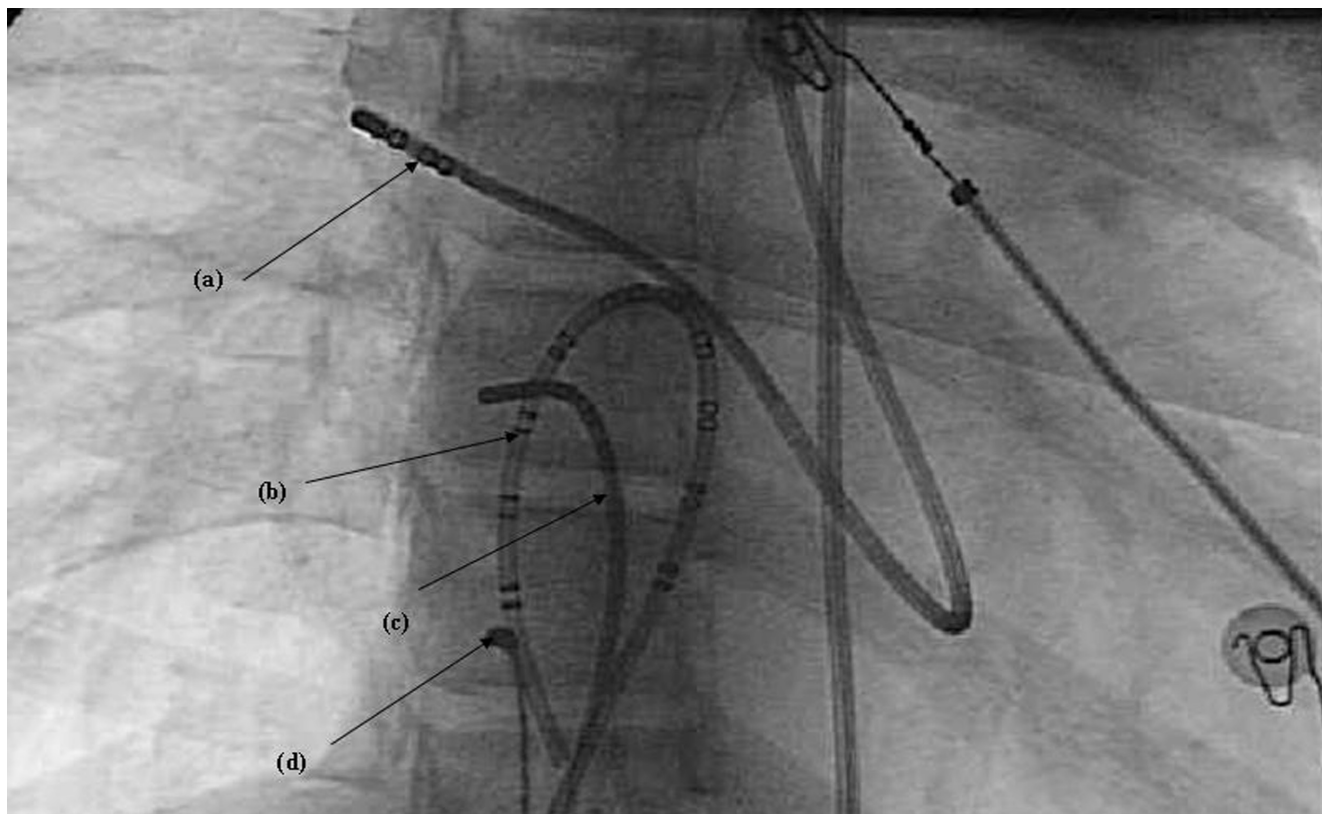


Figure 3. Fluoroscopic image at shallow right anterior oblique projection showing the positioning of ablating catheter in right upper pulmonary vein (a), Halo (b), dislodged coronary sinus catheter (c), and right atrial catheter (d)

at high posterior right atrium. At this site, double potential was also recorded during the tachycardia (Figure 2).

Radiofrequency (RF) ablation at this site could not terminate the tachycardia; consequently, a 7 Fr Biosense-Webster (34E67R) ablating catheter was advanced into the left ventricle without the need for any long sheath via the retrograde aortic approach. The choice of this approach was the result of our experience in its application. The ablating catheter was then maneuvered to pass across the mitral valve, so that the left atrium was accessed. Left atrial mapping was thereafter performed, which revealed that the area of interest was near the orifice of the RUPV. The catheter was advanced into the RUPV, and the recording of low amplitude fractionated electrical activity helped locate the focus of the arrhythmia. Finally, the arrhythmia was ablated by applying some RF currents around the orifice of this vein (outside the orifice) and only one RF current (20 Watt-60° C-40 seconds) just at the origin of AT. The total procedure time was 120 minutes, and the fluoroscopy time was 45 minutes. After ablation, the arrhythmia was not inducible with different stimulation protocols even during Isoproterenol infusion.

Clinical follow-up showed no recurrence of the arrhythmia, there was no evidence of pulmonary vein stenosis, and ejection fraction had returned to normal.

## Discussion

Transseptal puncture is most often used for electrophysiological procedures in the left atrium.<sup>2</sup> Newer techniques and increased experience have improved the safety of this procedure and reduced some risk.<sup>3</sup> Although the success rate of transseptal puncture is usually above 95%, it occasionally fails<sup>2, 3</sup> especially when repeat transseptal puncture is necessary.<sup>4</sup>

In some patients, contraindication may also present. Given the number of patients presenting for percutaneous left atrial ablation, it is important that second line, non-surgical approaches be found to access the left atrium in the cases where the transseptal approach is contraindicated. Standard steerable catheters can be placed retrogradely on the atrial side of the mitral annulus for the ablation of accessory pathways, but to our knowledge there is no report about advancing the catheter into the RUPV via the retrograde aortic approach.

Although there is previous a report on the ablation of focal left atrial tachycardia via a retrograde approach using remote magnetic navigation<sup>5</sup> and another report on the cannulation of the pulmonary vein in five canines using a retrograde transaortic magnetic-enabled approach,<sup>6</sup> we managed to establish an RUPV access in this patient without resorting to the magnetically enabled catheter and successfully mapped



the focal RUPV tachycardia.

## **Conclusion**

This case demonstrates that RUPV mapping is feasible via the retrograde aortic approach and it is also possible to ablate the arrhythmia using the same catheter and approach. This method should be tried only when there is an absolute contraindication for the transseptal approach by electrophysiologists who are experts in this method.

## **References**

1. Chen SA, Hsieh MH, Tai CT, Tsai CF, Prakash VS, Yu WC, Hsu TL, Ding YA, Chang MS. Initiation of atrial fibrillation by ectopic beats originating from the pulmonary veins: electrophysiological characteristics, pharmacological responses, and effects of radiofrequency ablation. *Circulation* 1999;100:1879-1886.
2. De Ponti R, Zardini M, Storti C, Longobardi M, Salernno-Uriarte JA. Trans-septal catheterization for radiofrequency catheter ablation of cardiac arrhythmias. Results and safety of a simplified method. *Eur Heart J* 1998;19:943-950.
3. Gonzalez MD, Otomo K, Shah N, Arruda MS, Beckman KJ, Lazzara R, Jackman WM. Transseptal left heart catheterization for cardiac ablation procedures. *J Interv Card Electrophysiol* 2001;5:89-95.
4. Marcus GM, Ren X, Tseng ZH, Badhwar N, Lee BK, Lee RJ, Foster E, Olgin JE. Repeat transseptal catheterization after ablation for atrial fibrillation. *J Cardiovasc Electrophysiol* 2007;18:55-59.
5. Thornton AS, Rivero-Ayerza M, Jordaens LJ. Ablation of a focal left atrial tachycardia via a retrograde approach using remote magnetic navigation. *Europace* 2008;10:687-689.
6. Greenberg S, Blume W, Faddis M, Finney J, Hall A, Talcott M, Lindsay B. Remote controlled magnetically guided pulmonary vein isolation in canine. *Heart Rhythm* 2006;3:71-76.