



# Cardiovascular Manifestation of a Family with Marfan's Syndrome

Mohammad Hossein Davari, MD<sup>1</sup>, Toba Kazemi, MD<sup>1\*</sup>, Hossein Alimirzaei, MD<sup>2</sup>, Mohamad Reza Rezvani, MD<sup>1</sup>

<sup>1</sup>Birjand Cardiovascular Research Center, Birjand University of Medical Sciences, Birjand, Iran.

<sup>2</sup>Vali Asr Hospital, Birjand University of Medical Sciences, Birjand, Iran.

Received 24 May 2010; Accepted 23 August 2010

## Abstract

Marfan's syndrome (MFS) is a genetic disorder associated with autosomal dominant inheritance. In MFS, the most prevalent cause of death is cardiovascular involvement. Here we introduce a family with a severe penetration of MFS. Eleven members of this family have MFS (father, two daughters, three sons, and five grandchildren). The most common cardiac involvement in our patients was mitral valve prolapse as manifested by mitral regurgitation. At ten years' follow-up, two patients had aortic root dilatation running the risk of aortic dissection; they were, therefore, scheduled for cardiac surgery, during which the Bentall procedure was successfully performed. Fortunately, all of the members of this family are currently alive.

*J Teh Univ Heart Ctr* 2011;6(1):37-40

**This paper should be cited as:** Davari MH, Kazemi T, Alimirzaei H, Rezvani MR. Cardiovascular manifestation of a family with marfan's syndrome. *J Teh Univ Heart Ctr* 2011;6(1):37-40.

**Keywords:** Marfan syndrome • Connective tissue diseases • Family • Cardiac manifestation

## Introduction

Marfan's syndrome (MFS) is a connective tissue disorder with autosomal dominant inheritance and affects about 1 in 5,000 individuals. The cause of MFS is mutation in fibrillin gene on chromosome 15.<sup>1</sup> The defective gene can be inherited, so the child of a person who has MFS has a 50% chance of inheriting the disease.<sup>1</sup> No geographic, gender, and race predilection is known.<sup>2</sup> MFS can affect several organs, including the skeleton, eyes, heart, and blood vessels.<sup>1</sup>

The diagnosis of MFS is confirmed by clinical signs, although genetic and molecular tests enhance diagnostic certainty. Currently, the main diagnostic criterion is the Ghent nosology.<sup>3</sup> Cardiovascular disease (aortic dilatation and dissection) is the major cause of morbidity and mortality in MFS patients.<sup>4</sup>



Figure 1. Family members with Marfan's syndrome. From left to right: father (1), first son and his daughter (2, 3), second son and his two sons (4-6), third son (7), second daughter and her son (8-9), and first daughter and her daughter (10-11)

\*Corresponding Author: Toba Kazemi, Associate Professor of Cardiology, Birjand University of Medical Sciences, Birjand Cardiovascular Research Center, Ghaffari Street, Valiassr Hospital, Birjand, Iran. Tel: +98 56 1443001-9. Fax: +98 56 14433004. E-mail: drtooba.kazemi@gmail.com.

Here we introduce a family (Figure 1), eleven members of whom had MFS. The family lived in the south-eastern Iranian city of Birjand, and we have followed it up all for ten years now.

### Cases Report

In 1998, a 17-year-old male (second son of this family) was referred to an ophthalmologist for visual disturbances. The ophthalmologic examination revealed lens displacement, iridodentosis, and high intraocular pressure. The patient's tall stature and arachnodactily (Figures 2 & 3) arouse the suspicion of MFS and he was referred to a cardiologist for further investigation. Echocardiography further established the diagnosis of MFS by demonstrating aortic root dilation and mitral valve prolapse (Figure 4).

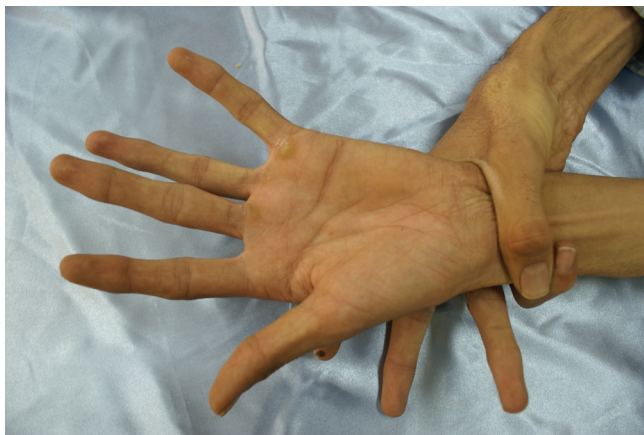

Figure 2. Positive wrist sign and arachnodactily

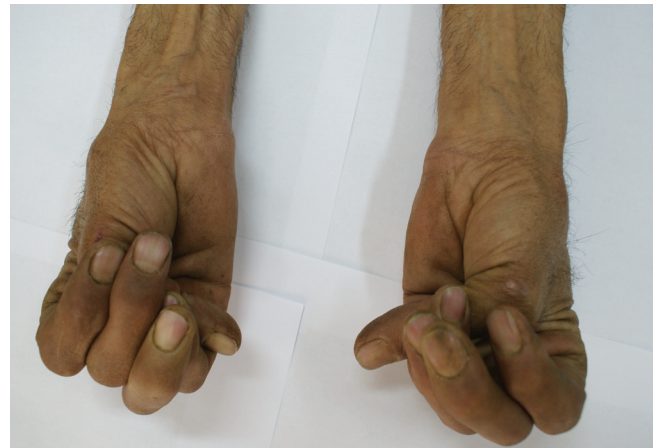

Figure 3. Positive thumb sign

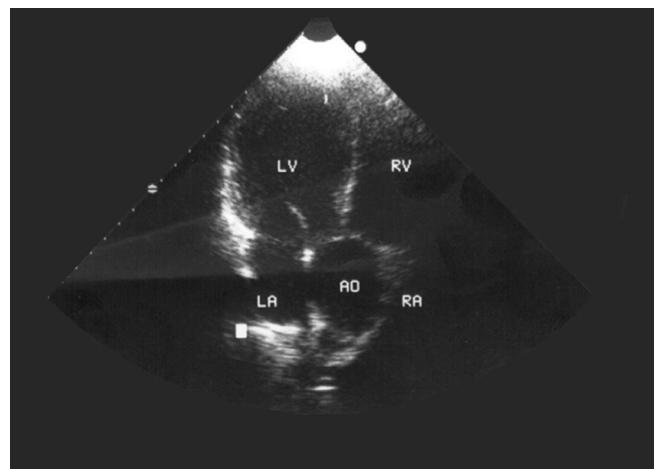


Figure 4. Parasternal view of echocardiography, showing aortic root dilatation AO, Aorta; LA, Left atrium; LV, Left ventricle; RA, Right atrium; RV, Right ventricle

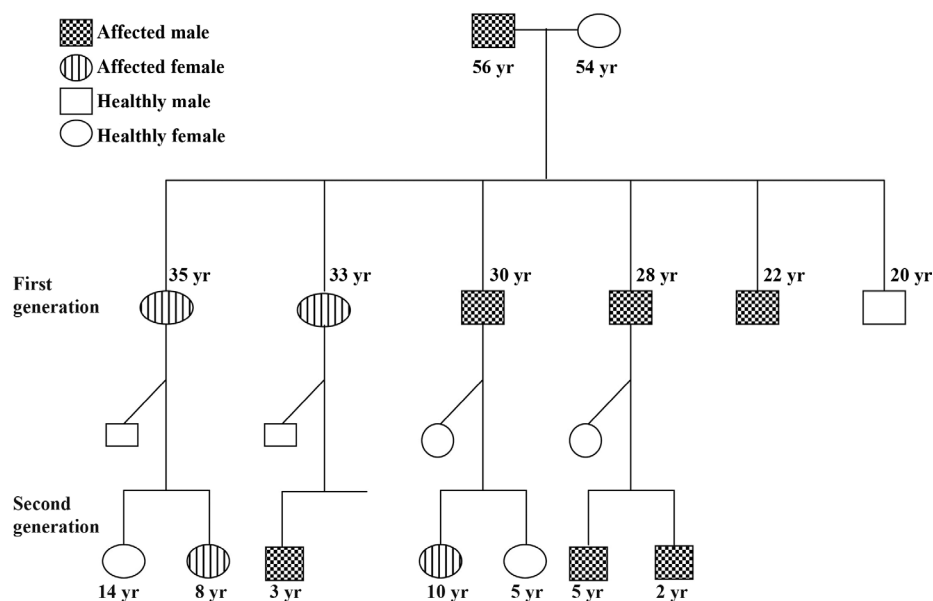


Figure 5. Pedigree of the family



Thereafter, all the members of the patient's family were examined by a single cardiologist and ophthalmologist. It transpired that the patient's father, two brothers, and two sisters were also afflicted with MFS; only the patient's mother and one brother were healthy. The diagnosis of MFS was fully confirmed via the Ghent nosology (1996). It should be mentioned, however, that unfortunately, genetic analysis was not feasible in Birjand.

Since then, all the members of this family have been visited periodically by a cardiologist and an ophthalmologist. In total, there are 11 individuals with MFS in this family, and we think MFS with such severe genetic penetration is rare (Figure 5).

In our patients, mitral valve involvement as manifested by mitral valve prolapse and mitral regurgitation was the most common cardiac involvement (Table 1), followed by the dilatation of the aortic root and aortic insufficiency. Two family members (second boy and second girl) underwent surgery for aortic dissection via the Bentall procedure, during which aortic root graft and aortic valve replacement were performed.

All the family members have undergone echocardiography annually for the past ten years; and if aortic root dilatation exceeds 40 mm, treatment with a beta blocker is commenced.

Table 1. Patients' characteristics

Case	Cardiac Involvement	Complication
Father	MVP, MR, AI ARD=31mm	no
First daughter	MVP, MR ARD=30mm	Two pregnancies without complication
Second daughter	MVP, MR, AI ARD=45mm	One pregnancy without complication, Surgery for threatened aortic dissection
First Son	MVP, MR, AI ARD=47mm	No
Second Son	MVP, MR	Surgery for aortic dissection & AVR
Third Son	MVP, MR ARD=45mm	No
First grandchild	MVP, MR	No
Second grandchild	MVP, MR	No
Third grandchild	MVP, MR	No
Fourth grandchild	MVP, MR	No
Fifth grandchild	Normal	No

MVP, Mitral valve prolapse; MR, Mitral regurgitation; AI, Aortic insufficiency; AVR, Aortic valve replacement; ARD, Aortic root dimension

Despite medical advice to the contrary, two female members of this family have had three pregnancies during this ten-year period. In these women, the aortic root dimension

was < 45mm before pregnancy; during and after pregnancy, however, this diameter did not change significantly. The pregnant women were treated with beta blockers and were monitored with echocardiography. Fortunately, all the three pregnancies ended with normal vaginal deliveries without complications. Two of these 3 children have already been diagnosed with MFS. At the time of this report, the youngest was 6 months old and his status was not determined.

## Discussion

Marfan's syndrome is an inherited connective-tissue disorder transmitted as an autosomal dominant trait.<sup>1</sup> Currently, the main diagnostic criterion is the Ghent nosology, according to which a positive family history associated with the involvement of at least two organs is the basis of diagnosis. In the members of the same family, major involvement in one organ system and involvement in a second organ system are required to make the diagnosis.<sup>3</sup>

Cardiovascular manifestations in MFS include valvular disease involving the mitral valve, aortic valve, or both. Mitral valve prolapse is the most prevalent valvular abnormality, affecting 35%-100% of patients. Mitral regurgitation occurs in 25% of patients and is more common in women and children. Enlarged aortic root occurs in 15%-44% of patients and may distort the aortic valve cusps and produce aortic regurgitation.<sup>5</sup>

Beta blockers play an important role in delaying aortic expansion and progression to rupture or dissection. Indeed, the rate of surgical intervention has declined during the past decade because of the widespread use of beta blockers. Furthermore, beta-blocker therapy retards aortic growth in children and adolescents with MFS, not least when the aortic root diameter is more than 40 mm. Anticoagulation therapies such as warfarin are required after heart-valve replacement; and prior to any surgery or dental procedure, antibiotic therapy is necessary to prevent bacterial endocarditis.<sup>6</sup>

Cardiovascular surgery prolongs the survival of patients with MFS. Emergency surgical replacement of the aortic root is indicated for acute proximal aortic dissection. If the diameter of the aortic root exceeds 55 - 60 mm, the ascending aorta is replaced via the modified Bentall procedure, in which the dilated aortic segment is exchanged with a prosthetic valve sewn into a tube graft in conjunction with the re-implantation of the coronary ostia.<sup>7</sup> Over the past ten years, of all the eleven family members introduced here, two underwent acute aortic dissection in 2004, 2008; they are currently stable and receive propranolol and warfarin.

Pregnancy in women with MFS increases the probability of not only developing acute aortic dissection but also having an affected child in 50% of the cases. Therefore, women with MFS should be counseled before conception about the risk of pregnancy-related complications and the risk of transmitting

the syndrome to the offspring.<sup>8</sup> The risk of complications during pregnancy is due to the aortic root diameter. The Canadian guidelines recommend that women with an aortic root diameter  $\geq 45$  mm and the European guidelines recommend that women with an aortic root diameter  $\geq 40$  mm be discouraged from pregnancy strongly.<sup>9, 10</sup> The vaginal delivery is preferable in patients with MFS who have a normal cardiovascular examination and no evidence of aortic dilatation. In these patients, Cesarean section should be reserved for obstetrical indications. Nonetheless, in patients with aortic dilatation or dissection, Cesarean section should be the preferred choice because it minimizes the hemodynamic changes associated with vaginal delivery.<sup>11</sup>

## Conclusion

It is advisable that not only anyone with MFS be visited by a cardiologist regularly but also all the family members of a patient with MFS be investigated. Furthermore, sufficient information should be provided to parents with MFS on the possibility of transmission to children.

## References

1. Judge DP, Dietz HC. Marfan's syndrome. *Lancet* 2005;366:1965-1976.
2. Leite Mde F, Aoun NB, Borges MS, Magalhães ME, Christiani LA. Marfan's syndrome: early and severe form in siblings. *Arq Bras Cardiol* 2003;81:89-92.
3. Lehmann ED. Cardiovascular screening in Marfan's syndrome *The Lancet* 1995;345:1501-1502.
4. Ammash NM, Sundt TM, Connolly HM. Marfan syndrome: diagnosis and management. *Curr Probl Cardiol* 2008;33:7-39.
5. van Karnebeek CD, Naeff MS, Mulder BJ, Hennekam RC, Offringa M. Natural history of cardiovascular manifestations in Marfan syndrome. *Arch Dis Child* 2001;84:129-137.
6. Ades L; CSANZ Cardiovascular Genetics Working Group. Guidelines for the diagnosis and management of Marfan syndrome. *Heart Lung Circ* 2007;16:28-30.
7. Milewicz DM, Dietz HC, Miller DC. Treatment of aortic disease in patients with Marfan syndrome. *Circulation* 2005;111:e150-157.
8. Hager A, Kaemmerer H, Hess J. Comment on pregnancy and aortic root growth in the Marfan syndrome. *Eur Heart J* 2005;26:2346.
9. Task Force on the Management of Cardiovascular Diseases During Pregnancy of the European Society of Cardiology. Expert consensus document on management of cardiovascular diseases during pregnancy. *Eur Heart J* 2003;24:761-781.
10. Therrien J, Gatzoulis M, Graham T, Bink-Boelkens M, Connelly M, Niwa K, Mulder BJM, Pyeritz RE, Perloff J, Somerville J, Webb GD. Canadian cardiovascular society consensus conference 2001 update: recommendations for the management of adults with congenital heart disease: part II. *Can J Cardiol* 2001;17:1029-1050.
11. Elkayam U, Ostrzega E, Shotan A, Mehra A. Cardiovascular problems in pregnant women with the Marfan syndrome. *Ann Intern Med* 1995;123:117-122.