



Pulsatility Index in Aortic Coarctation: A Possible Way to Evaluate Factors Affecting Stenting Outcome

Shokoufeh Hajsadeghi, MD¹, Seyed-Mohammad Fereshtehnejad, MD, MPH^{2*},
Saeid Gholami, MD³, Mitra Chitsazan, MD³, Mohammad Reza Keramati, MD²

¹Rasoul-e-Akram Hospital, Tehran University of Medical Sciences, Tehran, Iran.

²Firoozgar Clinical Research Development Center, Tehran University of Medical Sciences, Tehran, Iran.

³Student Scientific Research Committee, Tehran University of Medical Sciences, Tehran, Iran.

Received 14 September 2011; Accepted 17 December 2011

Abstract

Background: The pulsatility index (PI) shows continuous blood flow to the end organs and is a significant factor believed to decrease in aortic coarctation. Correction of this factor is of great importance in the treatment of stenotic lesions of the aorta. However, there are minimal data regarding the trend of changes in the PI after stent implantation. Furthermore, the association between the PI and other echocardiographic indices in patients undergoing stent implantation is unclear. This study was designed to evaluate changes in the PI following stenting and its correlation with other echocardiographic indices.

Methods: Twenty-three patients with a diagnosis of aortic coarctation consecutively underwent two-dimensional and Doppler echocardiographic imaging modalities twice (before and after stenting). The patients were divided into two groups based on the percentage of increase in the PI after stenting ($< 50\%$ or $\geq 50\%$). The relation between the post-stenting PI and the baseline echocardiographic indices was assessed.

Results: The PI was increased from 0.89 (SD = 0.30) to 1.75 (SD = 0.51) after stenting (p value < 0.001). Baseline diastolic/systolic velocity (D/S velocity) ratio of the abdominal aorta (p value = 0.013), mean velocity (p value = 0.033), and peak gradient of the descending aorta (p value = 0.033) were significantly higher in the patients with $\geq 50\%$ increase in the PI after stenting.

Conclusion: Our findings showed that elevation in the PI after stenting was a predictable criterion in patients with aortic coarctation: it was predicted by some baseline clinical and echocardiographic indices. Baseline D/S ratio velocity of the abdominal aorta, mean velocity and peak gradient of the descending aorta, and baseline systolic blood pressure were the statistically significant indices to predict $\geq 50\%$ increase in the PI in our patients.

J Teh Univ Heart Ctr 2012;7(1):19-24

This paper should be cited as: Hajsadeghi S, Fereshtehnejad SM, Gholami S, Chitsazan M, Keramati MR. Pulsatility Index in Aortic Coarctation: A Possible Way to Evaluate Factors Affecting Stenting Outcome. *J Teh Univ Heart Ctr 2012;7(1):19-24.*

Keywords: Aortic coarctation • Stents • Echocardiography, Doppler

Introduction

Endovascular stent implantation for coarctation of

the aorta has been used since 1991. Use of this method is associated with fewer complications such as aneurysms, acute ischemia in the spinal cord, and recoarctation compared

*Corresponding Author: Seyed-Mohammad Fereshtehnejad, Tehran University of Medical Sciences, Firoozgar Clinical Research Development Center (FCRDC), Firoozgar Hospital, Beh-Afarin Street, Valiasr Avenue, Tehran, Iran. 1593748711. Tel: +98 21 82141367. Fax: +98 21 88942622. Email: sm_fereshtehnejad@yahoo.com.

to surgery and/or balloon dilatation. However, recoarctation has been reported as its major complication.¹

In previous studies, attempts were made to define clinical indications for using this type of treatment and to evaluate the efficacy and outcome of stent implantation in different groups of patients. Yet, a number of questions still remain to be fully answered. First, currently used indications for stenting have been mostly made based on a group of patients with similar demographic conditions such as age, weight, and comorbidities rather than each patient's status individually.^{2,3} Second, most of the tools drawn upon in the follow-up of these patients are mainly based on evaluating anatomical changes after stent implantation rather than focusing on the hemodynamic status of the stent-inserted aorta.

Hypertension and decreased blood pressure in the lower extremities are assumed as hemodynamic changes which are common findings in patients with coarctation.⁴ Both factors are associated with a decreased pulsatility of the abdominal aorta. Pulsatility of the blood flow in the aorta causes continuous blood flow to the end organs and is a significant factor which is believed to decrease in coarctation. The pressure gradient across the aortic coarctation site results in an altered flow pattern in the abdominal aorta^{5,6} with loss of pulsatility. As a result of decreased pulsatility of the aorta, the flow becomes continuous throughout diastole.⁵ This phenomenon can be assessed via Doppler echocardiography using the pulsatility index (PI) $[(V_{max}-V_{min})/V_{mean}]$ (where V_{max} , V_{min} and V_{mean} represent maximum, minimum, and mean velocities, respectively). Correction of this factor could be an important surrogate of coarctation repairing. There is a dearth of data on the trend of changes in the PI after stent implantation. Also, the association between the PI and other echocardiographic indices in patients undergoing stent implantation is unclear. Recognition of these issues can be useful to predict early and late hemodynamic outcomes in the aorta before stent placement.

This study was designed to evaluate changes in the PI after stent implantation and its correlation with other echocardiographic parameters. Also, the feasibility of some baseline characteristics of patients in predicting the trend of changes in the PI after stent implantation was investigated.

Methods

Twenty-three patients with a diagnosis of congenital aortic coarctation were consecutively enrolled in this prospective study. The patients were referred to Rajaei Cardiovascular, Medical and Research Center (affiliated to Tehran University of Medical Sciences), Tehran, Iran between April 2008 and August 2009. The diagnosis of aortic coarctation was made based on angiography in all the patients. All the patients had type III (postductal) congenital coarctation in the abdominal aorta. The exclusion criteria consisted of any other concomitant

lesions, including aortic stenosis or regurgitation, patent ductus arteriosus, anomalies of the head and neck vessels, and long segment aortic coarctation or hypoplastic arch.

Stenting of the abdominal aortic coarctation was performed for all the patients enrolled in the study. In addition to baseline and demographic variables (e.g. age, gender, blood pressure, and length of stenosis), the characteristics of stenting, including length and width of the stent, length and width of the balloon, and first and second gradients of the cath, were recorded for all the patients. Informed written consent was obtained from all the patients, and the research project was approved by the Ethics Committee of Tehran University of Medical Sciences.

Echocardiographic evaluation (both abdominal and descending aortas) was done twice for all the patients, before stenting and 24 hours after it via two-dimensional and Doppler echocardiographic imaging modalities using a Vivid 3 Imaging System (GE, USA), in accordance with the institutional guidelines (Figure 1). For this purpose, standard suprasternal position was considered to measure the maximum velocity across the coarctation site and then continuous wave Doppler recordings were obtained. Pulsed-wave Doppler from the standard subcostal view was also performed to document the flow pattern of the abdominal aorta. All the echocardiographic studies were performed by a single echo-cardiologist before and after stenting. Moreover, a simultaneous electrocardiographic monitoring was also utilized. The onset of diastole was assumed at the end of the electrocardiographic T-wave, and the three measurements were taken from three consecutive cycles each time. Thereafter, the mean of the three measurements was calculated and reported as the main records.

The continuous values are expressed as mean \pm SD, and frequency percentages are used to describe the categorical variables. The Kolmogorov-Smirnov test was employed to assess the normality of the distribution of the numerical variables, and the Mann-Whitney U-test was performed to compare the significance of the difference in the baseline Doppler echocardiographic profile between the two groups of the patients regarding increase-percentage of the PI of $< 50\%$ or $\geq 50\%$ (50 was the mean percentage of PI increase in these patients after stenting). The receiver operating characteristic curve (ROC) analysis was performed to assess the predictability of $\geq 50\%$ increase in the PI after stenting with quantitative indices of the study, and thereafter to compare the area under curve (AUC) of these variables. The cut-off points were then determined in each ROC analysis. The best predictive cut-off value was that which gave the highest product of sensitivity and specificity. Diagnostic values of each cut-off point, including sensitivity and specificity, were calculated and reported. All the P values were two-tailed and a p value < 0.05 was considered statistically significant. SPSS v.17 software (Chicago, IL, USA) was used for the analytic procedures.

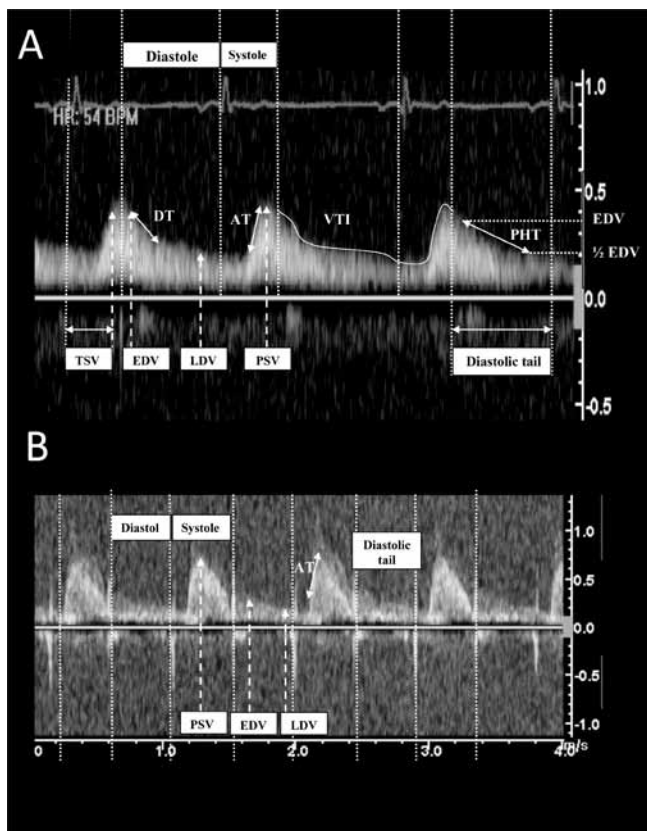


Figure 1. Pulse wave Doppler echocardiography of abdominal aorta: A; before stenting, B; after stenting. AT; systolic acceleration time: is measured from the onset of the systolic upstroke to the systolic peak. DT; deceleration time: is measured from peak E velocity to the point where the slope of the slowing flow would intercept the baseline. EDV; early diastolic velocity: maximum diastolic velocity on early diastole. LDV; late diastolic velocity: maximum diastolic velocity on late diastole. PHT; pressure half time (of diastole): is the time interval for the peak diastolic pressure gradient to be reduced by one half. PSV; peak systolic velocity: maximum systolic velocity. TSV; time to peak systolic velocity: time beginning from onset of QRS complex to peak systolic velocity. VTI; velocity time integral: the area under curve, shown in both systole and diastole

Results

Twenty-three patients, comprised of 16 (69.6%) males and 7 (30.4%) females, who had coarctation stenting were recruited in this study. The mean age of the patients was 26.14 (SD = 10.17) years and the mean duration of the disease was 36.50 (SD = 69.02) months. Other baseline and demographic characteristics of the patients are listed in Table 1. All these 23 patients underwent coarctation stenting with the mean stent size of 37.16 (SD = 3.67) mm × 8.47 (SD = 1.94) mm.

Table 1. Baseline characteristics of the patients*

Age (yr)	26.14±10.17
Gender	
Male	16 (69.6)
Female	7 (30.4)
Blood pressure	
Systolic blood pressure (mmHg)	158.18±24.18
Diastolic blood pressure (mmHg)	85.23±10.96
Duration of disease (mo)	36.50±69.02
Aortic valve	
BAV	13 (56.5)
TAV	10 (43.5)
Length of the stenosis (mm)	20.44±10.47
Ejection fraction (%)	54.55±5.10

*Data are presented as mean±SD or n (%)

BAV, Bicuspid aortic valve; TAV, Tricuspid aortic valve

Echocardiographic Profile

Doppler echocardiography was performed twice for each patient, at baseline and after stenting. The PI was increased from 0.89 (SD = 0.30) to 1.75 (SD = 0.51), which showed improvement of 119.57% (p value < 0.001).

Based on the percentage of increase in the PI (< 50% or ≥ 50%), the patients were divided into two groups. As is shown in Table 2, the baseline diastolic/systolic velocity (D/S velocity) ratio of the abdominal aorta was significantly higher in the patients with ≥ 50% increase in the PI after stenting [0.77 (SD = 0.25) vs. 0.56 (SD = 0.09), p value = 0.013]. Additionally, the mean velocity of the descending aorta before stenting was significantly higher in the patients with aortic coarctation who had ≥ 50% increase in the post-stenting PI [1.97 (SD = 0.36) vs. 1.57 (SD = 0.56), p value = 0.033]. The other baseline echocardiographic index which was significantly different between these two groups was the mean peak gradient of the descending aorta. As is shown in Table 2, the mean peak gradient (PG) of the descending aorta at baseline was significantly higher in the patients with ≥ 50% increase in the PI after stenting [21.77 (SD = 6.43) vs. 14.57 (SD = 9.85), p value = 0.033].

More analysis was conducted to evaluate the diagnostic values of the different baseline characteristics of the patients to predict ≥ 50% increase in the PI after stenting. The significant baseline indices to differentiate the percentage of increase in the PI as < 50% or ≥ 50% are listed in Table 3. The baseline D/S ratio velocity of the abdominal aorta, mean velocity and peak gradient of the descending aorta, and baseline systolic blood pressure were the statistically significant indices to predict ≥ 50% increase in the PI in the patients with aortic coarctation (all p values < 0.05). As is illustrated in Figure 2, the baseline D/S ratio velocity of the abdominal aorta had the greatest area under curve (AUC = 0.865, p value = 0.010) to predict ≥ 50% increase in the post-stenting PI. The cut-off point of 0.67 for this index had 75% sensitivity and 100% specificity.

Table 2. Doppler echocardiographic profile in two groups of patients*

Doppler Echocardiographic Index	< 50% Increased PI Group n=6	≥ 50% Increased PI Group n=17	P value**
D/S ratio velocity of abdominal aorta	0.56±0.09	0.77±0.25	0.13
Mean velocity of descending aorta (m/s)	1.57±0.56	1.97±0.36	0.33
Mean PG of descending aorta (mmHg)	14.57±9.85	21.77±6.43	0.33

*Data are presented as mean±SD

**All P values are resulted from Mann-Whitney U-test and P values < 0.05 are considered significant

D/S, Diastolic velocity/systolic velocity; PG, Peak gradient; PI, Pulsatility index

Table 3. Predictive values of baseline indices for increase-percentage of ≥ 50% in pulsatility index after stenting

Doppler Echocardiographic Index	AUC	P value*	Cut-Point	Sensitivity	Specificity
D/S ratio velocity of abdominal aorta	0.865±0.083	0.010	>0.67	75.0% (95% CI: 47%-87%)	100% (95% CI: 61%-100%)
Mean velocity of descending aorta (m/s)	0.802±0.132	0.033	>1.62	87.5% (95% CI: 64%-96%)	83.3% (95% CI: 44%-97%)
Mean PG of descending aorta (mmHg)	0.797±0.141	0.036	>16.50	81.3% (95% CI: 57%-93%)	83.3% (95% CI: 44%-97%)
Systolic blood pressure** (mmHg)	0.795±0.128	0.050	<175.00	87.5% (95% CI: 64%-96%)	50.0% (95% CI: 19%-81%)

*All P values resulted from Receiver Operating Characteristics Curve (ROC) analysis

AUC, Area under curve; D/S, Diastolic velocity/systolic velocity; PG, Peak gradient

**reverse relationship

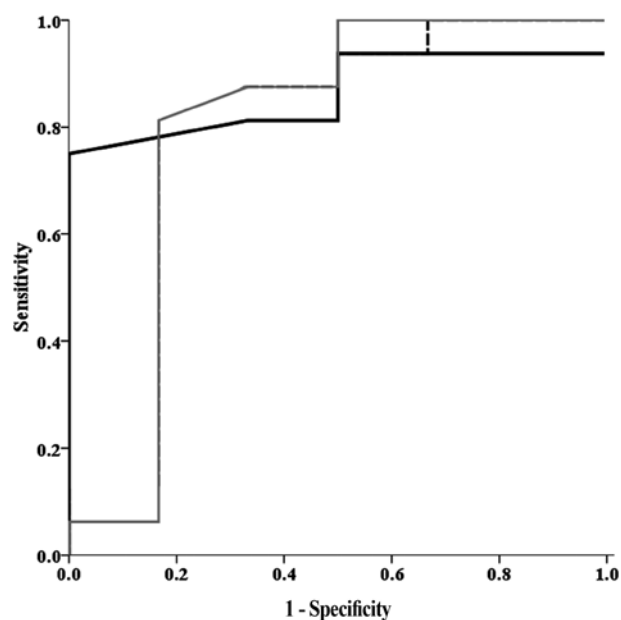


Figure 2. Receiver operative characteristics curve of baseline indices to predict the increase-percentage of pulsatility index of ≥ 50% in patients undergoing stenting (diastolic/systolic velocity ratio of abdominal aorta: black dotted, mean peak gradient of descending aorta: gray line)

Discussion

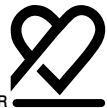Previous studies have emphasized the need for creating an available, accurate, and reliable profile which can assist in the follow-up of patients who undergo stent implantation for the treatment of aortic coarctation. To date, several non-invasive and invasive methods have been used for this purpose. However, recent years have witnessed the emergence of data demonstrating some disadvantages. For example, although Magnetic Resonance Imaging was first introduced as a

reliable modality for assessing patients after stent insertion, later it was shown that it has limitations in demonstrating the stented portion of the aorta due to artificial noising produced by the metallic stents.^{7, 8} The other mostly used modality in the follow-up of these patients is angiography, which has its known intra- and postoperative complications. By advancing echocardiography and its newly emerged branches, including Doppler echocardiography, some studies have suggested this non-invasive and available modality for assessing the feasibility of stent implantation in patients with aortic coarctation.⁹⁻¹¹ This non-invasive modality evaluates the hemodynamic changes of the aorta rather than the anatomical changes evaluated by angiography.

There are a large number of echocardiography indices which have been proven to change after the treatment of coarctation, but few of them have been found to be closely related to the clinically important hemodynamic status of the aorta. Studies on the hepatic, renal, human placental, carotid, mesenteric, and other vascular circulations have suggested that assessment of these arterial circulations can be made by evaluating the PI of the corresponding arteries.¹²⁻¹⁸ Thus, in the present study, the PI of the abdominal aorta was considered as a marker of the aortic hemodynamic status. Evaluation of this index after stenting and comparing it with baseline values can determine the efficacy of stent insertion. Also as a simple, available, and non-invasive method, it could potentially be used as a clinically useful tool in the long-term follow-up of patients.

Based on our results, impaired pulsatile systolic abdominal aortic flow is associated with impaired continuous diastolic flow in patients with significant aortic coarctation. Moreover, we found that increase in the PI following stent implantation is statistically significant. As a result, the PI of the abdominal aorta was investigated as an echocardiographic index in the early follow-up of these patients.

The other important issue regarding endovascular stent



implantation is the introduction of its indications. Numerous studies have reported several indications of stenting in coarctation. Most of these studies have defined these indications based on the complications seen in the same age groups of their study, such as femoral access problems and re-stenosis due to intimal growth, seen mostly in younger patients. It is clear that none of these indications is case-sensitive. Coarctation of the aorta is a congenital disease that has complex hemodynamic effects on each patient. Thus, it seems unreasonable to consider the same indications of stenting for all patients. In other words, none of the previous studies could introduce an assessment tool which can reliably predict the efficacy and outcome of stent implantation in each patient based on his/her own baseline hemodynamic status.

In the present study, we succeeded in defining some Doppler echocardiographic indices which are able to predict the effects of stenting on the hemodynamic status of the aorta. Four baseline (before stenting) Doppler echocardiographic indices were found to predict the increase in the PI. After sorting the patients based on the percentage of increase in their PI after stent implantation, i.e. more or less than 50%, these findings were reported: D/S ratio velocity of the abdominal aorta before treatment could be considered as a helpful index to predict the PI elevation after stenting. On the other hand, the D/S ratio before stenting was significantly different between the patients with post-PI of lower and higher than 50%. The mean velocity of the descending aorta is the other predicting index in the evaluation of stent implantation outcome based on the degree of increase in the PI. Its difference between the two groups of the PI was also statistically significant at baseline. Mean PG of the descending aorta was an index found to be a significant predictor of the PI and it varied significantly between the patients with various indices of pulsatility. Systolic blood pressure was also a helpful predictor of the PI; however, its change based on the PI was not assessed early after treatment because of the effects of postoperative stress on the blood pressure.

Conclusion

As is shown by the present study, when patients are sorted into two groups of more or less than 50% increase in the PI after stent implantation, some important echocardiographic indices differ significantly between these two groups. As a result, the PI of 50% could be a reasonable cut-off point to compare the efficacy of this intervention. In this study, the results of stent implantation were found to be predictable and the predictors were suggested to be considered as indications for this type of intervention in the treatment of coarctation. Further studies are required to evaluate the effect of the PI in the late follow-up of hemodynamic indices. Furthermore, studies comparing the degree of PI elevation after different

methods of treatment (surgery, balloon dilatation, and stenting) can be helpful in decision-making for this population of patients.

Acknowledgements

The authors would like to express their gratitude to Dr. Seifollah Abdi for his stenting of the evaluated patients. Moreover, we thank all the staff of the echocardiography ward of Rajaie Cardiovascular, Medical and Research Center.

References

1. Swan L, Goyal S, Hsia C, Hechter S, Webb G, Gatzoulis MA. Exercise systolic blood pressures are of questionable value in the assessment of the adult with a previous coarctation repair. *Heart* 2003;89:189-192.
2. Harrison DA, McLaughlin PR, Lazzam C, Connelly M, Benson LN. Endovascular stents in the management of coarctation of the aorta in the adolescent and adult: one year follow up. *Heart* 2001;85:561-566.
3. Mohan UR, Danon S, Levi D, Connolly D, Moore JW. Stent implantation for coarctation of the aorta in children <30 kg. *JACC Cardiovasc Interv* 2009;2:877-883.
4. De Mey S, Segers P, Coomans I, Verhaaren H, Verdonck P. Limitations of Doppler echocardiography for the post-operative evaluation of aortic coarctation. *J Biomech* 2001;34:951-960.
5. Pfammatter JP, Stocker FP. Quantitative echocardiographic characterization of abdominal aortic pulsatility in children with coarctation. *Pediatr Res* 1999;46:126-130.
6. Sanders SP, MacPherson D, Yeager SB. Temporal flow velocity profile in the descending aorta in coarctation. *J Am Coll Cardiol* 1986;7:603-609.
7. Hamdan MA, Maheshwari S, Fahey JT, Hellenbrand WE. Endovascular stents for coarctation of the aorta: initial results and intermediate-term follow-up. *J Am Coll Cardiol* 2001;38:1518-1523.
8. Tanous D, Collins N, Dehghani P, Benson LN, Horlick EM. Covered stents in the management of coarctation of the aorta in the adult: initial results and 1-year angiographic and hemodynamic follow-up. *Int J Cardiol* 2010;140:287-295.
9. Pfammatter JP, Berdat P, Carrel T. Impaired poststenotic aortic pulsatility after hemodynamically ideal coarctation repair in children. *Pediatr Cardiol* 2004;25:495-499.
10. Tan JL, Babu-Narayan SV, Henein MY, Mullen M, Li W. Doppler echocardiographic profile and indexes in the evaluation of aortic coarctation in patients before and after stenting. *J Am Coll Cardiol* 2005;46:1045-1053.
11. Pihkala J, Thyagarajan GK, Taylor GP, Nykanen D, Benson LN. The effect of implantation of aortic stents on compliance and blood flow. An experimental study in pigs. *Cardiol Young* 2001;11:173-181.
12. Ray-Chaudhuri K, Ryder SA, Thomaides T, Mathias CJ. The relationship between blood flow and pulsatility index in the superior mesenteric artery at rest and during constrictor stimuli in normal subjects. *J Clin Ultrasound* 1994;22:149-160.
13. Petersen LJ, Petersen JR, Talleruphuus U, Ladefoged SD, Mehlsen J, Jensen HA. The pulsatility index and the resistive index in renal arteries. Associations with long-term progression in chronic renal failure. *Nephrol Dial Transplant* 1997;12:1376-1380.
14. Schneider AW, Kalk JF, Klein CP. Hepatic arterial pulsatility index in cirrhosis: correlation with portal pressure. *J Hepatol* 1999;30:876-881.



15. Fong KW, Ohlsson A, Hannah ME, Grisaru S, Kingdom J, Cohen H, Ryan M, Windrim R, Foster G, Amankwah K. Prediction of perinatal outcome in fetuses suspected to have intrauterine growth restriction: Doppler US study of fetal cerebral, renal, and umbilical arteries. *Radiology* 1999;213:681-689.
16. Piscaglia F, Gaiani S, Gramantieri L, Zironi G, Siringo S, Bolondi L. Superior mesenteric artery impedance in chronic liver diseases: relationship with disease severity and portal circulation. *Am J Gastroenterol* 1998;93:1925-1930.
17. Snider AR. The use of Doppler ultrasonography for the evaluation of cerebral artery flow patterns in infants with congenital heart disease. *Ultrasound Med Biol* 1985;11:503-514.
18. Maulik D, Yarlagadda AP, Youngblood JP, Willoughby L. Components of variability of umbilical arterial Doppler velocimetry--a prospective analysis. *Am J Obstet Gynecol* 1989;160:1406-1409.