



# Off-Pump Coronary Bypass Grafting Causing Stunned Myocardium

Feridoun Sabzi, MD\*, Naser Hemati, MD, Abdoul Hamid Zokaei, MD, Gholamreza Moradi, MD, Samsam Dabiri, MD

Imam Ali Heart Center, Kermanshah University of Medical Sciences, Kermanshah, Iran.

Received 19 April 2011; Accepted 05 September 2011

## Abstract

The term “stunned myocardium” refers to abnormalities in the myocardial function following reperfusion and is common in on-pump coronary artery bypass grafting (CABG) and is exceedingly rare in off-pump CABG. A 53-year-old man presented with unstable angina due to the severe stenosis of the left anterior descending coronary artery (LAD) and the obtuse marginal. Laboratory findings and Chest X-ray revealed nothing abnormal. The intraoperative course was uneventful. The patient left the operating room without any inotropic support. Six hours later, however, he developed low cardiac output. At exploration, cardiac tamponade was excluded and flowmetry showed that the graft had adequate function. Cardiac enzymes were normal. High-dose adrenalin and Dobutamine were administrated and an intra-aortic balloon pump was used. After hemodynamic stabilization, the patient left the Intensive Care Unit without an intra-aortic balloon pump and inotropic support. On the fifth postoperative day, coronary angiography showed patent grafts and correct anastomotic sites. On the seventh postoperative day, the akinetic lateral wall of the left ventricle changed to dyskinesia. Finally after hospital discharge on the thirtieth postoperative day, an echocardiogram showed normal left ventricular function without regional wall motion abnormalities.

*J Teh Univ Heart Ctr* 2012;7(3):143-146

**This paper should be cited as:** Sabzi F, Hemati N, Zokaei AH, Moradi G, Dabiri S. Off-Pump Coronary Bypass Grafting Causing Stunned Myocardium. *J Teh Univ Heart Ctr* 2012;7(3):143-146.

**Keywords:** Coronary artery bypass grafting, off-pump • Post-operative complication • Myocardial stunning

## Introduction

The terms “stunned myocardium” and “hibernating myocardium” refer to abnormality in the systolic and diastolic function of the heart following reperfusion.<sup>1</sup> In both abnormalities, myocardial contractility and relaxation are deteriorated, while the cardiac enzymes are still viable.<sup>2</sup> In the hibernating myocardium, however, a programmed cell death (apoptosis) pattern has been described. Myocardial ischemia results in the utilization of adenosine triphosphate ATP stores secondary to the paralysis of aerobic metabolism

and oxidative phosphorylation.<sup>3</sup>

Stunning was defined by Braunwald as post-ischemic cardiac dysfunction of viable myocardium.<sup>4</sup> Clinical myocardial stunning was first reported by Bolli and Klonar, who separately characterized its experimental models. Stunning has been documented in post-percutaneous coronary intervention and thrombolytic therapy for coronary artery stenosis<sup>5,6</sup> and also in the wake of cardiopulmonary bypass (CPB).<sup>6,7</sup>

One of the technical challenges in off-pump coronary artery bypass grafting surgery (OPCAB) is myocardial

\*Corresponding Author: Feridoun Sabzi, Associate Professor of Cardiac Surgery, Kermanshah University of Medical Sciences, Imam Ali Hospital, Shaheed Beheshti Ave, Kermanshah, Iran. Tel: +98 918 1311896. Fax: +98 831 8360043. Email: dr\_Sabzi@yahoo.com.

ischemia caused by the proximal and distal snaring of the coronary artery, which gives rise to post-ischemic ventricular dysfunction.<sup>8</sup> Nonetheless, the occurrence of myocardial stunning in this setting has yet to be fully investigated. We herein report the case of a patient who developed temporary left ventricular dysfunction after an OPCAB procedure.

## Case Report

A 53-year-old man presented with unstable angina due to the severe stenosis of the left anterior descending coronary artery and obtuse marginalis, although the right coronary artery was normal. Laboratory findings, including a complete blood count, erythrocyte sedimentation rate, and C reactive protein, were normal. Chest X-ray revealed no abnormal findings, and there was no valvular abnormality on preoperative echocardiography. The patient had no comorbid disorders, but his left ventricular ejection fraction was reduced (40-45%).

The intraoperative course was uneventful. There were no findings of pericarditis. On physical examination, there was no respiratory distress, blood pressure was 130/80 mm Hg, heart rate was 80 beats per minute, respiratory rate was 23 per minute, the neck veins were not distended, and there was no ankle edema. Cardiovascular system examination showed regular first and second heart sounds with no gallop or murmur. The electrocardiogram (ECG) demonstrated a Q wave in the precordial leads. For temporary coronary artery occlusion, 4/0 Viline sutures and a Bulldog Clamp were used, and warm blood was employed to de air the graft. Temporary coronary artery occlusion was not prolonged, and the electrocardiogram and hemodynamic variables and objective data showed no signs of ischemia or contractile dysfunction. The operation was uneventful. No intra-coronary shunt was utilized.

The patient left the operating room without any inotropic support. Six hours later, however, he developed low cardiac output. At exploration, cardiac tamponade was excluded and flowmetry showed that the graft had adequate function. There were no findings as regards pericarditis, and the patient's postoperative erythrocyte sedimentation rate, C-reactive protein, and cardiac enzymes were normal. A high dose of adrenalin and dobutamine was administered, and an intra-aortic balloon pump was used.

Intraoperative transesophageal echocardiography demonstrated a depression in the left ventricular function due to an akinetic lateral left ventricular wall in the region of the obtuse marginalis. After hemodynamic stabilization, the patient left the Intensive Care Unit without an intra-aortic balloon pump and inotropic support. On the fifth postoperative day, a coronary angiogram demonstrated patent grafts and correct anastomotic sites (Figure 1 & 2). On the seventh postoperative day, the akinetic lateral wall

of the left ventricle changed to dyskinesia. Finally, after hospital discharge on the thirtieth postoperative day, an echocardiogram showed a normal left ventricular function without regional wall motion abnormalities.

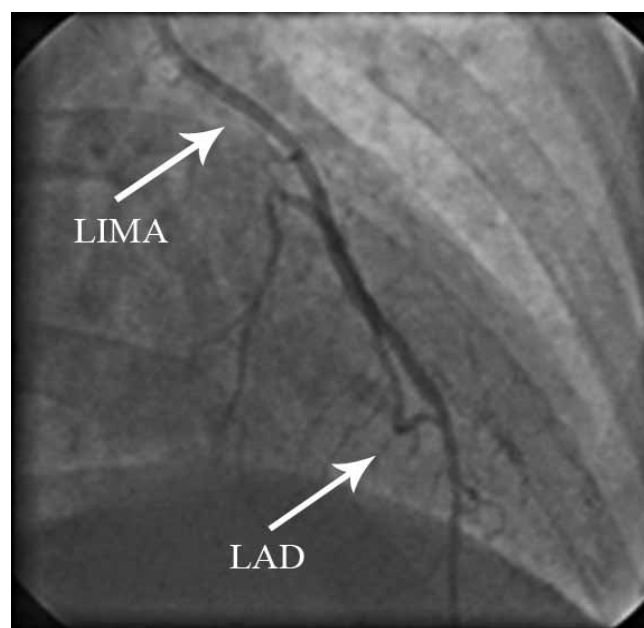


Figure 1. Anteroposterior (AP) coronary angiography view showing patent left internal mammary artery (LIMA) to left anterior descending artery (LAD)

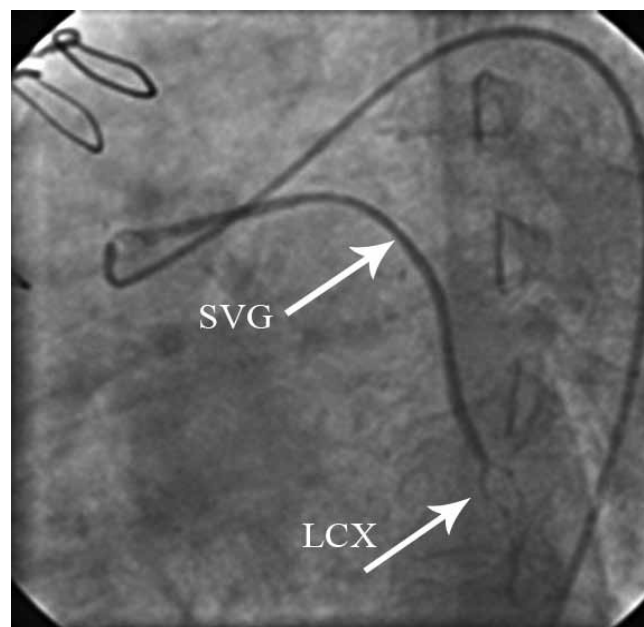
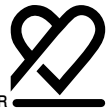

Figure 2. Left lateral coronary angiography view showing patent saphenous vein graft (SVG) to left circumflex coronary artery (LCX)

## Discussion

CPB may contribute to the mortality and cost associated



with CABG.<sup>9</sup> Recently, OPCAB has emerged as an alternative technique allowing coronary revascularization without the need for CPB.

We have performed 300 consecutive OPCAB procedures in our hospital over the years. In the case reported in this paper, the anesthesia protocol was comprised of a combination, of Fentanyl and Pancuronium Bromide, supplemented with Isoflurane and nitrous oxide, to permit early extubation. An arterial and central venous line was utilized as is the standard in this modality. OPCAB was performed through a sternotomy incision. Conduits for CABG, including the left internal mammary artery and saphenous vein, were harvested in the standard fashion. Deep pericardial traction sutures were placed to facilitate elevation of the apex of the heart and exposure of the lateral wall of the myocardium. The right pleural space was opened routinely to allow displacement of the heart to facilitate the exposure of the circumflex artery. Revascularization on the left anterior descending artery with the left internal mammary was typically performed first, followed by revascularization of the left circumflex artery and the right coronary artery distribution. To assist further in providing good presentation of the target arteries, especially the posterior and inferior walls, the patient was placed in a right lateral decubitus trendelenburg position.

An optimal combination of pharmacological and mechanical methods was drawn upon to reduce the coronary artery movement. In addition, intravenous Esmolol was used to reduce the heart rate. Stabilization of the target arteries was accomplished with an Octopus Stabilizer (Medtronic, Ts 300). Intravenous heparin (1 mg/kg) was given to maintain activated clotting time (ACT) between 200 and 300 seconds. The target coronary artery was occluded proximal and distal to the proposed arteriotomy site by widely placing double-looped 4-0 Viline sutures. These sutures were snuggled and arteriotomy was made. No technique was performed for preconditioning of the myocardium.

Distal coronary anastomosis was performed using a running 7-0 monofilament Viline suture. Proximal anastomosis to the aorta was made on a punch aortotomy after applying a side clamp to the ascending aorta. Visualization of the anastomosis was enhanced with the use of humidified carbon dioxide blower. Before the application of the Octopus Stabilizer, Amiodarone and Esmolol were administered to the patient and communication with the anesthesia team was maintained to monitor changes in the patient's hemodynamic and to treat cardiac arrhythmias. After distal anastomosis, proximal anastomoses were carried out on the ascending aorta with a partially occluding clamp.

After surgery, the patient was admitted to the Intensive Care Unit. Serial electrocardiograms and estimation of serum creatinine phosphokinase and its MB fraction were done to detect perioperative ischemia. Ventricular dysfunction developed postoperatively in 2 patients, and 2 patients developed severe left ventricular dysfunction due to the poor

quality of the anastomotic site of the left internal mammary artery to the left anterior descending coronary artery graft. Although the anastomotic site was revised, myocardial infarction occurred. In one patient, intraoperative flowmetry demonstrated normal graft flow and cardiac enzymes were not significantly elevated and postoperative angiography showed patent bypass graft and good quality of the anastomotic sites. (figure 1 and 2) Because the bypass grafts were patent, the only ischemic event that would have caused left ventricular dysfunction was temporary occlusion of the coronary arteries. The left ventricular dysfunction recovered completely within thirty days.

We think that post-ischemic contractile dysfunction of the left ventricle has its pathophysiological background in myocardial stunning. The best approach in the postoperative period is to support the acutely failing heart by inotropic drugs and intra-aortic balloon pumps. Alkholaifie reported that ultimate objective must be to prevent ventricular dysfunction by ischemic preconditioning, which could be achieved by repetitive short-time occlusion and reperfusion of the coronary vessel.<sup>9</sup> Grubitzsch did not observe segment depression or elevation after coronary artery occlusion in his patients, which usually indicates the necessity of preconditioning.<sup>8</sup> In contrast, Mulkowski, in a clinical setting of OPCAB, showed that transient ischemia did not limit subsequent ischemic regional dysfunction.<sup>10</sup> This controversy in the management of post-operative left ventricular dysfunction with patent bypass graft led to this recommendation by Rivetti that the use of the intra-coronary shunt must be considered if the duration of temporary coronary artery occlusion exceeds fifteen minutes.<sup>11</sup>

## Conclusion

Recently, OPCAB has emerged as an alternative technique allowing coronary revascularization without the use of CPB. Because OPCAB is associated with temporary myocardial ischemia, there is a risk of ischemia-related complications. We think that the most important issue in performing OPCAB is the short ischemia time.

## References

1. Kloner RA. Does reperfusion injury exist in humans? *J Am Coll Cardiol* 1993;21:537-545.
2. Hansen PR. Myocardial reperfusion injury: experimental evidence and clinical relevance. *Eur Heart J* 1995;16:734-740.
3. Puskas JD, Vinten-Johansen J, Muraki S, Guyton RA. Myocardial protections for off-pump coronary artery bypass surgery. *Semin Thorac Cardiovasc Surg* 2001;13:82-88.
4. Braunwald E, Kloner RA. The stunned myocardium: prolonged, postischemic ventricular dysfunction. *Circulation* 1982;66:1146-1149.
5. Bolli R. Myocardial 'stunning' in man. *Circulation* 1992;86:1671-1691.



6. Kloner RA, Przyklenk K, Kay GL. Clinical evidence for stunned myocardium after coronary artery bypass surgery. *J Card Surg* 1994;9:397-402.
7. Sabzi F, Molodi A. Locked-in syndrome and blue toe syndrome caused by cardiopulmonary bypass. *J Teh Univ Heart Ctr* 2010;5:150-152.
8. Grubitzsch H, Ansorge K, Wollert HG, Eckel L. Hemodynamic monitoring in patients undergoing off-pump coronary artery bypass graft surgery using the octopus tissue stabilizer: left atrial pressure as a gold standard. *J Cardiothorac Vasc Anesth* 2000;14:105-106.
9. Alkhulaifi AM, Jenkins DP, Pugsley WB, Treasure T. Ischaemic preconditioning and cardiac surgery. *Eur J Cardiothorac Surg* 1996;10:792-798.
10. Malkowski MJ, Kramer CM, Parvizi ST, Dianzumba S, Marquez J, Reichek N, Magovern JA. Transient ischemia does not limit subsequent ischemic regional dysfunction in humans: a transesophageal echocardiographic study during minimally invasive coronary artery bypass surgery. *J Am Coll Cardiol* 1998;31:1035-1039.
11. Rivetti LA, Gandra SM. Initial experience using an intraluminal shunt during revascularization of the beating heart. *Ann Thorac Surg* 1997;63:1742-1747.