

Anatomy of Atrioventricular Node Artery and Pattern of Dominancy in Normal Coronary Subjects: A Comparison between Individuals with and without Isolated Right Bundle Branch Block

Ali Kazemisaeid, MD, Marziyeh Pakbaz, MD*, Ahmad Yaminisharif, MD, Gholamreza Davoodi, MD, Masoumeh Lotfi Tokaldany, MD, Elham Hakki Kazazi, MD

Tehran Heart Center, Tehran University of Medical Sciences, Tehran, Iran.

Received 24 December 2011; Accepted 20 May 2012

Abstract

Background: Isolated right bundle branch block (RBBB) is a common finding in the general population. The atrioventricular node (AVN) artery contributes to the blood supply of the right bundle branch. Our hypothesis was that the anatomy of the AVN artery and the pattern of dominancy differ between subjects with and without RBBB.

Methods: We retrospectively studied the coronary angiography of 92 patients with RBBB and 184 age- and gender-matched controls without RBBB. All the subjects had angiographically proven normal coronary arteries. The dominant circulation and precise origin of the AVN artery were determined in each subject. Obtained data were compared between the two study groups.

Results: There was no significant difference between the two groups in terms of dominancy (p value = 0.200). Origination of the AVN artery from the right circulatory system was more common in both groups, but this pattern was more prevalent in the cases than in the controls (p value = 0.021). There was a great variation of the AVN artery origin. In the total study population, the AVN artery was more commonly separated from a non crux origin than from the crux area. The prevalence of the non-crux origination of the AVN artery was significantly higher in the cases than in the controls (p value < 0.001). While the origination of the AVN artery from the right circulatory system was more common in both groups, the prevalence of the right origin of the AVN artery was significantly higher in the cases than in the controls. We observed that the AVN artery most commonly originated from the dominant artery but not necessarily from the crux.

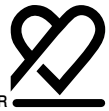Conclusion: The anatomy of the AVN artery but not the pattern of dominancy is somewhat different in subjects with RBBB compared with normal individuals.

J Teh Univ Heart Ctr 2012;7(4):164-169

This paper should be cited as: Kazemisaeid A, Pakbaz M, Yaminisharif A, Davoodi G, Lotfi Tokaldany M, Hakki Kazazi E. Anatomy of Atrioventricular Node Artery and Pattern of Dominancy in Normal Coronary Subjects; A Comparison Between Individuals With and Without Isolated Right Bundle Branch Block. *J TehUniv Heart Ctr 2012;7(4):164-169.*

Keywords: Anatomy • Coronary vessels • Bundle-branch block

*Corresponding Author: Marziyeh Pakbaz, Department of Cardiology, Tehran University of Medical Sciences, Tehran Heart Center, North Kargar Street, Tehran, Iran.1411713138. Tel: +98 21 88029256. Fax: +98 21 88029256. E-Mail: marzi.pakbaz@gmail.com.



Introduction

The atrioventricular node (AVN) is an area of specialized tissue between the atria and the ventricles of the heart and specifically acts as an electrical relay station for electrical impulses, passing from the atria to the ventricles. The arterial blood supply of the AVN, which is quite variable, was the topic of anatomic, histologic, and radiologic research for many years. The origin of the blood supply to the conduction system is highly relevant to the clinical symptoms and surgical procedures.¹ Recognition of the anatomical variants of the arterial blood supply to the AVN may help overcome potential complications following ablation procedures or in mitral valve surgery.

Isolated right bundle branch block (RBBB) is a common finding in the general population. RBBB may be associated with structural heart disease but many subjects with this conduction abnormality have no evidence of underlying heart disease.^{2, 3} The blood supply to the proximal part of the right bundle branch is provided by the left anterior descending artery (LAD) or the AVN artery, and the distal part is mainly supplied by branches from the LAD.⁴

With regard to the contribution of the AVN artery to the blood supply of the right bundle branch, we postulated that RBBB may be associated with anatomical variations in the AVN artery. The aim of this study was to investigate the origin of the AVN artery in patients with isolated RBBB and to compare it with normal electrocardiogram individuals.

Methods

This case control study was conducted enrolling patients with normal coronary arteries or mild coronary artery disease who underwent coronary angiography between 2001 and 2010 in Tehran Heart Center. Demographic features, coronary risk factors, drug history, history of cardiac events, electrocardiographic interpretation, echocardiographic findings, past history of coronary or any other type of intervention and open heart surgery, and the result of coronary angiography were drawn out of the computerized angiography database of Tehran Heart Center. Patients eligible for inclusion were men and women at least 20 years of age with documented RBBB on the surface electrocardiogram, mild or normal coronary arteries proven by angiography, and a normal ejection fraction (more than 50%). Major exclusion criteria included the presence of conduction abnormalities other than RBBB, history of using drugs affecting the heart conduction system such as beta adrenergic receptor blockers and antiarrhythmic agents, significant valvular heart disease (more than mild regurgitation or stenosis of any valve) on echocardiography study, and congenital or acquired structural heart disease that could be an etiology for developing RBBB such as atrial septal defect, ventricular septal defect, and

pulmonary thromboembolism. Case selection was done with convenience non-probability sampling. Initially, 141 patients were selected from the angiography database. Subsequently, the hospital records of these patients, including the history of symptoms, further evaluation of the electrocardiogram, echocardiographic findings, and coronary angiography report sheets, were reviewed in detail. First, the electrocardiogram and records were selected for further study if the electrocardiogram satisfied the criteria previously defined for typical RBBB by the World Health Organization and the International Society and Federation for Cardiology in 1985, as follows: 1) prolongation of QRS to 0.12 second or more; 2) an rsr' , rsR' , or rSR' pattern and occasionally a wide and notched R pattern in lead V_1 or V_2 ; 3) an S wave duration longer than the R wave duration or greater than 40 ms in leads V_6 and I; and 4) an R peak time greater than 0.05 second in lead V_1 but normal in leads V_5 and V_6 .⁵

Of these criteria, the first three should be present for the diagnosis to be made. When a notched dominant R pattern is present in V_1 , criterion 4 should be satisfied as well.

Of the initial 141 patients selected, 49 subjects who did not meet the inclusion criteria were excluded. Finally, a total of 92 subjects were entered for final analysis. Control subjects, who underwent coronary angiography during the same period, were randomly extracted from the angiography database. The controls were matched by age and sex to the cases with a 2:1 ratio. Inclusion criteria other than electrocardiography findings were the same as those of the cases. For each group, the coronary angiography recorded on CDs was studied to determine the pattern and characteristics of the coronary anatomy and the origination of the AVN artery. The dominant circulation was also determined.

The classification described by Popma JJ was used in the present study to define the dominant coronary circulation⁶: a) in a right dominant circulation, the posterior descending artery (PDA) and at least one posterolateral branch (PLB) originate from the right coronary artery (RCA); b) in a left dominant circulation, the PDA and all of the PLBs originate from the left coronary artery; and c) In a co-dominant circulation, the PDA originates from the RCA and all of the PLBs originate from the left coronary artery.

In order to determine the origin of the AVN artery, the dominant artery was ascertained. Based on the knowledge that the AVN artery most commonly originates from the crux,⁷ if a branch to the AVN region originated from the dominant artery at the area of the crux, it was considered the AVN artery. If such a branch was not detected, other segments of the dominant artery and thereafter the non-dominant artery were evaluated in multiple views. At the end, the origin of the AVN artery was classified to be from the right, left, or dual circulation (if both circulatory systems gave rise to the AVN blood supply). If the AVN artery was not originated from the crux, we determined the specific

artery giving rise to it.

Statistical analysis was performed using SPSS version 15.0 software. Results for the quantitative variables were reported as mean ± standard deviation and as frequencies for the qualitative variables. The mean values of the quantitative variables of the two study groups were compared using the Student t-test. The frequency distributions of the qualitative variables, obtained from the two study groups, were compared using the chi-square test. A p value ≤ 0.05 was considered a statistically significant difference.

Results

A total of 276 patients were involved, and 92 (33.3%) and 184 (66.7%) subjects were grouped as cases and controls, respectively. The mean age for the case group (59.8% male) was 59.19 ± 10.93 years and for the controls (62.5% male) 59.29 ± 10.94 years. In terms of dominancy, there was no significant difference between the study groups (p value = 0.200). Also, 75.0% of the cases versus 76.6% of the controls had right dominant, 12.0% of the cases versus 16.3% of the controls had left dominant, and 13.0% of the cases versus 7.1% of the controls had co-dominant circulations (Figure 1). By comparison, in terms of dominancy, there was no significant difference between the study groups.

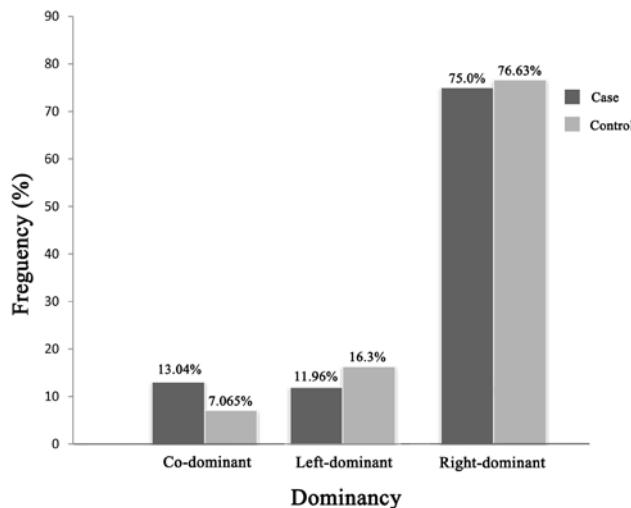


Figure 1. Comparison between the cases (individuals with right bundle branch block) and controls (individuals without right bundle branch block), showing the frequency of the distribution of the types of dominancy

In the evaluation of the AVN artery origin, we determined whether it was originated from the right or left or whether it had a dual origin, whether or not it was from the crux. Furthermore, we determined the specific artery, from which the AVN artery branched (Tables 1 and 2). The crux was defined as the U-turn segment of the dominant artery.

Of the total study population, the AVN origin was from

the crux in 106 (38.4%) and from a non-crux origin in 169 (61.2%) subjects (Table 1).

Table 1. Variations of the AVN origin artery in the total study population

Origin of AVN artery	Number of subjects
Undetermined	1
Crux	106
Non-crux origins	169
Dual origin	
PLB and distal of LCX	2
OM and distal of RCA	1
Origin from LCX	
Distal of LCX	3
Mid-part of LCX	1
Origin from OM	40
Origin from RCA	
Conus	3
Proximal of RCA	7
Distal of RCA	24
Posterior descending artery	2
Posterolateral branch	85
Origin from Ramus	1
Total	276

AVN, Atrioventricular node; LCX, Left circumflex artery; RCA, Right coronary artery; OM, Obtuse marginal artery

In one patient, the AVN origin was undetermined, probably because it was too small to be visualized. Only a minority of the patients had an AVN artery with a dual origin (2 of the cases and one of the controls), as is shown in Table 1.

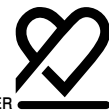These special cases were omitted from the subsequent analysis of the AVN origin because of the very small number of such cases. The results after such an adjustment are depicted in Table 2.

Table 2 illustrates that origination of the AVN artery from a non-crux origin was more common than origination from the crux in both groups. The prevalence of the non-crux origination of the AVN artery was significantly higher in the cases than in the controls (79.8% vs. 51.4%, respectively; p value < 0.001).

Although origination from the right circulatory system was more common in both groups (82.0% of the cases and 68.9% of the controls), the prevalence of the right origin of the AVN artery was significantly higher in the cases than in the controls (p value = 0.021) (Table 2).

A more detailed comparison of the AVN artery origin between the cases and controls is illustrated in Figure 2.

The most common origin of the AVN artery was the crux in the controls and the PLB in the cases when considering the frequency of the different non-crux origin variations of the AVN artery separately. Nevertheless, by integrating these



subtypes and considering the single variant of the “non-crux origin of the AVN artery”, it became more common than the crux origin even slightly in the controls.

We analyzed the association between the origin of the AVN artery and the type of dominancy in the whole study population and observed that the AVN artery most commonly originated from the dominant artery. In the case of the co-dominant circulation, it most commonly originated from the right circulation (Table 3).

Table 2. Comparison of the AVN artery origin in individuals with right bundle branch block (cases) and individuals without right bundle branch block (controls)*

AVN artery origin	Total n=272	Case n=89	Control n=183	P value**
Left	73 (26.8)	16 (18.0)	57 (31.1)	0.021
Right	199 (73.2)	73 (82.0)	126 (68.9)	
Crux	107 (39.3)	18 (20.2)	89 (48.6)	< 0.001
Non-crux	165 (60.7)	71 (79.8)	94 (51.4)	

*Data are presented as n (%)

**Case vs. Control

AVN, Atrioventricular node




Figure 2. Frequency of the AVN artery origin in cases (individuals with right bundle branch block) and controls (individuals without right bundle branch block)

AVN, Atrioventricular node; CX, Left circumflex artery; OM, Obtuse marginal artery; PDA, Posterior descending artery; PLB, Posterolateral branch artery; RCA, Right coronary artery

Table 3. Association of the AVN artery origin with dominancy

Dominancy	Origin of the AVN artery	
	from right circulation	from left circulation
Right dominant	87.9%	12.1%
Left dominant	7.5%	92.5%
Co-dominant	60.0%	40.0%

AVN, Atrioventricular node

Discussion

The findings of the present study suggest that there is no relationship between the dominancy of the epicardial arteries and the presence of RBBB in subjects with normal coronary arteries. There was a great variation of the AVN artery origin among all the study subjects. In the total study population and also in each group, the AVN artery was more commonly separated from a non-crux origin than from the crux (61.2% versus 38.4%); this is in contrast to the conventional wisdom.⁷ The prevalence of the non-crux origination of the AVN artery was significantly higher in the cases than in the controls. A dual artery supply of the AVN was a rare variation, only observed in 0.01% of the subjects. While the origination of the AVN artery from the right circulatory system was more common in both groups, the prevalence of the right origin of the AVN artery was significantly higher in the cases than in the controls. Finally, we observed that the AVN artery most commonly originated from the dominant artery but not necessarily from the crux.

To this date, there has been no previous study aiming to specifically compare anatomic variations in the AVN artery in subjects with RBBB versus subjects with normal surface electrocardiograms.

Table 4 represents the results of the previous studies that investigated the AVN artery origin.⁸⁻¹⁴ All the studies showed that the AVN artery originated most commonly from the RCA, which was the most common dominant system. This led to the conclusion that the AVN artery usually branched from the dominant artery. However, this was not always the case as we observed some cases of the origination of the AVN artery from the non-dominant artery. These out-of-the-rule variants were more commonly seen in the control group (15% of the controls versus 1% of the cases and 10% of the total study population). The results of the current study with regard to this variable were very close to the results of Ramanathan and his colleagues’ angiography-based study on an Indian population and somewhat different from other studies, suggesting that race might be a potential factor influencing the anatomic variables of the coronary artery.¹⁴ Three per cent of the total population investigated by Ramanathan et al., showed origination of the AVN artery from the non-dominant artery.

Pejković B et al., in an anatomic study of 150 human hearts, found that the artery supplying the AVN arose most frequently from the U- or V-shaped segment of the right (90%) or left (10%) coronary artery termed the ‘U-turn’ at the level of the crux.¹⁵ Differently in our study, the AVN artery was more commonly separated from a non-crux origin than from the crux (61.2% versus 38.4%). In 72.1% of the subjects, it was a branch from the right circulation and in 26.4% from the left circulation. In line with our observation, Pejkovic B et al., also showed that the AVN artery origin depended on topographic

arterial dominance: in cases with right or balanced arterial coronary vascularization, the AVN artery was a branch of the RCA, and in cases of left dominance the left coronary artery gave a branch to the AVN.¹⁵

Dual supply of the AVN was a rare variation in the present sample of individuals. Such a dual supply has been described in the literature previously.^{8, 10, 12-14, 16, 17} The co-dominant circulation seems not to be related to the dual arterial blood supply of the AVN insofar as in our study none of the 3 patients with dual supply were co-dominant (one was left-dominant and the other 2 were right-dominant).

Rusu MC et al., in an anatomic study of 50 human hearts, described five morphological types (each with distinctive subtypes) of the AVN artery: 1) type I (22%, the AVN artery from the U-turn of the RCA); 2) type II (18%, the AVN artery from the PDA); 3) type III (34%, the AVN artery from the PLB); 4) type IV (8%, the AVN artery from the bifurcation of the RCA into the PDA and the PLB-trifurcated RCA); and 5) type V (18%, the AVN artery from the circumflex artery).¹⁸ According to this type of classification, in our total study population the prevalence of each subtype was as follows: 38.4% type I; 0.7% type II; 30.8% type III; 8.6% type IV; and 1.4% type V. We also observed additional subtypes such as origination from the OM, conus, proximal part of the RCA and ramus in 14.5%, 1.1%, 2.5%, and 0.3% of the subjects, respectively. Similar to the Russu study, the separation of the AVN artery from a non-crux origin was more common than that from the crux. Also in both studies, the most common non-crux origin of the AVN artery was from the PLB. The least common subtype in our study was origination from the PDA (and also ramus), in contrast to the Russu study, in which origination from the PDA was a common variation.

By comparing the two study groups in our investigation, as is shown in Figure 2, this conclusion could be readily made that the origin of the AVN artery differed in the subjects with RBBB and those without RBBB.

Conclusion

Table 4. Origin of the AVN artery reported by various authors

Author	Study date	Sample size	Origin of AVN artery (%)		
			RCA	LCX	Dual
Vieweg et al.	1975	118	84	8	8
Hutchison	1978	40	80	20	-
Hadziselimović	1978	200	85	13	2
Krupa	1993	120	90	10	-
Futami et al.	2003	30	80	10	10
Saremietal	2008	102	87	11	2
Ramanathan et al.	2009	300	72	28	0
The present study	2011	276	72.1	26.4	1.1

AVN, Atrioventricular node; RCA, Right coronary artery; LCX, Left circumflex artery

According to our observations, there was no relationship between the dominance of the epicardial arteries and the presence of RBBB in subjects with normal coronary arteries. There was a great variation of the AVN artery origin. Non-crux origination of the AVN artery was more common than the crux origination in both groups, and the prevalence of non-crux origination of the AVN artery was significantly higher in the cases than in the controls. Origination of the AVN artery from the right circulatory system was more common in both groups and the prevalence of the right origin of the AVN artery was significantly higher in the cases than in the controls. The AVN artery most commonly originated from the dominant artery but not necessarily from the crux.

Acknowledgment

This study was approved and supported by Tehran University of Medical Sciences.

References

1. Abuin G, Nieponice A. New findings on the origin of the blood supply to the atrioventricular node. Clinical and surgical significance. *Tex Heart Inst J* 1998;25:113-117.
2. Knilans TK. Right bundle branch block. In: Surawicz B, ed. *Chou's Electrocardiography In Clinical Practice*. 6th ed. Philadelphia: Saunders; 2008. p. 99-100.
3. Mirvis DM, Goldberger AL. Electrocardiography. In: Bonow RO, Mann DL, Zipes DP, Libby P, Braunwald E, eds. *Braunwald's Heart Disease, A Textbook of Cardiovascular Medicine*. 9th ed. Philadelphia: Saunders; 2011. p. 146-147.
4. Stambler BS, Rahimtoola SH, Ellenbogen KA. Pacing for atrioventricular conduction system disease. In: Ellenbogen KA, Kay GN, eds. *Clinical Cardiac Pacing, Defibrillation, and Resynchronization Therapy*. 3rd ed. Philadelphia: Saunders; 2007. p. 429-430.
5. Willems JL, Robles de Medina EO, Bernard R, Coumel P, Fisch C, Krikler D, Mazur NA, Meijler FL, Mogensen L, Moret P. Criteria for intraventricular conduction disturbances and pre-excitation. World Health Organization/International Society and Federation for Cardiology Task Force Ad Hoc. *J Am Coll Cardiol* 1985;5:1261-1275.
6. Pompa JJ. Coronary arteriography. In: Bonow RO, Mann DL,



- Zipes DP, Libby P, Braunwald E, eds. Braunwald's Heart Disease, A Textbook of Cardiovascular Medicine. 9th ed. Philadelphia: Saunders; 2011. p. 406-440.
7. Rubart M, Zipes DP. Genesis of cardiac arrhythmias: electrophysiologic considerations. In: Bonow RO, Mann DL, Zipes DP, Libby P, Braunwald E, eds. Braunwald's Heart Disease, A Textbook of Cardiovascular Medicine. 9th ed. Philadelphia: Saunders; 2011. p. 653-686.
 8. Vieweg WV, Alpert JS, Hagan AD. Origin of the sinoatrial node and atrioventricular node arteries in right, mixed, and left inferior emphasis systems. *Cathet Cardiovasc Diagn* 1975;1:361-373.
 9. Hutchinson MC. A study of the atrial arteries in man. *J Anat* 1978;125:39-54.
 10. Hadziselimović H. Vascularization of the conducting system in the human heart. *Acta Anat (Basel)* 1978;102:105-110.
 11. Krupa U. The atrioventricular nodal artery in the human heart. *Folia Morphol (Warsz)* 1993;52:G1-9.
 12. Futami C, Tanuma K, Tanuma Y, Saito T. The arterial blood supply of the conducting system in normal human hearts. *Surg Radiol Anat* 2003;25:42-49.
 13. Saremi F, Abolhoda A, Ashikyan O, Milliken JC, Narula J, Gurudevan SV, Kaushal K, Raney A. Arterial supply to sinoatrial and atrioventricular nodes: imaging with multidetector CT. *Radiology* 2008;246:99-107.
 14. Ramanathan L, Shetty P, Nayak SR, Krishnamurthy A, Chettiar GK, Chockalingam A. Origin of the sinoatrial and atrioventricular nodal arteries in South Indians: an angiographic study. *Arq Bras Cardiol* 2009;92:314-319.
 15. Pejčković B, Krajnc I, Anderhuber F, Kosutić D. Anatomical aspects of the arterial blood supply to the sinoatrial and atrioventricular nodes of the human heart. *J Int Med Res* 2008;36:691-698.
 16. Krauss D, Carter JE, Jr, Feldman T. Anomalous connection between the sinus node artery and the A-V node artery. *Cathet Cardiovasc Diagn* 1993;29:236-239.
 17. James TN, Burch GE. The atrial coronary arteries in man. *Circulation* 1958;17:90-98.
 18. Rusu MC, Ferechide D, Curca GC, Dermengiu D. Morph functional considerations on the atrioventricular node arterial vascularization. *Rom J Leg Med* 2009;17:101-110.