



# Radiofrequency Ablation of Accessory Pathways in Children with Complex Congenital Cardiac Lesions: A Report of Three Cases

Mohammad Dalili, MD<sup>\*1</sup>, Jayakeerthi Y Rao, MD<sup>2</sup>, Pedro Brugada, MD<sup>2</sup>

<sup>1</sup>Rajaie Cardiovascular, Medical and Research Center, Iran University of Medical Sciences, Tehran, Iran.

<sup>2</sup>Heart Rhythm Management Center, Universitair Ziekenhuis Brussels – Vrije Universiteit Brussel, Brussels, Belgium.

Received 07 August 2012; Accepted 15 October 2012

## Abstract

Catheter ablation is an accepted, highly effective modality of treatment for cardiac arrhythmias in children. The success rate depends on the operator's experience, especially in cases involving complex anatomies. We hereby report our recent experience of successful ablation of accessory pathways in three children with complex congenital heart diseases.

The first case was a 7-year-old girl with tricuspid atresia and a previous Glenn shunt, in whom a sub-epicardial overt accessory pathway was successfully ablated via the coronary sinus. The second case, a 9-year-old girl, received accessory pathway ablation via the fenestration of an extracardiac Fontan pathway. The third case was a 14-year-old boy with dextrocardia, common atrium, common ventricle, and a previous extracardiac Fontan operation, in whom ablation of a concealed accessory pathway was carried out retrogradely from the aorta. All the ablations were done in Rajaie Cardiovascular, Medical and Research Center, Tehran, and all the patients were discharged from the hospital without any complication.

*J Teh Univ Heart Ctr 2013;8(2):111-115*

**This paper should be cited as:** Dalili M, Rao JY, Brugada P. Radiofrequency Ablation of Accessory Pathways in Children with Complex Congenital Cardiac Lesions: A Report of Three Cases. *J Teh Univ Heart Ctr 2013;8(2):111-115.*

**Keywords:** Accessory atrioventricular bundle • Heart defect, congenital • Catheter ablation • Child

## Introduction

Catheter ablation is the treatment of choice for most pediatric arrhythmias. There is evidence to show that catheter ablation can be safely performed even in very small children.<sup>1</sup> The process in children is even more challenging than that in adults on account of the small size of the patients and their fragile cardiac tissues. The procedure can be further complicated if the child's heart is anatomically abnormal.

The most problematic cases for ablation are patients with abnormal cardiac positions or univentricular hearts as well as patients after complex cardiac surgeries. We present three cases of accessory pathway (AP) ablation in difficult anatomies and further review the literature.

### Case 1

A 7-year-old girl, weighing 21 kg, presented with frequent

\*Corresponding Author: Mohammad Dalili, Department of Pediatric Cardiology, Rajaie Cardiovascular, Medical and Research Center, Vali-Asr Street. Adjacent to Mellat Park, Tehran, Iran. 1996911151. Tel: +98 21 23922183. Fax: +98 21 22663212. E-mail: drdalili@yahoo.com.

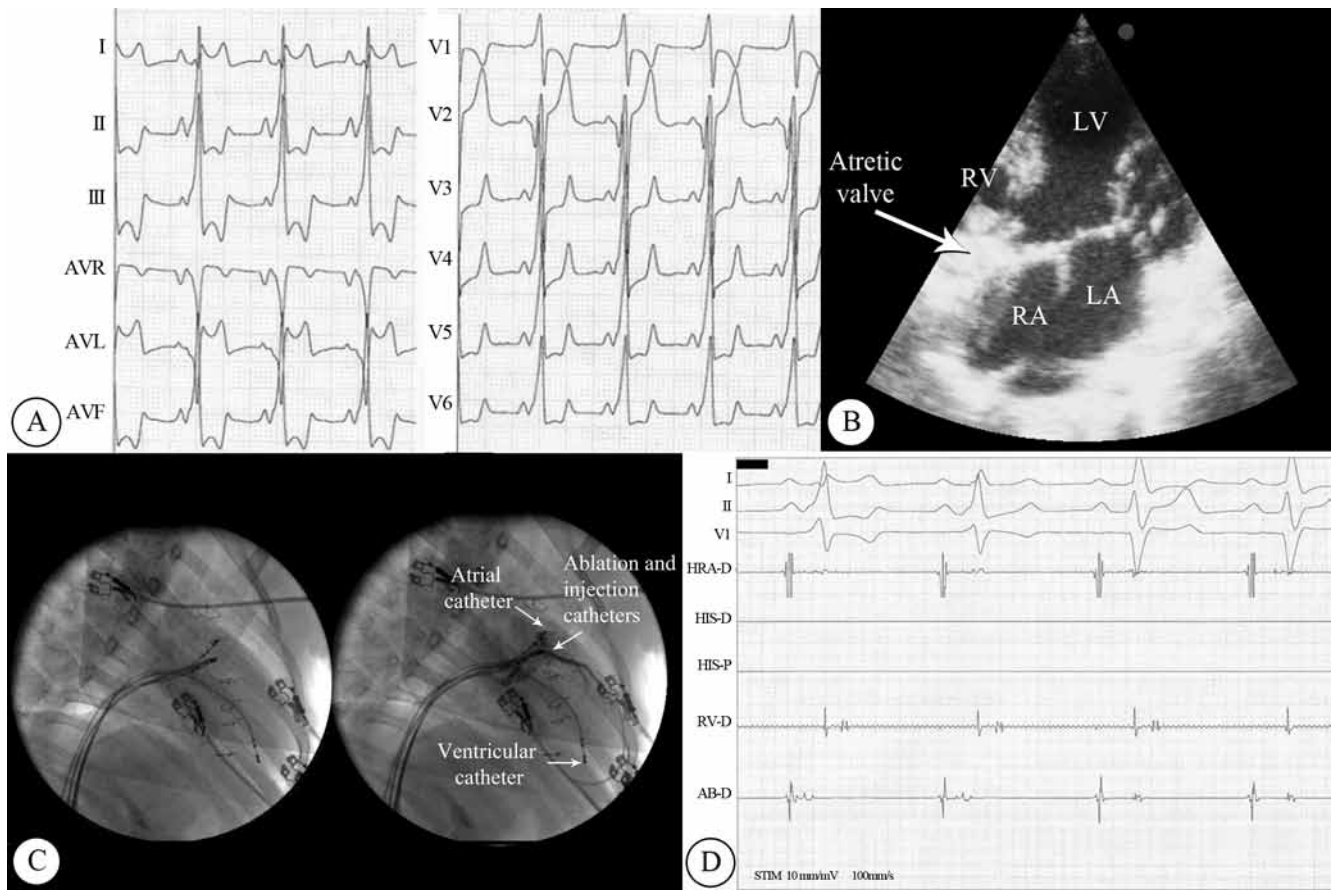


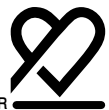Figure 1. A) Electrocardiogram at baseline, showing pre-excitation, which is suggestive of a left lateral bypass tract; B) Two-dimensional echocardiographic image, demonstrating an atretic tricuspid valve, large atrial septal defect, and a rudimentary right ventricle; C) Positions of the atrial, ventricular, and ablation catheters in the coronary sinus in left anterior oblique view before (left) and after (right) contrast injection; D) Electrogram, demonstrating successful ablation LV, Left ventricle; RV, Right ventricle; RA, Right atrium; LA, Left atrium

palpitations and documented narrow complex tachycardia. Her electrocardiogram during sinus rhythm showed a manifest left lateral AP (Figure 1A). In the past, she had been diagnosed to have tricuspid atresia (type IIb) with D-transposition of the great arteries, a large ventricular septal defect, and pulmonary hypertension (Figure 1B). She had undergone pulmonary artery banding, followed by Glenn shunt, and was awaiting total cavopulmonary connection. She had associated severe scoliosis. We conducted an electrophysiological study and documented both an orthodromic atrioventricular reentrant tachycardia and atrial tachycardia with a rapid conduction over the AP. There was no direct access to the right ventricle, and the ventricular catheter was placed via the right atrium into the left atrium and through the atrial septal defect before it was positioned in the left ventricle. Endocardial ablation on the mitral annulus had previously failed at another center. We mapped the mitral annulus again during sinus rhythm: no good signals could be recorded and, thus, no energy was delivered there. We successfully carried out the ablation of the sub-epicardial AP in the coronary sinus near the origin

of the middle cardiac vein (Figure 1C). Interestingly, atrial tachycardia was easily inducible before ablation, but it could not be induced after the elimination of the AP (Figure 1D). The P-wave morphology during atrial tachycardia was in favor of a left atrial origin. The procedure time was 120 minutes, and the fluoroscopy time was 35 minutes.

### Case 2

A 9-year-old girl, weighing 30 kg, presented with recurrent palpitations. Electrocardiography during sinus rhythm revealed a manifest posteroseptal AP (Figure 2C). In the past, she had been diagnosed to have tricuspid atresia (type Ib) with normally-related great arteries, a small ventricular septal defect, and pulmonary stenosis. She had previously undergone extracardiac total cavopulmonary connection and was awaiting fenestration closure with device (because of cyanosis). We conducted an electrophysiological study and documented orthodromic atrioventricular reentrant tachycardia. There were two approaches to the ventricle: 1) from the inferior vena cava into the intracardiac tunnel,



fenestration, atria, and left ventricle, respectively; and 2) via the retrograde aortic approach. We opted to ablate the AP via the retrograde approach on account of its less complexity but failed to obtain appropriate signals, containing atrial electrogram. We were, therefore, obliged to resort to the antegrade approach and pass the ablation catheter through the fenestration (Figure 2A and Figure 2B). We subsequently ablated the left posteroseptal AP from the atrial aspect of the annulus (Figure 2D). The procedure time was 90 minutes, and the fluoroscopy time was 22 minutes.

### Case 3

A 14-year-old boy, weighing 42 kg, presented with recurrent drug (Propranolol and later Amiodarone) refractory tachycardia. Resting electrocardiogram was normal. In the past, he had been diagnosed to have situs inversus totalis with dextrocardia, common atrioventricular canal, and pulmonary stenosis, for which extracardiac total cavopulmonary connection was performed (Figure 3A).

Orthodromic atrioventricular reentrant tachycardia was documented (Figure 3B), and the retrograde aortic approach was selected (Figure 3C). The AP was localized to the right posterior region of the common atrioventricular valve. Ablation was successfully performed under ventricular pacing (Figure 3D). The procedure lasted for 60 minutes, and the fluoroscopy time was 12 minutes.

In all the cases, the AP was ablated on the atrial aspect of the annulus, using Stinger M, curve D, 7F, 4-mm tip catheters (C.R. Bard, Inc., MA, USA) with a power of 20- 30 Watts in the first case and 40 Watts in the others, and a temperature of 55- 60 °C. The patients were observed for 15 minutes after ablation, and electrophysiological studies were repeated to confirm the abolition of the recurrence of the substrate. Amiodarone was discontinued in the third patient.

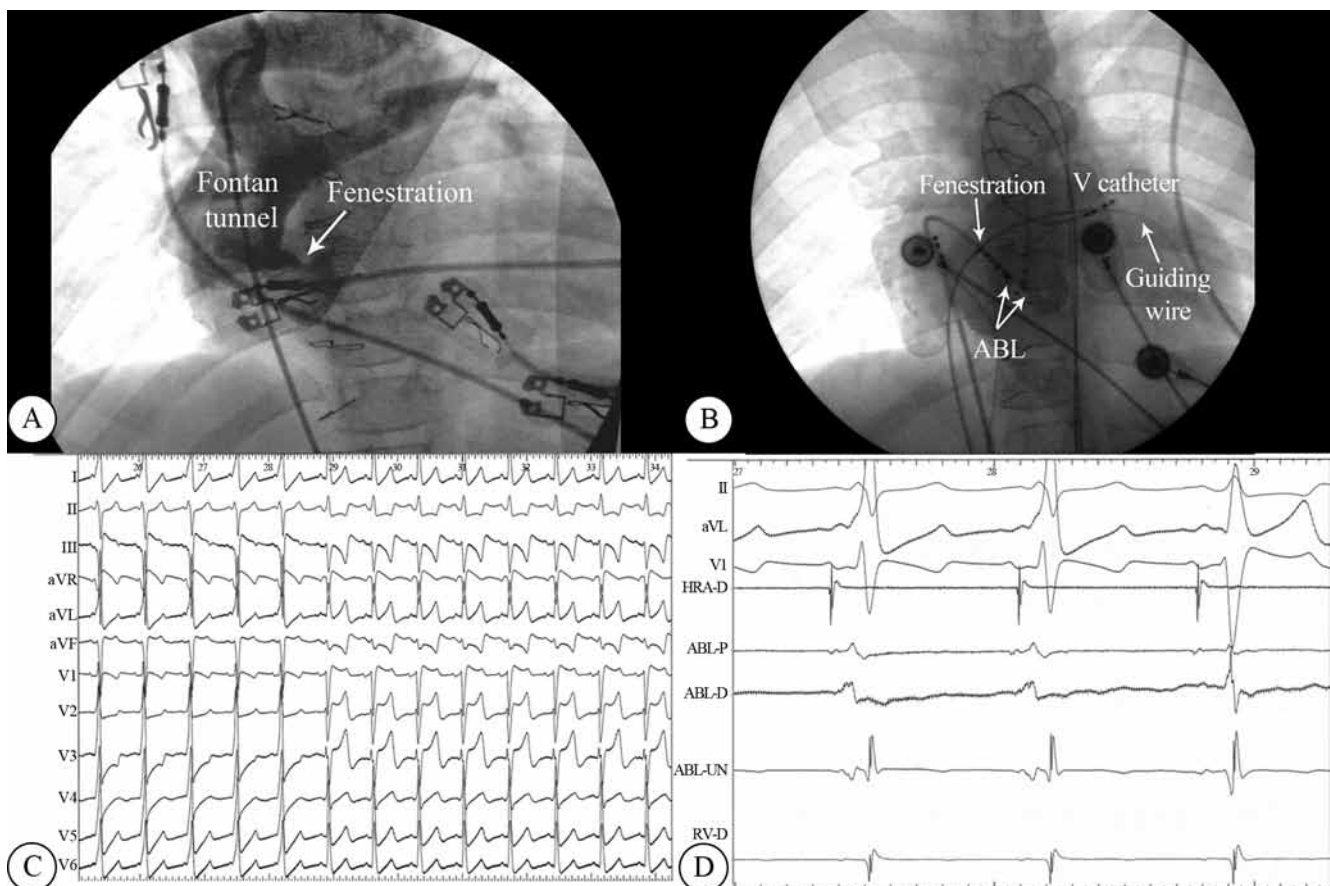


Figure 2. Angiogram in anteroposterior view: contrast injection in the Fontan pathway at the innominate vein level, revealing fenestration in the tunnel (A), position of the ablation catheters: one via the fenestration and the other via the retrograde aortic (B). C) Twelve-lead electrocardiogram during ablation, showing remarkable repolarization changes post ablation. D) Electrogram, revealing successful ablation  
ABL, Ablation catheter; V catheter, Ventricular catheter

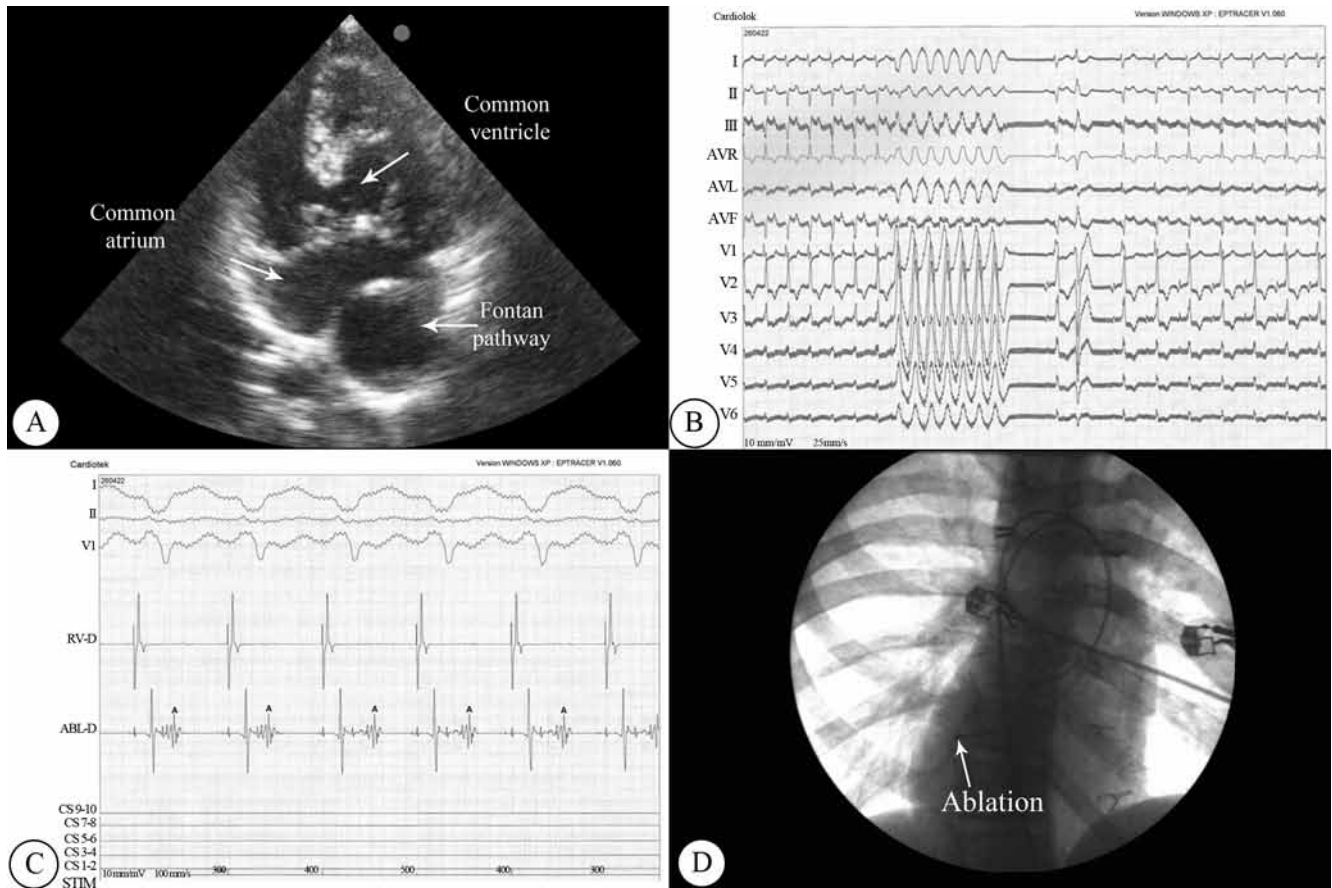


Figure 3. A) Two-dimensional echocardiographic image, depicting the straddling common atrioventricular valve. B) Orthodromic reciprocating tachycardia, terminated by ventricular pacing and resumption of sinus rhythm with a concealed bypass tract. C) Position of the atrial and the ablation catheters, both through the retrograde aortic approach in right anterior oblique projection. D) Successful ablation during ventricular pacing and retrograde conduction purely over the atrioventricular node

## Discussion

Some forms of congenital heart diseases such as Ebstein's anomaly, "corrected" transposition of the great vessels, and tricuspid atresia are associated with a higher incidence of APs.<sup>2,3</sup> Up to a third of patients with Wolff-Parkinson-White syndrome followed up from birth have associated congenital heart diseases.<sup>4</sup> Cardiac arrhythmias, either due to a congenital substrate or secondary to corrective surgeries, complicate the management of patients with structural heart diseases insofar as they are poorly tolerated hemodynamically and drugs prescribed to control them pose problems intrinsic to them.<sup>5</sup> In this subset of patients, radiofrequency ablation should be attempted prior to complete surgical correction whenever possible on account of the fact that the corrective surgeries could eliminate the access to the cardiac chambers of interest.<sup>6,7</sup> In case 1, we ablated inside the coronary sinus because the endocardial approach had failed. Ablation inside the coronary sinus has been described earlier, albeit not in a complex anatomy.<sup>8</sup>

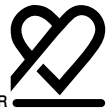## Conclusion

Catheter-based ablation of APs in complex congenital heart diseases can be successfully performed by an experienced electrophysiologist au fait with the anatomy of complex cardiac lesions. In surgical modalities that could eliminate the intracardiac access, it may be preferable to attempt electrophysiological study and ablation before surgery.

## References

1. Blafox AD, Felix GL, Saul JP; Pediatric Catheter Ablation Registry. Radiofrequency catheter ablation in infants  $\leq 18$  months old: when is it done and how do they fare?: short-term data from the pediatric ablation registry. *Circulation* 2001;104:2803-2808.
2. Hager A, Zrenner B, Brodherr-Heberlein S, Steinbauer-Rosenthal I, Schreieck J, Hess J. Congenital and surgically acquired Wolff-Parkinson-White syndrome in patients with tricuspid atresia. *J Thorac Cardiovasc Surg* 2005;130:48-53.
3. Dick M, 2nd, Behrendt DM, Byrum CJ, Sealy WC, Stern AM, Hees P, Rosenthal A. Tricuspid atresia and the Wolff-Parkinson-





- White syndrome: evaluation methodology and successful surgical treatment of the combined disorders. *Am Heart J* 1981;101:496-500.
4. Deal BJ, Keane JF, Gillette PC, Garson A, Jr. Wolff-Parkinson-White syndrome and supraventricular tachycardia during infancy: management and follow-up. *J Am Coll Cardiol* 1985;5:130-135.
  5. Hebe J, Hansen P, Ouyang F, Volkmer M, Kuck KH. Radiofrequency catheter ablation of tachycardia in patients with congenital heart disease. *Pediatr Cardiol* 2000;21:557-575.
  6. Levine JC, Walsh EP, Saul JP. Catheter ablation of accessory pathways in patients with congenital heart disease including heterotaxy syndrome. *Am J Cardiol* 1993;72:689-694.
  7. Friedman RA, Walsh EP, Silka MJ, Calkins H, Stevenson WG, Rhodes LA, Deal BJ, Wolff GS, Demaso DR, Hanisch D, Van Hare GF. NASPE Expert Consensus Conference: Radiofrequency catheter ablation in children with and without congenital heart disease. Report of the writing committee. *North American Society of Pacing and Electrophysiology. Pacing Clin Electrophysiol* 2002;25:1000-1017.
  8. O'Connor BK, Case CL, Gillette PC. Radiofrequency ablation of a posteroseptal accessory pathway via the middle cardiac vein in a six-year-old child. *Pacing Clin Electrophysiol* 1997;20:2504-2507.