



Myxoma of the Superior Vena Cava Origin Presented as a Right Atrial Mass

Feridoun Sabzi, MD*, Babak Nasiri, MD

Cardiovascular Medical Center of Imam Ali Hospital, Kermanshah, Iran.

Received 31 October 2011; Accepted 27 March 2012

Abstract

Myxomas are the most common benign cardiac tumors. Myxomas are more common in the left heart chamber than the right side chamber. An extracardiac origin presenting as a right atrial mass is very rare. We present a case of myxoma originating in the superior vena cava (SVC) in a 24-year-old man, who underwent surgical resection. Preoperative two-dimensional echocardiography demonstrated a mass in the right atrium. Intraoperatively, the tumor was found to have originated from the SVC orifice. The tumor was excised from the SVC by opening the one-third proximal portion of the SVC. Pathological examination revealed a myxoma, and one-year follow-up showed no evidence of the recurrence of any tumors in the SVC.

J Teh Univ Heart Ctr 2013;8(4):202-204

This paper should be cited as: Sabzi F, Nasiri B. Myxoma of the Superior Vena Cava Origin Presented as a Right Atrial Mass. *J Teh Univ Heart Ctr* 2013;8(4):202-204.

Keywords: Heart neoplasms • Myxoma • Vena cava, superior

Introduction

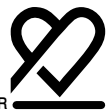Myxomas are the most common type of cardiac tumors, and approximately 75% of these tumors originate in the left atrium and 15% to 20% in the right atrium, with only less than 10% arising from the right and left ventricles. However, the incidence of myxomas in the great vein is extremely rare, and a thorough review of the literature demonstrates only one case in the inferior vena cava (IVC), one case in the femoral vein, and one case in the superior vena cava (SVC). Most patients present clinically with one or more of a triad of emboli, intracardiac obstruction, and constitutional manifestation; furthermore, a small myxoma has no symptoms.¹⁻⁵ The following is a report on an interesting case of an SVC myxoma.

Case Report

A 24-year-old man presented with moderate shortness of breath of two months' duration, which was intermittent and unrelated to exercise or rest. Physical examination showed normal vital signs, blood pressure of 110/80 mm Hg, and pulse rate of 75 beats per minutes and regular. There were no abnormal physical findings such as jugular venous distention, rales, and edema. There was a holosystolic murmur (grade 2/6) over the right parasternal area with radiation to the left. Laboratory findings of note were a hematocrit value of 43% and an erythrocyte sedimentation rate of 12. Chest X-ray revealed no abnormalities, and the electrocardiogram demonstrated a normal sinus rhythm with normal voltage waves.

The patient underwent two-dimensional echocardiography, which demonstrated a 4 × 5 × 5 cm atrial mass attached

*Corresponding Author: Feridoun Sabzi, Associate Professor of Cardiac Surgery, Kermanshah University of Medical Sciences, Imam Ali Hospital, Shaheed Beheshti Ave., Kermanshah, Iran. Tel: + 98 918 1311896. Fax: + 98 831 8360036. E-mail: dr_sabzi@yahoo.com.



by a long stalk to the SVC. During atrial systole, the mass moved into the tricuspid annulus, resulting in an apparent obstruction. There was no evidence of a mass in any other cardiac chambers.

Based on these findings, a right atrium tumor was diagnosed and the patient underwent surgery.

Removal was accomplished via cardiopulmonary bypass. The venous return was accomplished by SVC-IVC cannulation, and the aorta was cross-clamped with cardioplegic arrest. Core cooling to 32 °C, aortic occlusion, and cold cardioplegic arrest provided exposure to the tumor through an extended right atriotomy to the SVC.

The right atrium was opened, and a cluster of grape-shaped, glistening, white masses of leathery consistency (as reported by Devig) was noted within it. The mass was not attached to the right atrial wall and had a long stalk, which was emerging from the SVC orifice (Figures 1-3). The SVC was mobilized, and the tumor stalk was palpable within the SVC. Cavotomy was performed at the site where the stalk was palpable; and under tension and stretching of the stalk, the point of origin was determined to be in the proximal part of the SVC wall.

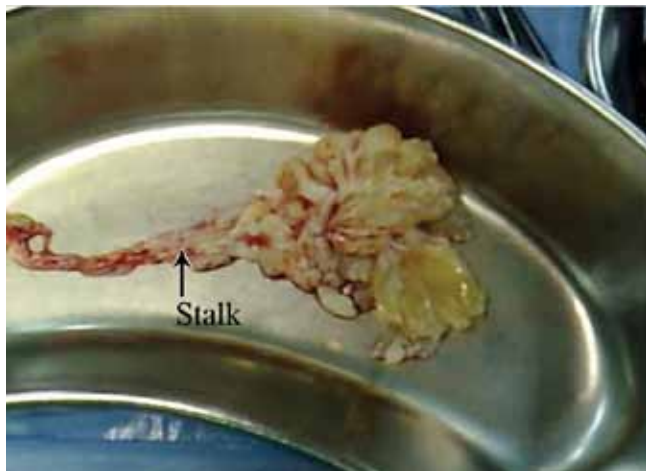


Figure 1. Macroscopic view of tumor with long stalk

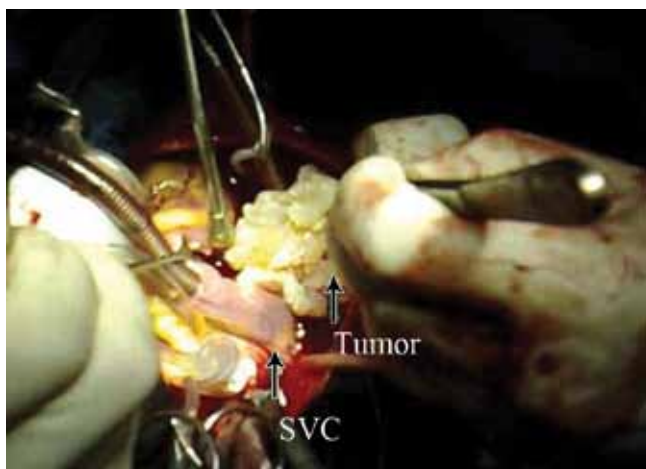


Figure 2. Intra-operative view of tumor, superior vena cava (SVC)

Decision was made to extirpate the stalk base under caudal traction. With the aid of this maneuver, the tumor base was excised from the SVC wall and the small defect in the SVC was repaired. The operative specimen was photographed at the time of excision (Figure 2).

The patient was weaned off cardiopulmonary bypass uneventfully, and his postoperative course was unremarkable. Pathologic examination of the tumor revealed a 5.7 cm firm, cluster tumor, and histological examination revealed a benign myxoma.

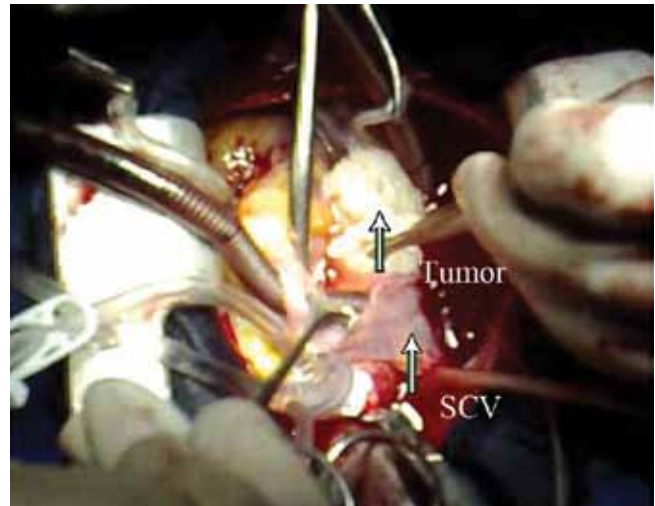


Figure 3. Intra-operative view of tumor with stalk in superior vena cava (SVC)

Discussion

Myxomas were reported for the first time in 1845 by King and then by Goldberg in 1952.⁶⁻⁸ Diagnostic methods for myxomas include chest radiography (pulmonary hypertension, atrial enlargement), two-dimensional transthoracic echocardiography (TTE), transesophageal echocardiography (TEE), and angiography, as well as some other noninvasive modalities such as computed tomography and magnetic resonance imaging. TEE is helpful for the precise localization of a tumor and its point of attachment as well as obstruction of cardiac valves. The indication for selective angiography in patients with myxomas remains for the detection of coronary artery disease if the patients are more than 40 years old. Rath and Demorise^{9, 10} utilized this imaging method for the detection of coronary artery embolus and myocardial infarction in patients with myxomas.

Cardiac tumors are exceedingly rare, with the incidence ranging between 0.001% and 0.03% of the autopsied specimens.¹ Approximately, 75% of primary cardiac tumors are benign, and myxomas are the most frequent type of benign intracardiac tumors with an incidence ranging from 83% to 92%.^{1-3, 11}

Myxomas presenting as a right atrial masses with an extracardiac origin are rare. A literature search revealed only 5 previously reported cases of myxomas arising from the femoral vein, IVC (two cases), Eustachian valve, and SVC.¹²⁻¹⁶ Another instance of a lesion arising from the SVC was reported by Teixido et al.¹⁶ Bontolotti and associates¹³ reported a patient with unusual findings of a right atrial myxoma arising from the supra hepatic segment of the IVC; the tumor was excised under core cooling and cardioplegic arrest with a short period of low-flow cardiopulmonary bypass. Along the same lines, Devig and colleagues¹⁴ described a young man who underwent an excision of a right atrial myxoma located at the junction of the right atrial wall and the anterosuperior aspect of the IVC. Chiming in with the previous findings, Cujec and associates¹⁷ reported a 21-year-old man with a right atrial myxoma arising from the Eustachian valve that prolapsed to the IVC, causing the Budd-Chiari syndrome, and Elmusa et al.¹⁸ reported the excision of a right atrial myxoma from the supra hepatic segment of the IVC. Finally, Teixido et al.¹⁶ were the first to report the case of a young man diagnosed with a testicular germ cell tumor with pulmonary metastasis: there was a large vegetative mass arising from the SVC and extending through the right atrium.

Right atrial myxomas may present with embolic obstructive or constitutional signs and symptoms like syncopal attack, exertional dyspnea, and chest discomfort due to a transient occlusion of the tricuspid by a thrombus or a fragment of the tumor tissue. The most characteristic finding is an ejection-type systolic murmur in the pulmonary area that often varies from day to day or with positional change. Be that as it may, the absence of symptoms, with the exception of dyspnea, in our patient was remarkable insofar as other patients with right atrial myxomas are reported to complain of vague constitutional symptoms such as malaise, low-grade fever, weakness, and unexplained weight loss. Laboratory examinations typically reveal microcytic anemia in addition to an elevation in the erythrocyte sedimentation rate. Once the diagnosis of a cardiac myxoma is established, a prompt excision is essential to prevent complications. In our patient, the myxoma was attached to the medial wall of the SVC and the stalk of the tumor was clearly visualized by the TEE.

McCarthy classified cardiac myxomas into three types: complex; familial; and sporadic. Patients with complex and familial myxomas are characterized by younger age, atypical location, multiple tumor sites, and high incidence of recurrent tumors. Painstaking surgical management and postoperative follow-up are, therefore, of vital importance in this group of patients.

Conclusion

As this case report clearly shows, rare and bizarre

variations in the origin of myxomas may occur and they cannot be discovered preoperatively unless an index of suspicion is maintained.

References

1. Cooley DA, Beall AC, Jr. Surgical treatment of acute massive pulmonary embolism using temporary cardiopulmonary bypass. *1962 Chest* 2009;136:e30.
2. Moosdorf R, Scheld HH, Hehrlein FW. Tumors of the heart. Experiences at the Giessen university clinic. *Thorac Cardiovasc Surg* 1990;38:208-210.
3. Silverman NA. Primary cardiac tumors. *Ann Surg* 1980;191:127-138.
4. Blondeau P. Primary cardiac tumors--French studies of 533 cases. *Thorac Cardiovasc Surg* 1990;38:192-195.
5. Zheng JJ, Geng XG, Wang HC, Yan Y, Wang HY. Clinical and histopathological analysis of 66 cases with cardiac myxoma. *Asian Pac J Cancer Prev* 2013;14:1743-1746.
6. Jung J, Hong YS, Lee CJ, Lim SH, Choi H, Lee S. Successful surgical treatment of a right atrial myxoma complicated by pulmonary embolism. *Korean J Thorac Cardiovasc Surg* 2013;46:63-67.
7. Goldberg HP, Glenn F, Dotter CT, Steinberg I. Myxoma of the left atrium: diagnosis made during life with operative and postmortem findings. *Circulation* 1952;6:762-767.
8. Rath S, Har-Zahav Y, Battler A, Agranat O, Neufeld HN. Coronary arterial embolus from left atrial myxoma. *Am J Cardiol* 1984;54:1392-1393.
9. de Moraes C, Falzoni R, Alves VA. Myocardial infarct due to a unique atrial myxoma with epithelial-like cells and systemic metastases. *Arch Pathol Lab Med* 1988;112:185-190.
10. Salcedo EE, Cohen GI, White RD, Davison MB. Cardiac tumors: diagnosis and management. *Curr Probl Cardiol* 1992;17:73-137.
11. Ramphal PS, Spencer HW, Mitchell DI, Denbow C. Myxoma of right femoral vein origin presenting as a right atrial mass with syncope. *J Thorac Cardiovasc Surg* 1998;116:655-656.
12. Bortolotti U, Faggian G, Mazzucco A, Milano A, Thiene G, Fasoli G, Gallucci V. Right atrial myxoma originating from the inferior vena cava. *Ann Thorac Surg* 1990;49:1000-1002.
13. Devig PM, Clark TA, Aaron BL. Cardiac myxoma arising from the inferior vena cava. *Chest* 1980;78:784-786.
14. Chitwood WR, Jr. Cardiac neoplasms: current diagnosis, pathology, and therapy. *J Card Surg* 1988;3:119-154.
15. Teixido G, Galve E, Avegliano G, Majó J. Myxoma extending from the superior vena cava to the right pulmonary artery. *Rev Esp Cardiol* 2007;60:664-665.
16. Cujec B, Ulmer B, McKaigney JP, Bharadwaj B. Right atrial myxoma presenting as Budd-Chiari syndrome. *Ann Thorac Surg* 1987;44:658-659.
17. Elmusa K, Haddad R, Arnaut MS. Atypical and unusual atrial myxoma. *J Med Liban* 2004;52:48-50.