

Concurrent Mobile and In Situ Types of Right Heart Thrombi

Alireza Rostamzadeh, MD¹, Kamal Khademvatani, MD¹, Yousef Rezaei, MD^{1*},
Nariman Sepehrvand, MD²

¹Seyyed-al-Shohada Heart Center, Urmia University of Medical Sciences, Urmia, Iran.

²National Institute of Health Research, Tehran University of Medical Sciences, Tehran, Iran.

Received 29 October 2012; Accepted 07 April 2013

Abstract

Right-sided heart thrombus is a life-threatening condition that necessitates immediate therapy. Detection of right-sided heart thrombus is usually via transthoracic echocardiography. Generally, thrombolysis is considered a treatment of choice, but there is currently no consensus about the optimal therapeutic choice. We present a case of multiple right atrial thrombi with concurrent mobile and broad-based in situ thrombi in a patient with a history of chronic obstructive pulmonary disease, which was completely resolved by thrombolysis following a failed Heparin infusion. The patient was sent home in good clinical condition and was stable at 3 months' follow-up.

J Teh Univ Heart Ctr 2014;9(2):90-92

This paper should be cited as: Rostamzadeh A, Khademvatani K, Rezaei Y, Sepehrvand N. Concurrent Mobile and In Situ Types of Right Heart Thrombi. *J Teh Univ Heart Ctr* 2014;9(2):90-92.

Keywords: Thrombosis • Thrombolytic therapy • Echocardiography

Introduction

Right-sided heart thrombus (RHT) is a rare condition with such different etiologies as the migration of clots from the systemic veins, central venous catheters, hemodialysis, Behçet's disease, cardiomyopathy, foreign bodies, and cancer-related hypercoagulable state.^{1,2} RHT is regarded as an emergent condition because of its high rate of mortality, especially if it is associated with pulmonary embolism. Its in-hospital mortality is reported to be almost 50%.² There has been a dramatic rise in the detection of RHT in recent years courtesy of the increased use of transthoracic echocardiography (TTE).^{1,3}

In this article, we report a case of RHT with concurrent mobile and fixed thrombi in the right atrium in a patient with

chronic obstructive pulmonary disease (COPD). To the best of our knowledge, this is the first report on the coexistence of two different types of RHT in one patient.

Case Report

A 71-year-old man was referred to our Emergency Department with tachypnea, dyspnea, and exacerbated coughs of 10 days' duration. He had a history of COPD commencing 15 years previously, which was under treatment. The patient had undergone appendectomy 10 years earlier and also had a history of smoking.

The patient was cyanotic at admission with a blood pressure of 100/80 mmHg, heart rate of 90 beats per

*Corresponding Author: Yousef Rezaei, Seyyed-al-Shohada Heart Center, 17 Shahrivar Blvd., Urmia, Iran. 5718749441. Tel: +98 912 6231864. Fax: +98 441 2375907. E-mail: yousefrezaei1986@gmail.com.



minute, respiratory rate of 28 breaths per minute, and body temperature of 36.8 °C axillary. Other remarkable findings on examination are as follows: bilateral coarse crackle and wheezing; a loud P2 and a grade 2/6 systolic murmur heard on auscultation; jugular vein distention; ascites; and bilateral lower-limbs edema. Arterial blood gas evaluation revealed respiratory acidosis. Chest X-ray imaging demonstrated hyperinflation in both lungs, and there was sinus rhythm on the electrocardiogram, suggestive of right ventricular hypertrophy. In addition, the color Doppler ultrasonography of the lower limbs did not demonstrate any sign of deep vein thrombosis. The serum D-dimer level and other laboratory tests were normal, except for the serum creatinine level, which was 2.1 mg/dl. TTE revealed an ejection fraction of 50-55% and right ventricular dysfunction with a smoky pattern. Several intracardiac masses were also detected in the right atrium and around the orifice of the inferior vena cava. The largest of these masses was a 2.7 × 1.8 cm highly mobile mass with a narrow stalk, but the other smaller ones were fixed with broad-based attachments (Figure 1). The systolic pulmonary artery pressure was estimated at 85 mmHg based on Doppler echocardiography.

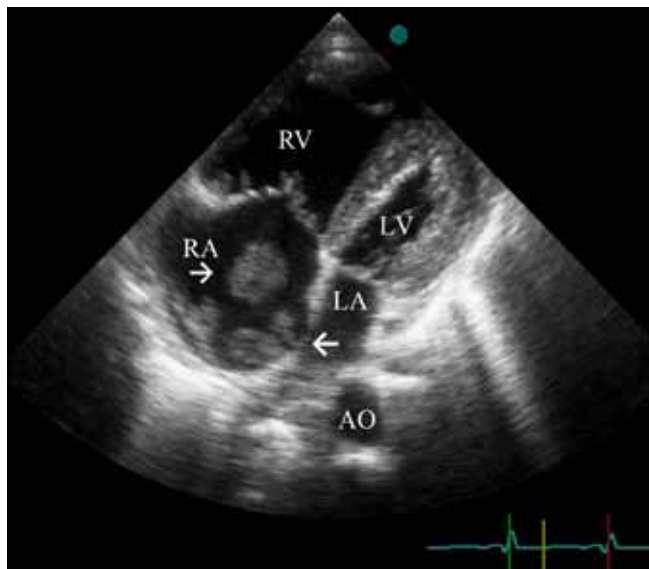


Figure 1. Two-dimensional echocardiographic image, depicting the apical four-chamber view. The top arrow shows a mobile in situ thrombosis with a narrow stalk, and the bottom arrow shows an immobile in situ thrombosis. AO, Aorta; LA, Left atrium; LV, Left ventricle; RA, Right atrium; RV, Right ventricle

The patient refused to undergo transesophageal echocardiography (TEE); consequently, spiral computerized tomographic (CT) scan was conducted to detect evidence of any probable pulmonary embolism. Nevertheless, the CT scan did not confirm the existence of pulmonary embolism or any lung parenchymal findings. It is noteworthy that perfusion scan could not be used due to the pre-existence of long-

standing COPD, which might have contributed to a false-positive detection of the defects in the scan. Furthermore, the patient's renal failure was pre-renal azotemia, for which he was receiving hydration and bicarbonate infusion.

Anticoagulation therapy with Heparin infusion was initiated for the patient. The treatment, however, proved ineffective and the clots remained unchanged on TTE one week later. The patient underwent thrombolytic therapy with Streptokinase infusion for 36 hours. Subsequently, TTE demonstrated no sign of clots. The patient was discharged home with an oral anticoagulation therapy regimen of Warfarin and was stable at 3 months' follow-up.

Discussion

RHT is a phenomenon that is highly associated with pulmonary embolism, especially when the thrombi are floating. There are three types of RHT: 1) floating thrombosis, which often passes through the tricuspid or pulmonic valves or a patent foramen ovale during the cardiac cycle; 2) immobile in situ thrombosis, which is adherent to the cardiac wall; and 3) mobile in situ thrombosis with a stalk and a thin point of attachment to the heart wall. Each type has its own different prognosis based on its condition. The first type is associated with a high incidence rate of pulmonary embolism along with the worst prognosis. In contrast, type 2 has a good prognosis, and type 3 has an intermediate risk and prognosis.⁴ In the present case, the coexistence of two types of RHT is a rare feature, which may have mixed prognosis and, therefore, may need different management modalities compared to the presence of each type solely. The right atrial thrombi in this case may be attributed to blood stagnation caused by long-standing COPD and cor pulmonale, which has a lower risk of pulmonary embolism than do cases with floating clots. In our case, however, there were mobile and immobile clots, concurrently. Moreover, deep vein thrombosis and atrial fibrillation, as the main contributing causes of RHT, were ruled out by sonographic evaluation and detection of sinus rhythm on electrocardiography, respectively.

RHT, particularly its mobile type, is associated with high mortality risk, which requires immediate intervention. The treatment options include conservative (anticoagulation or thrombolysis), invasive interventional, and surgical.^{2,5} In the absence of sufficient research, the optimal treatment for each type of RHT remains controversial.³ Anticoagulation alone with Heparin seems to be less effective in the cases with imminent risk of pulmonary embolism,⁶ but it works well in cases with in situ clots, which have a favorable prognosis.² Be that as it may, Heparin therapy was not effective in our case. According to the majority of reports, thrombolysis is an effective and widely available option that could be suggested as a first therapeutic choice,^{1,7} although its complications such as hemorrhage risk and clot mobilization^{8,9} should be

considered as well. If anticoagulation and thrombolysis fail, the invasive options are the next steps.¹ Nonetheless, surgery is the classic therapy for RHT. Interventional procedures are the last option if the above-mentioned therapies are contraindicated or not applicable.² We could not apply the last two options owing to the absence of an experienced interventionist as well as the surgeon's refusal to perform surgery because of the patient's old age, respiratory discomforts, and refusal to undergo surgery. Indeed, therapy should be selected according to the patient's condition as well as the physician's clinical judgment.

Finally, the insufficient response to anticoagulation due to the concurrency of the two types of clots in our case underscores the need for a well-designed and multi-central study to clarify the proper treatment for all RHT cases.

Conclusion

RHT is an emergent condition requiring immediate therapy. Thrombolysis is deemed a therapeutic choice, not least when the patient cannot be scheduled for surgery. Surgery may be another first-line option if the setting is appropriate.

References

1. Peláez JB, de Miguel EM, Moreno RS, Gómez LR, Etxebeste J, Martín RG, de Maeztu Añon JC, Salcedo JM. Right-atrial floating thrombus attached to the interatrial septum with massive pulmonary embolism diagnosed by echocardiography. *Int J Cardiol* 2008;131:125-127.
2. Chartier L, Béra J, Delomez M, Asseman P, Beregi JP, Bauchart JJ, Warembourg H, Théry C. Free-floating thrombi in the right heart: diagnosis, management, and prognostic indexes in 38 consecutive patients. *Circulation* 1999;99:2779-2783.
3. Rose PS, Punjabi NM, Pearse DB. Treatment of right heart thromboemboli. *Chest* 2002;121:806-814.
4. No authors listed. The European cooperative study on the clinical significance of right heart thrombi. European working group on echocardiography. *Eur Heart J* 1989;10:1046-1059.
5. Cosgrove H, Hyland-McGuire P. Right heart thrombus: the importance of early intervention. *J Accid Emerg Med* 1999;16:291-292.
6. Alizadeh A, Rad MA, Emkanjoo Z, Saravi M, Sadeghi G, Sadr-Ameli MA. Free floating right atrial thrombus in two asymptomatic patients after electrophysiological study: role of routine echocardiography after ablation. *Europace* 2010;12:587-588.
7. Noji Y, Kojima T, Aoyama T, Yamaguchi M, Araki T, Fujino S, Yokota K, Kumamoto N, Nakaya T, Takase K, Shimizu M, Mabuchi H. Images in cardiovascular medicine. Free-floating thrombus in right heart and massive pulmonary embolism migrating into pulmonary artery. *Circulation* 2005;111:e438-439.
8. Ferrari E, Benhamou M, Berthier F, Baudouy M. Mobile thrombi of the right heart in pulmonary embolism: delayed disappearance after thrombolytic treatment. *Chest* 2005;127:1051-1053.
9. Pernat A, Logar M, Zorman SK. Two cases of complications of the thrombolysis of right heart free-floating thrombi with pulmonary embolism: important role of echocardiographically based management. *Int J Clin Pract* 2004;58:628-631.