

Moderate Mitral Regurgitation and Coronary Disease: Treatment with Coronary Bypass Alone?

Hakimeh Sadeghian, MD*, Abbasali Karimi, MD, Hosein Ahmadi, MD, Mojtaba Salarifar, MD, Saeed Sadeghian, MD, Nader Fallah, PhD, Navid Paydari, MD, Mohammad Majd, MD

Tehran Heart Center, Tehran University of Medical Sciences, Tehran, Iran.

Abstract

Background: In cases of moderate (2 or 3+ on a scale of 0 to 4+) nonorganic mitral regurgitation (MR) and coronary artery disease, operative strategy continues to be debated between coronary artery bypass grafting alone (CABG) or concomitant valve repair. To clarify the optimal management of these patients, we evaluated the mid-term results of isolated CABG in the study group.

Methods: From March 2002 to February 2005, 40 consecutive patients (57.5% male, mean age: 62.45 ± 8.7 years, mean ejection fraction: $44.15 \pm 12.6\%$, mean New York Heart Association class 2.5 ± 0.78) with coronary artery disease and moderate MR without organic mitral valve disease (prolapse, rheumatism, etc.) underwent CABG alone. Thirty one (77.5%) patients had either postoperative or follow-up transthoracic echocardiography with mean follow up time of 10.82 ± 8.12 months. Patient's pre and postoperative data were compared to evaluate the results of isolated CABG on moderate MR.

Results: MR was ischemic (with persistent wall motion abnormality) in 25 (62.5%) patients and functional (without persistent wall motion abnormality) in 15 (31.5%). Considering postoperative and follow up transthoracic echocardiography, 54.8% had no or mild MR (29% MR 1+, 25.8% no MR) and 45.2% had moderate MR (16.1% MR 3+, 29% MR 2+). Resolution of MR was significant ($p < 0.001$), but it had no correlation with ischemic MR ($p = 0.46$), preoperative ejection fraction ($p = 0.09$), LV systolic ($p = 0.70$) and diastolic dimensions ($p = 0.80$). Seven patients died, 2 in hospital and 5 later.

Conclusion: Although for coronary artery disease accompanying moderate nonorganic MR, CABG alone reduces severity of MR significantly, many patients are left with moderate MR. Preoperative diagnosis of moderate nonorganic MR may warrant concomitant mitral repair.

The Journal of Tehran Heart Center 1 (2006) 17 -22

Keywords: CABG • Echocardiography • Mitral regurgitation

Introduction

Mitral regurgitation (MR) accompanying coronary artery disease (CAD) is a heterogeneous entity. Ischemic MR (IMR) is mitral insufficiency caused by myocardial infarction and associated with a persistent wall motion abnormality.¹ The

term IMR excludes rheumatic, degenerative, myxomatous, infective and other organic causes of MR.

IMR must be distinguished from organic mitral valve disease with coexisting coronary artery disease, but sometimes it is

*Corresponding Author: Hakimeh Sadeghian, Department of echocardiography, Tehran Heart Center, North Kargar Street, Tehran, Iran 1411713138. Tel: +98-21-88029257. Fax: +98-21-88029256. E-mail: sadeghianhakimeh@yahoo.com.

very difficult to determine whether MR is ischemic or there is a coexisting of MR with coronary artery disease.

In IMR, does coronary artery bypass grafting (CABG) alone and revascularizing ischemic areas improve regional wall motion and correct the MR?

Although most surgeons would agree that severe MR should be corrected at the time of CABG and that trace to mild MR can probably be left alone, the optimal management of moderate ischemic MR remains controversial.

Those favoring a conservative approach, make several arguments:

First, revascularizing ischemic areas will improve regional wall motion and correct the MR.^{2,3,4}

Second, several studies suggest that performing CABG alone does not affect long term survival or functional status.^{5,6,7,8,9}

Many surgeons however, have advocated more liberal use of mitral annuloplasty in patients with moderate MR at the time of CABG.¹⁰

They argue that CABG alone will not correct moderate ischemic MR in many patients, especially those with scarring from myocardial infarction and those with annular and ventricular dilation.¹¹

In addition, intervention on the mitral valve appears to benefit those with symptomatic heart failure.¹² Some authors suggest repairing moderate mitral regurgitation in selected cases to improve long-term quality of life.¹³

This investigation was undertaken to study the influence of CABG alone on moderate non organic MR. For this purpose, we compared severity of MR before and after CABG and at follow up in patients with moderate MR.

Methods

Between March 2002 and February 2005, patients with moderate MR and coronary artery disease (CAD) who underwent CABG alone were identified from Tehran Heart Center surgery data base.

Moderate MR was defined as MR grade II or III with echocardiography or ventriculography.

Based on preoperative echocardiography, we excluded organic mitral valve diseases such as rheumatism, prolapse and infective endocarditis.

Patients with moderate MR and concomitant valve repair or replacement have been evaluated in another study.

MR was defined as ischemic if associated with persistent wall motion abnormality and as functional when there was not any persistent wall motion abnormality.

Parsonnet score was used before the operation to estimate the risk of mortality after CABG.

Echocardiography

A preoperative echocardiography was performed for all

patients. The assessment of mitral regurgitation severity was based on a number of variables (Table 1).¹⁴

Table 1. Assessment of the mitral regurgitation severity

	RV (ml)	ERO cm2	MR jet (%LA)	
I	Mild	<30ml	<0.2	<15
II		30-44ml	0.2-0.29	15-30
III		45-59ml	0.3-0.39	35-50
IV	Severe	≥ 60ml	>0.4	>50

RV, Regurgitation Volume (ml); ERO, Effective Regurgitation Orifice (cm2); MR jet (%LA), Mitral Regurgitation jet (% Left Atrium)

Ventriculography

MR grading based on ventriculography was done according to the following criteria:¹⁵

I. Mild: essentially clears with each beat and never opacifies the entire left atrium.

II. It does not clear with one beat and generally does opacity the entire Left atrium, it is opacified (albeit faintly) after several beats, however, opacification of Left atrium does not equal that of left ventricle.

III. The left atrium is completely opacified and achieves equal opacification of left ventricle.

IV. Severe: opacification of the entire left atrium occurs within one beat, the opacification becomes progressively denser with each beat, and contrast material can be seen refluxing into the pulmonary veins during systole.

Postoperative Transthoracic echocardiography

A postoperative transthoracic echocardiography was performed by a noninvasive cardiologist before discharge for 17/38 (45%) patients.

Follow up

Follow up was conducted in two periods. One between January and March 2004 and another between January and March 2005. Transthoracic echocardiography for follow up was completed in 21 patients. We can not find 5 patients because of change of their telephone NO. And their address, 7 patients interviewed by telephone, but they didn't come for echocardiography and 7 patients were died (2 in hospital and 5 later). The date and cause of death were noted for cases who had died.

Data collection and analysis

Preoperative, operative, and postoperative data were collected prospectively in the division's clinical database and confirmed by review of the actual medical records.



Statistical analysis was performed with the SPSS statistical package (SPSS Inc). All means in the text are expressed as mean \pm SD.

Ordinal variables were compared with the nonparametric Mann-Whitney or Willcoxon signed ranks tests. Categorical Variables were compared with fisher's exact test for 2 X 2 contingency tables and Pearson's χ^2 test for larger tables. A p value < 0.05 was considered statistically significant.

Results

Patient characteristics

Patient demographics, preoperative and postoperative data are presented in (Table 2).

Table 2. Patient characteristics

All patients	n = 40
Age, y	
Mean	62.45 \pm 8.7
Range	44 - 78
Sex	
Male	57.5%
Female	42.5%
Left ventricular function	
Normal (EF \geq 50%)	42.5%
Mild dysfunction (EF 40- 49%)	25%
Moderate dysfunction (EF 30-39%)	12.5%
Severe dysfunction (EF $<$ 30%)	20%
Ejection Fraction	
Mean	44.15% \pm 17.6%
Range	20% - 70%
NYHA Function Class	2.5 \pm 0.78
Mean	
Comorbid condition	
Diabetes mellitus	30%
Hypertension	52.5%
Renal insufficiency	5%
COPD	25%
Number of bypass grafts	
Mean	3.43 \pm 1.01
Range	1-5
Aneurysmectomy	5%
Poor coronary arteries	7.5%
Left main stenosis ($>$ 50%)	7.5%
Recent unstable angina Recent	32.5%
Myocardial infarction	15%
Preoperative IABP	7.5%
Recent pulmonary edema	5%
Cardiogenic shock	2.5%
Congestive heart failure	10%

EF, Ejection Fraction; NYHA, New York Heart Association; COPD, Chronic Obstructive Pulmonary Disease; IABP, Intra Aortic Balloon Pump

Mean age was 62.45 \pm 8.7 years (range 44 to 78 years) and mean ejection fraction was 44.15 \pm 12.60% (range 20 to 70%). 25(62.5%) patients had persistent wall motion abnormality (Ischemic MR (IMR) group), while 15(31.5%) patients had no persistent wall motion abnormality (functional MR (FMR) group).

17(42.5%) patients had preserved left ventricular systolic function (EF \geq 50%) and 23(57.5%) had left ventricular systolic dysfunction (EF $<$ 50%), which 20 % of them had severe systolic dysfunction (EF $<$ 30%). 10 % of patients had congestive heart failure. Recent unstable angina was detected in 32.5 %, recent myocardial infarction in 15%, recent pulmonary edema in 5 %. 7.5% had left main stenosis, 2.5% were in cardiogenic shock and intra aortic balloon pumps (IABP) were used in 7.5% of patients.

Significant non cardiac comorbid conditions, including diabetes mellitus (30%), renal insufficiency (5%) and chronic obstructive pulmonary disease (25%) were not uncommon.

Preoperative data

Preoperative data are shown in table 2. The mean number of bypass grafts was 3.43 \pm 1.01. Aneurysmectomy was done for 5% and 7.5% had poor coronary arteries.

Mortality and functional class

There were 2 (5%) in-hospital deaths and from the 33 patients whom were followed, late death occurred in 5 (16.50%) patients.

All deaths were cardiac related. Overall mortality was 7 (20%) patients, 3 in the IMR group and 4 in functional MR (FMR) group. Mortality was not significantly different between IMR and FMR groups (12% vs. 26.7%, $p=0.99$). Preoperative ejection fraction (43.32 \pm 13.59 vs. 47.14 \pm 10.74, $p=0.48$) and severity of MR ($p=0.62$) had no relation with mortality.

2 in-hospital deaths occurred on the day of operation, one with reducing blood pressure not responding to IABP and the other with cardiac arrest. Of the 5 late deaths, one occurred 30 days after operation due to pulmonary thromboemboli, the 4 other deaths were documented through the telephone. The functional class improved from a preoperative mean of 2.5 \pm 0.78 to a postoperative mean of 1.53 \pm 0.79 ($p=0.002$).

Postoperative TTE

From 17 patients who had postoperative transthoracic echocardiography, 41.2% had no or mild MR and 58.9% had moderate MR (2 or 3+) (Table 3).

Table 3. Mitral regurgitation (MR) severity by TTE or Ventriculography

Severity of MR	Preoperative N=40	Postoperative TTE N=17	Follow up TTE N=21	Postoperative or follow up TTE N=31
0+	0%	29.4%	14.3%	25.8%
1+	0%	11.8%	42.9%	29.0%
2+	80%	47.1%	23.8%	29.0%
3+	20%	11.8%	19.0%	16.1%
4+	0%	0%	0%	0%
Mean severity of MR	2.20±0.41	1.41±1.06	1.47±0.98	1.35±1.05

TTE, Transthoracic Echocardiography

Resolution of MR after CABG alone is significant ($p=0.007$) but it was not different between the IMR and FMR group, (40.0% vs. 42.9%, $p=0.90$). 5 patients (29.4%) had MR 3+ before operation and 12 (70.6%) MR 2+, in postoperative echocardiography 4 of first 5 patients had MR 2 or 3+ and one no or mild MR and from the other 12 patients, 6 had MR 2 or 3+ and 6 no or mild MR, (Odds ratio= 4. 00), (figure 1).

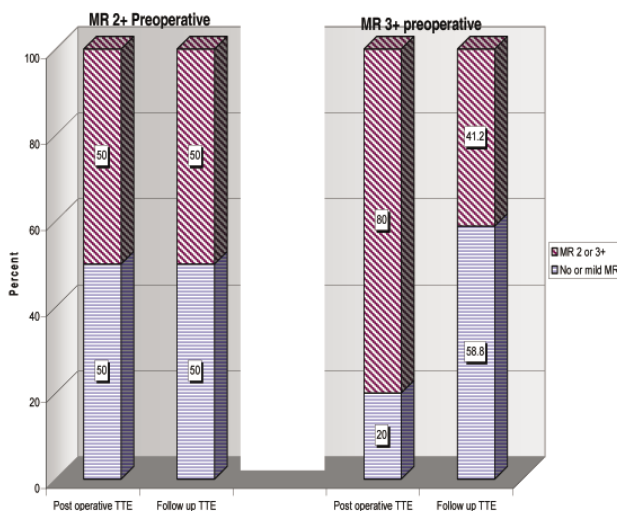


Figure 1. Comparison of resolution of MR in postoperative and Follow up echocardiography

Follow up echocardiography

From 21 patients who had follow up echocardiography, 57.2% of patients had no or mild MR, 42.8% moderate MR. MR resolution was significant ($p=0.007$) but it was not different between IMR and FMR groups,(50.0% vs. 71.4%, $p=0.64$). 4 patients (9.04%) had MR 3+ before operation and 17 (80.95%) MR 2+, in follow up echocardiography 2 of first 4 patients had MR 2 or 3+ and 2 no or mild MR and from the other 17 patients, 7 had MR 2 or 3+ and 10 no or mild MR, (Odds ratio= 1.43), (fig 1). Although reduction of MR in follow up echocardiography in comparison to postoperative echocardiography is not significant ($p=0.4$), but if there is some reduction in severity of MR, it is probably due to time course of recovery of hibernating myocardium. Considering postoperative and follow up echocardiography together, we performed echocardiography for 31 patients.. Postoperative or follow-up echocardiography revealed that 54.8% of patients had no or mild MR and 45.2% had moderate MR. MR reduction was not different between IMR and FMR groups, (47.4% vs. 66.7%, $p=0.46$). Comparing this with preoperative MR, MR reduction is significant ($p<0.001$). The mean preoperative, postoperative, follow up and postoperative or follow-up MR grades were 2.20±0.41, 1.41±1.06, 1.47±0.98 and 1.35±1.05, Respectively (Table 3). There is a trend for persistence of moderate MR after CABG in patients with left ventricular systolic dysfunction (58.8% in patients with $EF<50\%$ vs. 28.6% in patients with $EF\geq 50\%$, $p=0.09$) (table 4).

Table 4. Postoperative or follow up echocardiography (severity of MR in impaired and normal LV systolic function)

	MR 0 or 1+ n (%)	MR 2 or 3+ n (%)	Total n (%)
EF < 50%	7(41.2%)	10(58.8%)	17(100.0%)
EF ≥ 50%	10(71.4%)	4(28.6%)	14(100.0%)
Total	17(54.8%)	14(45.2%)	31(100.0%)

MR, Mitral Regurgitation; LV, Left Ventricle; EF, Ejection Fraction

Resolution of MR was not related to left ventricular diastolic and systolic dimensions (LVDd: 53.69 ± 10.38 vs. 52.85 ± 6.03 mm, $p = 0.80$ and LVDs: 42.69 ± 11.88 vs. 41.17± 6.86 mm, $p=0.70$). 3 (7.5%) patients had poor coronary arteries from which 1 (2.5%) had mild MR in follow up and two died, 1 in-hospital and the other later (who had MR 2+ in postoperative echocardiography). 5 (16.1%) patients had MR 3+ at follow up or postoperative echocardiography; 4 of them were in the IMR group and only 1 patient was in the FMR group, but difference was not significant ($p= 0.62$). Mean ejection fraction in these patients was 42% vs. 44% in the rest, $p= 0.7$. 8 patients (20%) had MR 3+ with echocardiography or angiography before operation, in 4 patients severity of MR was different with these two methods, in 4 other patients



when our surgeons checked severity of MR in the time of operation, it seemed non significant and so they did not repair mitral valve. In follow up of these patients, 3 had MR3+ (one died later), 1 MR 2+, 1 MR 1 +, 2 no MR and another died later. From 5 patient who had MR 3+ after operation, 3 had MR3+ before operation, 1 MR 1+ and 1 MR 2+.

Intraoperative transesophageal echocardiography

From 3 patients who had intraoperative TEE (post-pump) 1 had moderate MR and she died on the day of operation, 2 had mild MR and upon follow up echocardiography one of them had mild MR and the other moderate MR.

Discussion

There are two key findings in this study: 1) although resolution of MR after CABG alone is statistically significant and 55% of patients had resolution of MR, but 45% continued to have moderate MR after CABG alone.

2) There is a trend for persistence of MR in patients with impaired LV systolic function. In addition, most patients with MR 3+ after CABG alone were in the IMR group.

Effect on mortality

In hospital mortality was 5% and overall mortality in the patients who were followed was 7/35 (20%).

Parsonnet score of these patients was 19.58 ± 9.77 . According to the Parsonnet score, in-hospital mortality for a score between 15-20, is about 9.5 %¹⁶ so in-hospital mortality in this study is lower than comparable populations.

Late mortality in our study was 16.5 % which was comparable to the Ogun report (16%),⁴ but mean ejection fraction of their patients was lower ($25 \pm 5\%$).

Clinical Implications

The present study addressed the specific question of whether CABG alone corrects moderate MR in the mid term.

Although many patients had some improvement in their MR, a significant proportion was left with moderate MR. The long term clinical implications of these results are not specifically addressed in the present study. Whether these results justify more liberal use of mitral annuloplasty depends on the answer to 2 follow up questions: 1) what is The long-term impact of residual MR on functional status and survival? 2) Does this MR gradually progress to severe MR and produce left atrial and ventricular dilation, elevate pulmonary pressure, increase the frequency of atrial fibrillation and need for reoperation?

Skeptics have argued that residual MR after CABG alone does not have an adverse effect on late functional status or survival.

In the Emory group study,⁶ 5-and 10- year actuarial survival

was nearly identical to that of a control group without preoperative MR undergoing CABG during the same time period. One other study suggests that CABG alone does not affect long-term survival in patients with moderate ischemic MR.¹⁷

Two large studies^{18,19} in the 1980s suggest that MR is an independent risk factor for late death in patients undergoing CABG.

There is limited information in the literature on the late functional status of patients undergoing CABG alone for moderate ischemic MR. Mallidi et al reported that overall late survival was not affected by the presence of mild to moderate degrees of mitral regurgitation in patients undergoing CABG but These patient had poorer event-free survival and worse late functional status.¹³ The Emory study⁶ reported a trend toward more class III and IV angina (29% versus 6%) and congestive heart failure (14% versus 6%) compared with case-matched controls. On the other hand, Bolling et al²⁰ reported that nearly all patients undergoing mitral valve repair at the time of CABG moved from class III or IV to class I or II.

These findings raise the possibility that even if the significant rate of residual MR noted in the present study does not result in decreased long term survival, it may adversely affect long-term functional status and quality of life. Concomitant mitral valve repair may therefore be justified, if it can be performed with relatively low operative risk, to improve long-term functional status. In our study, there is a trend for persistence of moderate MR in patients with left ventricular systolic dysfunction. In addition, of 5 patients with MR3+ after CABG, 4 were in the IMR group. Is there any association between Ischemic MR as the mechanism of MR and preoperative ejection fraction with resolution of MR after CABG alone? If this hypothesis could be proved, we can determine patients who need mitral valve repair by preoperative transthoracic echocardiography. For proving the hypothesis we need a prospective study with more patients.

Study Limitations

The primary limitation of the present study is that it is a retrospective analysis, susceptible to various sources of bias.

The second limitation is that decision to forgo concomitant mitral valve repair was not based on specific preoperative criteria but solely on surgeon preference.

Individual surgeons differed in their threshold for exploring the mitral valve based on their assessment of the literature, with some surgeons performing CABG alone as a matter of policy.

Conclusion

Although CABG alone reduces MR severity significantly in patients with moderate non organic MR, but about 45%

of patients are left with moderate MR, so wider application of mitral annuloplasty may be warranted in these patients. More detailed analysis is necessary to determine preoperative factors that predict residual MR after CABG alone, and long-term follow up is necessary to determine the impact of residual MR on late symptoms and survival.

A prospective study with routine echocardiography is necessary to determine whether LV systolic function, persistent wall motion abnormality and scarring myocardium have any effect on residual MR after CABG in these patients.

References

1. Gorman RC, Gorman III/L JH, Edmunds, Jr. H. Ischemic mitral regurgitation. In: Cohn LH, Edmunds, Jr. LH, eds. Cardiac surgery in the adults. New York: Mc Graw-Hill; 2003. p. 751-769.
2. Balu V, Hershowitz S, Zaki Masud AR, Bhayana JN, Dean DC. Mitral regurgitation in coronary artery disease. *Chest* 1982;81:550-555.
3. Christenson JT, Simonet F, Bloch A, Maurice J, Velebit V, Schmuziger M. Should a mild to moderate ischemic mitral valve regurgitation in patients with poor left ventricular function be repaired or not? *J Heart Valve Dis* 1995;4:484-488.
4. Ogun NT, Hulusi Us M, Ogun H, Islik O. Coronary artery bypass grafting alone for advanced ischemic left ventricular dysfunction with significant Mitral regurgitation: early and midterm outcomes in a small series. *Tex Heart Inst J* 2004;1:143-8.
5. Tolis GA., Korkolis DM, Kopf GS, Elefterades JA.. Revascularization alone (without mitral valve repair) suffices in patients with advanced ischemic cardiomyopathy and mild-to-moderate mitral regurgitation. *Ann Thorac Surg* 2002;74:1476-81.
6. Duarte IG, Shen Y, MacDonald MJ, Jones EL, Carver JM, Guyton RA.. Treatment of moderate mitral regurgitation and coronary disease by coronary bypass alone: late results. *Ann Thorac Surg* 1999;68:426-430.
7. Connolly MW, Gelbfish JS, Jacobowitz IJ, Rose DM, Mendelsohn A, Cappabianca PM. Surgical results for mitral regurgitation from coronary artery disease. *J Thorac Cardiovasc Surg* 1986;91:379-388.
8. Arcidi JM Jr, Hebel RF, Craver JM, Jones EL, Hatcher CR Jr, Guyton RA.. Treatment of moderate mitral regurgitation and coronary disease by coronary bypass alone. *J Thorac Cardiovasc Surg* 1988;95:951-959.
9. Rydén T, Bech-Hanssen O, Brandrup-Wognsen G, Nilsson F, Svensson S, Jeppsson A. The importance of grade 2 ischemic mitral regurgitation in coronary artery bypass grafting. *European Journal of Cardio-thoracic Surgery* 2001;20:276-281.
10. Aklog L, Filsoufi F, Flores KQ, Chen RH, Chon LH, Nathan NS, Byrne JG, Adams DH. Does coronary artery bypass grafting alone correct moderate ischemic mitral regurgitation? *Circulation* 2001;104[suppl I]: I-68-I-75.
11. Czer LSC, Maurer G, Bolger AF, Derobertis M, Chaux RNA, JM Matloff. Revascularization alone or combined with suture annuloplasty for ischemic mitral regurgitation: evaluation by color Doppler echocardiography. *Tex Heart Inst J* 1996;23:270-278.
12. Harris KM, Sundt III TM, Aeppli D, Sharma R, Brazilai B. Can late survival of patients with moderate ischemic mitral regurgitation be impacted by intervention on the valve? *Ann Thorac Surg* 2002;74:1468-75.
13. Mallidi HR, Pelletier MP, Lamb J, Desai N, Sever J, Christakis GT. Late outcomes in patients with uncorrected mild to moderate mitral regurgitation at the time of isolated coronary artery bypass grafting. *J thorac Cardiovasc Surg* 2004;127:636-644.
14. Feigenbaum H, Armstrong WF, Ryan T. Mitral valve Disease. In: Feigenbaum H, Armstrong WF, Ryan T, eds. *Feigenbaum's Echocardiography*. 6th ed. Philadelphia: WILLIAMS and WILKINS; 2005. p. 306-385.
15. Grossman W. Profiles in valvular heart disease. In: Baim D, Grossman W, eds. *Cardiac catheterization, angiography, and intervention*. Baltimore: Mc Graw-Hill; 2001. p. 742-743.
16. Lawrence DR, Valencia O, Smith EEJ, Murday A, Treasure T. Parsonnet score is a good predictor of the duration of intensive care unit stay following cardiac surgery. *Heart* 2000;83:429-432.
17. Hickey MS, Smith LR, Muhlbaier LH, Harrell FE Jr, Reves JG, Hinohara T, Califf RM, Pryor DB, Rankin JS. Current prognosis of ischemic mitral regurgitation: Implications for future management. *Circulation* 1988;78(suppl I): I-51-I-59.
18. Adler DS, Goldman L, O'Neil A, Cook EF, Mudge GH Jr, Shemin RJ, DiSesa V, Cohn LH, Collins JJ Jr. Long-term survival of more than 2,000 patients after coronary artery bypass grafting. *Am J Cardiol* 1986;58:195-202.
19. Pinson CW, Cobanoglu A, Metzendorf MT, Grunkemeier GL, and Kay PH, Starr A. Late surgical results for ischemic mitral regurgitation: role of wall motion score and severity of regurgitation. *J Thorac Cardiovasc Surg* 1984;88:663-672.
20. Bolling SF, Deeb GM, Bach DS. Mitral valve reconstruction in elderly, ischemic patients. *Chest* 1996;109:35-40.