



## A Large Mobile Aortic Arch Mass

Mehrnoush Toufan, MD\*, Farnaz Sepasi, MSc, Saba Asghari, MSc, Amirhosein Fathi, MSc

Tabriz Heart Research Center, Tabriz University of Medical Sciences, Tabriz, Iran

Received 20 December 2006; Accepted 26 February 2007

### Abstract

Mobile luminal mass of aortic arch is an unusual finding in patients with peripheral embolization. To search the source of these emboli, aortic arch mass should be considered. To our knowledge, transesophageal echocardiography (TEE) can be a useful modality to demonstrate the nature and exact location of the mass. This report is illustrative of a large mobile aortic arch mass, histologically thrombus, found by TEE in a 48-year-old woman with embolic symptoms.

*J Teh Univ Heart Ctr* 2 (2007) 117-118

**Keywords:** Aortic arch mass • Thrombus • Transesophageal echocardiography

### Introduction

Mobile luminal mass of aortic arch is an unusual finding in patients with peripheral embolization,<sup>1</sup> as in this case, emboli to liver, spleen, kidney and lower extremities.

Herein we report a mobile aortic arch mass<sup>2</sup> found by transesophageal echocardiography (TEE) in a 48-year-old woman with embolic symptoms. A pathologic examination of the specimen after surgery revealed thrombus.

ischemia was detected. All radial, brachial, femoral, popliteal, dorsalis pedis, and tibialis posterior pulses were diminished. Radial and brachial pulses were normally palpated after heparinization.

Lab tests revealed: ESR=93, CRP=2+, and Creatinine=2.1 mg/dl. Protein C, Protein S, and Anti thrombin III were not checked. Liver function test had increased. Other lab findings are shown in Table 1.

### Case Report

A 48-year-old woman was referred from the rheumatology ward to our heart center. Her Chief Complaint was: claudication and lower extremity pain that had become worse during the past 3 weeks.

On physical examination, lungs and heart were normal. There were no palpable lymph nodes in the neck. No organomegally was found. There were no skin lesions, but discoloration of the lower extremity skin in favour of arterial

Table 1. Laboratory results

Tests	Results	References
ESR	1 <sup>st</sup> hour 2 <sup>nd</sup> hour	93 120
CRP	2+	0-20 mm/hr 0-30 mm/hr
Cr	2.1	Neg
ALT	98	0.6-1.3 mg/dl
AST	183	5-49 mg/dl
BUN	40	5-40 mg/dl
ANA	Neg	7-20 mg/dl
RF	Neg	Neg<1:40 Neg<1:80 or 60 u/ml

ESR; Erythrocyte sedimentation rate, CRP; C-reactive protein, Cr; Creatinine, ALT; Alanine aminotransferase, AST; Aspartate aminotransferase, BUN, Blood urea nitrogen; ANA, Anti nuclear antibody; RF, Rheumatoid factor

\*Corresponding Author: **Mehrnoush Toufan**, Assistant Professor of Cardiology, Heart Research Center, Tabriz University of Medical Sciences. Golgasht St, Attar Neishaboori Ave, Tabriz, Iran. Tel: +98 914 311 12 84. Fax: +98 411 669 52 04. E-mail: m\_toufan@yahoo.com.

Chest X-ray showed normal heart and lungs. Doppler ultrasonography studies showed 70% occlusion of the Tibioproneal artery with filling defect, and decreased flow of anterior and posterior tibioproneal in both lower extremities. Over the next few days, the patient underwent a CT angiography, which identified the occlusion of the aortic arch. CT angiogram also demonstrated emboli in the liver, spleen, left kidney, and extremities.

To search for a possible embolic source a TEE was done. The echogram showed no evidence of valvular vegetations, with normal chamber size. Ejection fraction (EF) was 45-50%. TEE revealed a large mobile irregular nonhomogeneous mass attached to the wall of the intraluminal aortic arch with a narrow stalk (attachment site: lesser curve of aortic arch), and no intimal thickening, no flap, no arteritis, and no plaque were found (Figure 1).

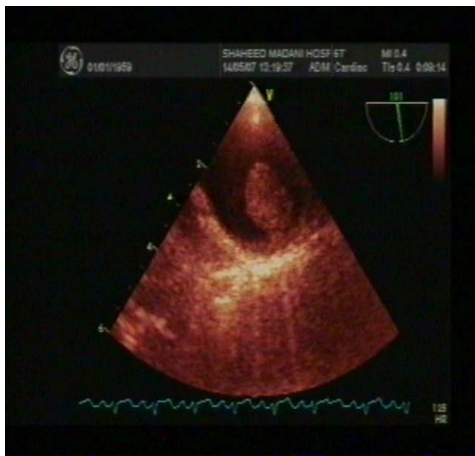


Figure 1. Transesophageal echocardiography showed an aortic arch clot

Surgical removal of the mass was considered urgently, so the patient was taken to the operating room for direct surgical mass removal. The resected mass from the aortic arch was 7 cm in length and 1.5 cm in width. Postoperative TEE showed no mobile mass in the ascending aorta and aortic arch, while EF was the same. The patient responded positively to receiving systemic heparinization. Histologically, sections from the received specimen disclosed only blood clot.

After this procedure, the patient continued to improve and was discharged home on warfarin therapy.

## Discussion

Use of TEE has greatly improved the visualization of lesions involving the thoracic aorta and aortic arch.<sup>1</sup> Choukroum et al.<sup>3</sup> reported 9 cases with embolic thoracic aorta thrombi diagnosed by TEE. Klocker et al. suggested the association of mobile thoracic aorta debris and blue toe syndrome. These

studies suggest a definite risk of peripheral embolization associated with mobile aortic thrombi. It seems that TEE is the most reliable method for the detection of mobile aortic thrombi.

Correlations of TEE and pathologic findings of operative specimens confirm that mobile aortic debris is formed by thrombus with associated atherosclerotic plaques.<sup>4</sup> But in the present study, no intimal thickening, no arteritis, and no plaque were found. The appearance of the mass was atypical from what has previously described as atherosclerotic plaque.<sup>5</sup> It was a highly mobile mass in front of the blood jet.

## Conclusion

We should pay attention to the cases with multiple peripheral embolic symptoms. Aortic thrombus with embolic potential should be considered. To our knowledge, TEE can be a useful and valuable diagnostic modality,<sup>6,7</sup> to demonstrate the nature and exact location of the mass.

We reported a case where an aortic mass was without mural atherosclerotic plaque diagnosed by TEE. The mass could be a source for embolization. Microscopic study of the resected mass revealed a blood clot.

## References

1. Criado E, Wall P, Lucas P, Gasparis A, Proffitt T, Ricotta J. Transesophageal echo-guided endovascular exclusion of thoracic aortic mobile thrombi. *J Vasc Surg* 2004;39:238-242.
2. Pasiński T, Jasek S, Firek B, Przybylski A, Szwed H, Sadowski Z. Resolution of an aortic mobile mass with anticoagulation without evidence of arterial embolism. *Clin Cardiol* 1996;19:151-152.
3. Choukroum EM, Labrousse LM, Madonna FP, Deville C. Mobile thrombus of the thoracic aorta: diagnosis and treatment in 9 cases. *Ann Vasc Surg* 2002;16:714-722.
4. Vaduganathan P, Ewton A, Nagueh SF, Weilbaecher DG, Safi HJ, Zoghbi WA. Pathologic correlates of aortic plaques, thrombi and mobile "aortic debris" imaged in vivo with transesophageal echocardiography. *J Am Coll Cardiol* 1997;30:357-363.
5. Rossi PJ, Desai TR, Skelly CL, Curi MA, Glagov S, Schwartz LB. Paravisceral aortic thrombus as a source of peripheral embolization-report of three cases and review of the literature. *J Vasc Surg* 2002;36:839-843.
6. Tunick PA, Kronzon I. Protruding atherosclerotic plaque in the aortic arch of patients with systemic embolization: a new finding seen by transesophageal echocardiography. *Am Heart J* 1990;120:658-660.
7. Dubin JD, Miller C, Mayrer A, Veltri E. Evolving aortic mass in a patient with sepsis and systemic embolization. Detection by transesophageal echocardiography. *Chest* 1992;102:1882-1883.