



## Successful Implantation of Coronary Sinus Lead after Balloon Angioplasty of a Coronary Vein Stenosis

Mohammad Hasan Namazi, MD\*, Morteza Safi, MD, Hassan Kamalzadeh, MD  
Reza Karbasi, MD

*Cardiovascular Research Center/Shaheed Beheshti University of Medical Sciences, Tehran, Iran.*

Received 10 March 2007; Accepted 21 July 2007

### Abstract

A 55-year-old man referred for cardiac resynchronization therapy (CRT) due to severe heart failure. A severe stenosis in the coronary sinus vein after the posterior branch disallowed the insertion of the lead. Nevertheless, the stenosis was dilated and the left ventricle (LV) lead was implanted in the lateral marginal branch.

*J Teh Univ Heart Ctr 4 (2007) 233-234*

**Keywords:** Coronary sinus lead • Coronary vein stenosis • Coronary vein angioplasty

### Introduction

Currently available tools and techniques achieve a greater than 90% transvenous left ventricle (LV) lead placement success rate. However, failure to implant the coronary sinus (CS) lead is reported in 8-10% of procedures.<sup>1</sup> This is mainly due to failure to cannulate the CS, inappropriate coronary vein, unstable lead position, high stimulation threshold, and unavoidable phrenic nerve stimulation.<sup>2</sup> This report describes a patient in whom coronary vein stenosis disallowed the normal insertion of the CS lead, but the LV lead was subsequently implanted in the lateral marginal branch following balloon angioplasty.

### Case report

A 55-year-old man presented with dilated cardiomyopathy, and further investigations revealed the following: New York

Heart Association (NYHA) class III, left bundle branch block (LBBB), left ventricular ejection fraction (LVEF) of 20% and left ventricular end-diastolic diameter of 7cm. He was candidate for biventricular pacing therapy. A Tissue Doppler Imaging study showed compatibility for cardiac resynchronization (CRT) therapy.

Anesthesia having been established with lidocaine 2%, a temporary pace maker was inserted in the right ventricular apex and coronary sinus cannulation was performed. A retrograde venography showed severe stenosis in the CS after the posterior branch. Although a 0.014-inch guide wire could easily cross the stenotic area, a Medtronic 4194 lead (inserted over the guide wire) could not pass. As shown in

\*Corresponding Author: Mohammad Hasan Namazi, Associate Professor of Cardiology, Shaheed Modarres Hospital, Cardiovascular Research Center, Saadat abad, Tehran, Iran. 19987-34383. Tel: + 98 21 22083106. Fax: +98 21 22083106. Email: mohamadhasannamazi@yahoo.co.uk.

Figure 1, despite the fact that there were no suitable venous branches before the stenosis, a good lateral marginal branch after the stenosis was noted.

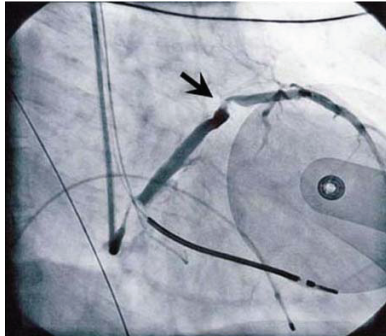


Figure 1: Coronary sinus stenosis

A VOYGER balloon, 3 mm in diameter and 15 mm in length, was negotiated through the lesion before it was inflated up to 8 atm (Figure 2).

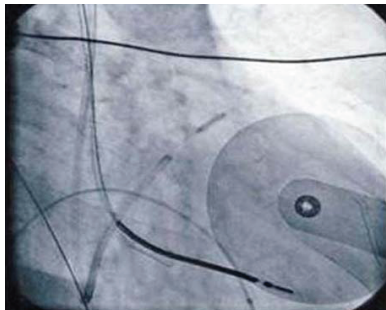


Figure 2: Coronary sinus balloon angioplasty

After angioplasty, the percutaneous transluminal coronary angioplasty (PTCA) catheter was exchanged for a Medtronic lead 4194, and it was passed through the dilated area without any difficulty and was inserted in the lateral marginal branch. A satisfactory stable lead position with acceptable threshold of LV lead and 890-ohm impedance without phrenic nerve stimulation was obtained. After the insertion of the other leads (right atrium and right ventricle) in suitable positions, all the leads were connected to the Medtronic INSYNC III MARQUIS pace maker and biventricular pace maker was commenced (Figure 3). Due to the relatively bad situation of the patient and successful implantation of the coronary sinus lead, second retrograde venography was not performed.

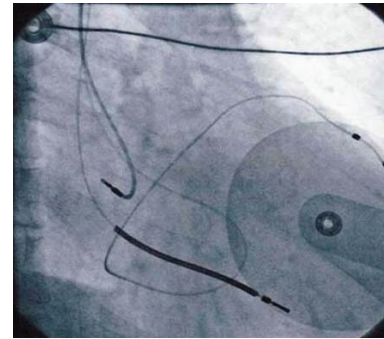


Figure 3: Coronary sinus lead implantation

## Discussion

To our knowledge, symptomatic coronary vein stenosis has not been reported yet. This could be in part explained by the presence of an abundant collateral circulation.

Coronary vein angiograms performed during biventricular pacemaker implantation elucidate the presence of an asymptomatic coronary venous stenosis in approximately 10% of the authors' patients.

In this patient, we were unable to pass the CS lead through the stenotic area; therefore, we chose to dilate the coronary vein stenosis.

Venous stenting within the context of pacemaker-induced superior vena cava syndrome for symptomatic patients or to gain access to the central venous circulation has been previously reported.<sup>3,4</sup>

For this patient, we dilated a relatively large vein. Although there is risk of a subsequent occlusion of the smaller coronary veins, the extensive collateral circulation of the cardiac veins avoids clinical sequel. Only in the event of lead extraction can such an occlusion cause problems.

## References

1. Cazeau S, Leclercq C, Lavergne T, Walker S, Varma C, Linde C, Garrigue S, Kappenberger L, Haywood GA, Santini M, Bailleul C, Daubert JC; Multisite stimulation in cardiomyopathies (MUSTIC) study investigators. Effects of multisite biventricular pacing in patients with heart failure and intraventricular conduction delay. *N Engl J Med* 2001;344:873-880.
2. Walker S, Levy T, Rex S, Brant S, Paul V. Initial United Kingdom experience with the use of permanent, biventricular pacemakers: implantation procedure and technical considerations. *Europace* 2000;2:233-239.
3. Francis CM, Starkey IR, Errington ML, Gillespie IN. Venous stenting as treatment for pacemaker-induced superior vena cava syndrome. *Am Heart J* 1995;129:836-837.
4. Ing FF, Mullins CE, Grifka RG, Nihill MR, Fenrich AL, Collins EL, Friedman RA. Stent dilation of superior vena cava and innominate vein obstructions permit transvenous pacing lead implantation. *Pacing Clin Electrophysiol* 1998;21:1517-1530.