



Endovascular Repair of a Common Carotid Pseudoaneurysm in a Patient with Behçet's Disease: A Case Report and Review of Literature

Seyed Ebrahim Kassaian, MD, FACC¹, Behnam Molavi, MD¹, Kyomars Abbasi, MD¹, Mohammad Sadeghian, MD¹, Shahrooz Yazdani, MD^{2*}

¹Tehran Heart Center, Tehran University of Medical Sciences, Tehran, Iran.

²Shahid Rajaei Hospital, Alborz University of Medical Sciences, Karaj, Iran.

Received 16 June 2019; Accepted 05 May 2020

Abstract

Behçet's disease (BD) is a multisystem inflammatory disorder. Physicians should be alerted to the possibility of BD in a patient with a carotid artery pseudoaneurysm and no clear predisposing factor such as neck trauma or surgery. Endovascular repair of carotid pseudoaneurysms is technically feasible with excellent midterm follow-up results. Administration of immunosuppressive therapy before endovascular intervention is mandatory to reduce the chance of vascular complications accompanied by BD.

A 40-year-old man presented with a painful and pulsatile neck mass with 2 episodes of transient ischemic attacks. The patient also complained of recurrent urogenital ulcers and aphthous lesions together with painful rashes. Ultrasonography and computed tomography angiography revealed 2 aneurysmal dilations in the left common carotid artery at the bifurcation level. He was referred to a rheumatologist, who made the diagnosis of BD. High-dose corticosteroids and cyclophosphamide were commenced. One week later, 2 overlapping self-expanding stent grafts were deployed. The final angiogram showed no residual endoleak, and the flow of the carotid and cerebral arteries was satisfactory. The patient was discharged with no neurological complications. Follow-up ultrasonography and computed tomography angiography 6 months later showed no endoleak, as well as significant shrinkage of the aneurysm sac.

J Teh Univ Heart Ctr 2020;15(3):131-135

This paper should be cited as: Kassaian SE, Molavi B, Abbasi K, Sadeghian M, Yazdani S. Endovascular Repair of a Common Carotid Pseudoaneurysm in a Patient with Behçet's Disease: A Case Report and Review of Literature. *J Teh Univ Heart Ctr 2020;15(3):131-135.*

Keywords: Carotid arteries; Aneurysm, false; Behçet syndrome; Stents

Introduction

Behçet's disease (BD) is a multisystem inflammatory disorder, the characteristic findings of which include recurrent urogenital ulcers, vascular disorders, and ocular and cutaneous lesions. Vascular involvement has been reported in

between 7% and 29% of patients in different case series.¹ One of the catastrophic vascular presentations of BD is arterial aneurysm formation.² While the abdominal, femoral, and pulmonary arteries are the most prevalent affected arteries, extracranial carotid artery involvement is very rare.³ To the best of our knowledge, there is no consensus yet as to whether

*Corresponding Author: Shahrooz Yazdani, Assistant Professor of Interventional Cardiology, Cardiovascular Research Center, Alborz University of Medical Sciences, Shahid Rajaei Hospital, Rajaei Street, Beheshti Avenue, Karaj, Iran. Tel: +98 263 4502001. Fax: +98 263 4502001. E-mail: Shahrooz1982@yahoo.com.



surgery or endovascular exclusion would be the preferred way of treatment for inflammatory pseudoaneurysms in BD.² In this paper, we discuss the diagnostic dilemma and therapeutic challenges in a patient that presented with a symptomatic large pseudoaneurysm of the carotid artery and was found to have BD.

Case Report

A 40-year-old man was admitted for a left-sided cervical mass, which was painful and pulsatile. In the month preceding his admission, the patient had 2 episodes of right-sided transient ischemic attacks. He denied any history of trauma, surgery, or irradiation to his neck, and he had no known history of systemic disease. He also complained of recurrent urogenital ulcers and aphthous lesions, together with painful rashes on his extremities, of 6 months' duration. On physical examination, there was a pulsatile mass in the left anterior cervical region (Figure 1).

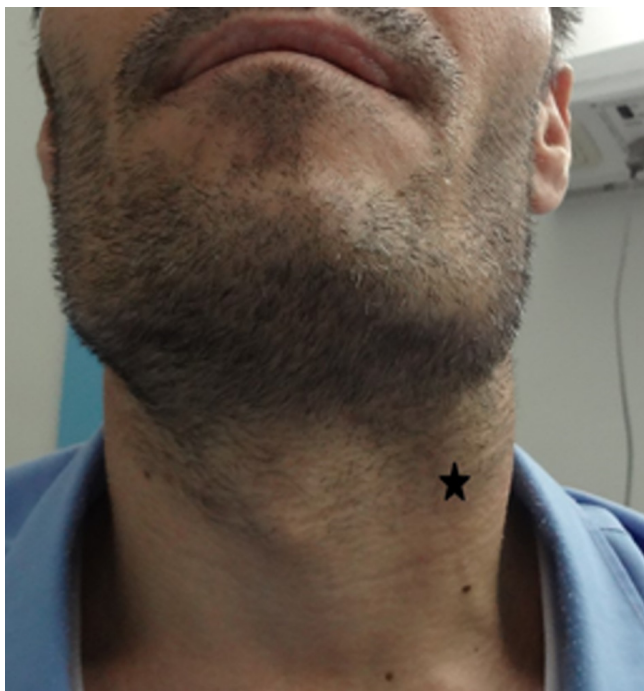

Figure 1. The patient, presenting with a left cervical mass (asterisk) in the anterior view

There was no important problem in his neurological examination. Blood tests showed a high erythrocyte sedimentation rate (49 mm/h, NL<10 mm/h) and a high level of C-reactive protein (3.05 mg/dL, normal <0.5 mg/dL).

In ultrasonography, there was a large pseudoaneurysm in the left common carotid artery (CCA) (Figure 2).

The aneurysm stemmed before the CCA bifurcation, and the external carotid artery origin was spared. Computed tomography angiography of the aorta and its main branches

showed 2 aneurysmal dilations in the left CCA at the bifurcation level with a very large mural thrombus (41×30 mm in diameter) at the anterior aspect of the vessel (Figure 3).

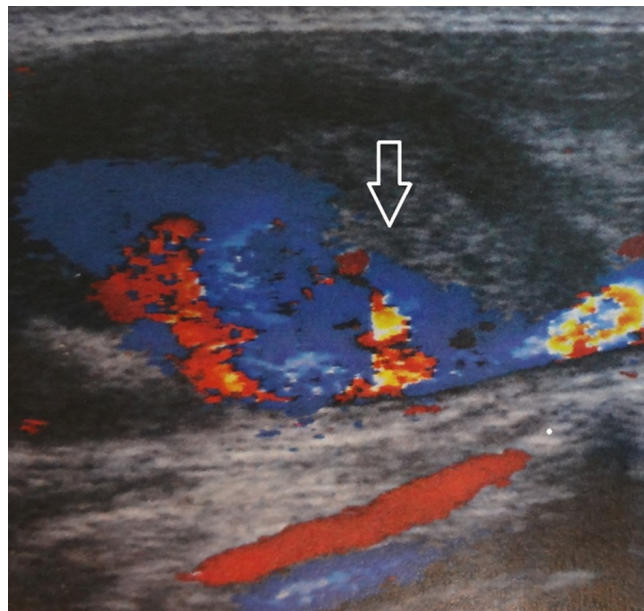


Figure 2. Sonographic image of the left cervical mass, showing a large pseudoaneurysm in the left common carotid artery (arrow)

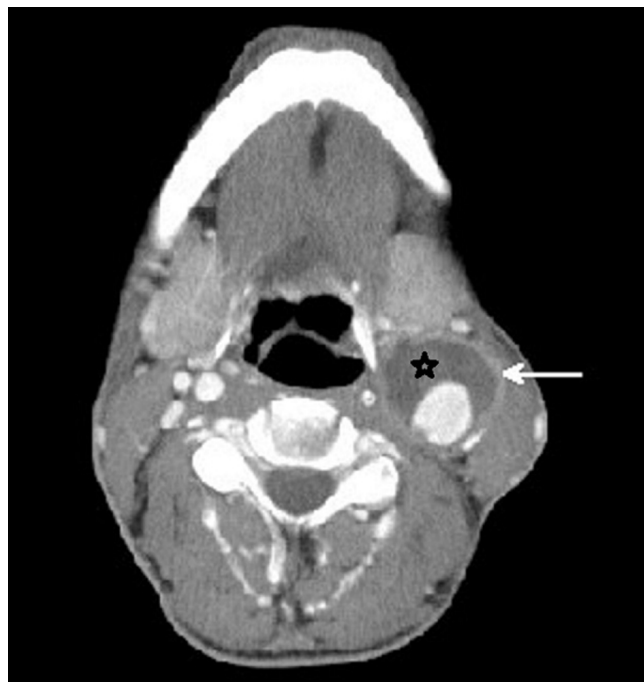

Figure 3. Contrast-enhanced computed tomography scan in the axial view, demonstrating an aneurysm (arrow), 41×30 mm in size, with a very large mural thrombus (asterisk)

The patient was referred to a rheumatologist, who established the diagnosis of BD on the basis of history, the presence of systemic inflammatory reaction, a positive



pathergy test, and ophthalmologic findings of uveitis.

In-depth consultation among the treatment team, consisting of a cardiologist, a cardiac and vascular surgeon, a rheumatologist, and a radiologist, resulted in the decision to choose the endovascular approach after starting immunosuppressive therapy to reduce the risk of stent thrombosis. High-dose corticosteroids and cyclophosphamide were commenced under the close observation of the rheumatologist. After 1 week, the patient's mucocutaneous symptoms resolved, the treatment team decided to exclude the aneurysm via stent graft deployment.

After a selective digital subtraction angiography of the left CCA, a 0.035-inch Terumo guide-wire (Terumo, Tokyo, Japan) was inserted via the femoral access into the left internal carotid artery. The guide-wire was then replaced with a super stiff one, and a 10-F long sheath (Shuttle introducer sheath – Cook Inc., Bloomington, IN) was inserted into the left CCA. Two overlapping self-expanding stent grafts (8×60 and 10×60 mm) were deployed into the left internal carotid artery and the left CCA, consecutively (Fluency, Bard, Covington, Ga). Post-stenting angiography showed a non-flow-limiting iatrogenic dissection flap, 20 mm distal to the position of the stent grafts. Nevertheless, a decision was made to cover the dissection site with a self-expanding 7×30 mm PRECISE Stent (Cordis, Johnson and Johnson, Miami, FL). The final angiogram showed no residual endoleak, and the flow of the carotid and cerebral arteries was satisfactory (Figure 4A and 4B).

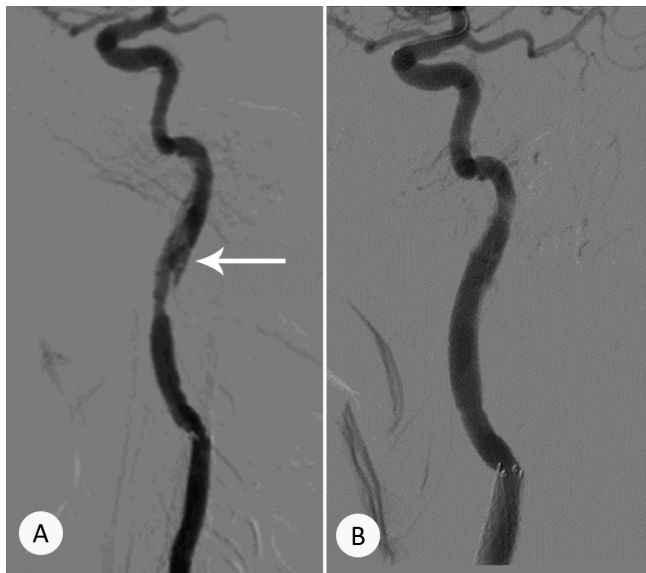

Figure 4. A) Left carotid angiography, showing dissection (arrow) in the internal carotid artery after stent graft placement; B) Final angiography after the deployment of the carotid stent, showing the sealing of the dissection

After the procedure, the pulsating mass of the neck disappeared, and the patient remained symptom-free. He was discharged on medical treatment with the oral

administration of aspirin, Plavix, and prednisolone. Based on the rheumatologist's recommendation, weekly injections of cyclophosphamide were continued after discharge, and the patient was referred for close follow-up visits to a BD clinic run by an expert group of rheumatologists.

The follow-up ultrasonography and computed tomography angiography of the patient 6 months later showed no endoleak or any other problem, and there was significant shrinkage in the aneurysm sac (Figure 5).

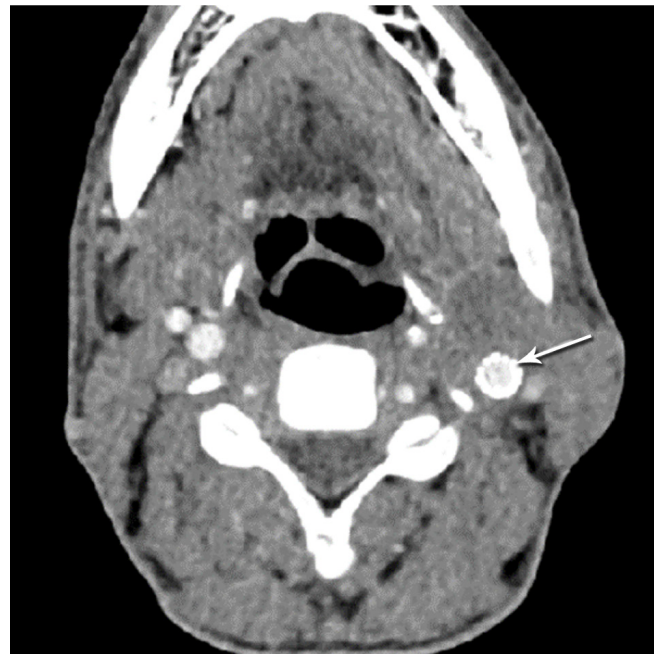

Figure 5. Follow-up computed tomography angiography in the axial view 6 months after the procedure, showing no residual aneurysm as well as the resorption of the mural thrombus (arrow)

Discussion

Our patient was a young man with recent transient ischemic attacks and an enlarging pulsatile mass in the neck, which was strongly in favor of the diagnosis of a carotid aneurysm. The presence of uveitis, typical urogenital aphthous ulcers, skin rashes, the carotid aneurysm, and a positive pathergy test all supported BD as the underlying etiology, which was subsequently confirmed by an experienced rheumatologist.

BD is an uncommon multisystem inflammatory disease with an unknown etiology. Small-vessel vasculitis is the main pathophysiology involved in the natural course of the disease. BD has geographical distributions mostly limited to the Middle East, Mediterranean countries, and East Asia.⁴ In BD, vascular involvement is relatively common. The involvement of both arterial and venous systems is probable; nonetheless, in most cases, venous manifestations predominate.⁵

In the arterial system, the abdominal aorta is the most

common site of involvement, followed by the pulmonary, femoral, popliteal, and carotid arteries in descending order. Arterial involvement in between 2% and 6% of cases results in aneurysm formation.⁶ We previously reported successful endovascular repair of supra-celiac and abdominal aortic pseudoaneurysms concomitant with a right atrial mass in a patient with BD.⁷ To our knowledge, fewer than 20 cases of cervical carotid artery aneurysms associated with BD have been reported in the literature.⁸

Our patient had a symptomatic carotid aneurysm, which mandated definitive therapy. If left untreated, aneurysms in the setting of BD have a high tendency for rupture, which is the primary cause of death in these patients.⁹

Until now, there have been no treatment guidelines based on either scientific evidence or expert consensus for the management of extracranial carotid artery aneurysms. In the past, open surgical repair was most commonly recommended for the management of arterial aneurysms in patients with BD. However, the complication rate of open surgery has been reported to be approximately 50% due to thrombotic occlusion and pseudoaneurysm formation after surgical reconstruction. In addition, skin and connective tissues have inflammation at the site of surgical incisions, rendering open repair a less desirable option.¹⁰ In a study by Hosaka et al.,¹¹ a total of 10 patients with BD underwent open surgery for arterial involvement. During the follow-up period, Hosaka and colleagues observed 5 graft occlusions and 5 anastomotic pseudoaneurysms.

Recent reports have shown that endovascular stent grafting may offer an alternative treatment for arterial aneurysms in BD. Although the first reported patients showed contradicting outcomes, endovascular treatment combined with immunosuppressive therapy has been recently reported to be associated with encouraging postprocedural results and lower recurrence rates than open repair.¹² In 1998, Vasseur et al.¹³ performed the first endovascular treatment in BD to treat aortoiliac aneurysms. In 1999, Bonnotte et al.⁶ presented an internal carotid artery pseudoaneurysm in a patient with BD, which was successfully treated with stent-supported coil embolization. In 2001, Park et al.¹⁴ published a case of double-tandem aneurysms in the CCA, treated with 2 covered stent placements. Nevertheless, Park and associates reported that angiography at 6 months' follow-up illustrated parent artery occlusion. Liu et al.¹⁵ reported 10 patients with pseudoaneurysms due to BD that underwent endoluminal stent graft implantation; they experienced no perioperative complications. However, the authors lost 1 patient 8 months after the procedure due to the rupture of a recurrent aneurysm.

Considering the utmost importance of the suppression of the inflammatory phase of the disease before performing any invasive manipulation, we started immunosuppressive agents 1 week before the endovascular intervention. Both clinical and laboratory examinations improved after the

initiation of the therapy. The erythrocyte sedimentation rate and the C-reactive protein level normalized within 1 week. It is vital to administer immunosuppressive therapy before both surgical and endovascular therapies in BD in order to avoid early treatment failure due to thrombotic events and also recurrent aneurysms.¹³ It is also essential not to deploy endovascular devices in the diseased segments of the artery because maintaining a safety margin would be reasonable. Liu et al.¹⁵ suggested a similar approach. In unstable patients with ruptured pseudoaneurysms in the setting of BD, they initiated immunosuppressive therapy concomitant with endovascular therapy. In stable patients, Liu and colleagues waited for 1 to 3 weeks before definitive therapy to allow the normalization of inflammatory markers.

When covering a pseudoaneurysm, we should pay sufficient heed to the side branch arteries arising from the parent artery so as to avoid type 2 endoleak. The obliteration of the side branch originating from the aneurysmal part of the vessel before main-branch stenting could be a reasonable approach. Nevertheless, in contrast to previous reports, we did not deploy an occluder into the external carotid artery considering the fact that the ostium of the branch was located 3 mm after the ending part of the aneurysmal disease and there was the inherent risk of embolic stroke due to the manipulation of the thrombus inside the CCA.

Conclusion

In light of our experience concerning BD, adequate immunosuppression before surgical or endovascular procedures is mandatory to reduce thrombotic events and also recurrence.

The endovascular approach is less invasive than open surgery, and immunosuppressive therapy may help to prevent the recurrence of aneurysms. Further, prospective studies on a larger scale are warranted.

Acknowledgments

We sincerely thank Professor Fereydoun Davatchi for his invaluable assistance in our patient's rheumatologic management and also Dr. Shapour Shirani for his radiologic expertise.

References

1. Alpogut U, Ugurlucan M, Dayioglu E. Major arterial involvement and review of Behcet's disease. *Ann Vasc Surg* 2007;21:232-239.
2. Iscan, ZH, Vural KM, Bayazit M. Compelling nature of arterial manifestations in Behcet disease. *J Vasc Surg* 2005;41:53-58.
3. Güneş T, Önem G, Taştan H, Alur İ. Rapidly occurring carotid



- artery aneurysm in a patient with Behçet disease. *Ann Vasc Surg* 2015;29:836.e5-8.
4. Shimizu, T. Behçet disease (Behçet syndrome). *Semin Arthritis Rheum* 1979;8:223-260.
 5. Suzuki J, Akashi K, Shimada M, Abe S, Kawakami Y. A case of Behçet's disease with a rapidly enlarging aneurysm in the common carotid artery. *Jpn J Med* 1991;30:251-254.
 6. Bonnotte B, Krause D, Fanton AL, Theron J, Chauffert B, Lorcerie B. False aneurysm of the internal carotid artery in Behçet's disease: successful combined endovascular treatment with stent and coils. *Rheumatology (Oxford)* 1999;38:576-577.
 7. Kassaian SE, Abbasi K, Shirzad M, Anvari MS, Shahrzad M, Molavi B. Endovascular repair of supra-celiac and abdominal aortic pseudo aneurysms concomitant with a right atrial mass in a patient with Behçet's disease: a case report. *J Teh Univ Heart Ctr* 2014;9:179-182.
 8. Bastounis E, Maltezos C, Giambouras S, Vayiopoulos G, Balas P. Arterial aneurysms in Behçet's disease. *Int Angiol* 1994;13:196-201.
 9. Saadoun D, Wechsler B, Desseaux K, Le Thi Huong D, Amoura Z, Resche-Rigon M, Cacoub P. Mortality in Behçet's disease. *Arthritis Rheum* 2010;62:2806-2812.
 10. Sener E, Bayazit M, Göl MK, Mavitas B, Tasdemir O, Bayazit K. Surgical approach to pseudoaneurysms with Behçet's disease. *Thorac Cardiovasc Surg* 1992;40:297-299.
 11. Hosaka A, Miyata T, Shigematsu H, Shigematsu K, Okamoto H, Ishii S, Miyahara T, Yamamoto K, Akagi D, Nagayoshi M, Nagawa H. Long-term outcome after surgical treatment of arterial lesions in Behçet disease. *J Vasc Surg* 2005;42:116-121.
 12. Desbois AC, Wechsler B, Resche-Rigon M, Piette JC, Huong Dle T, Amoura Z, Koskas F, Desseaux K, Cacoub P, Saadoun D. Immunosuppressants reduce venous thrombosis relapse in Behçet's disease. *Arthritis Rheum* 2012;64:2753-2760.
 13. Vasseur MA, Haulon S, Beregi JP, Le Tourneau T, Prat A, Warembourgh H. Endovascular treatment of abdominal aneurysmal aortitis in Behçet's disease. *J Vasc Surg* 1998;27:974-976.
 14. Park JH, Chung JW, Joh JH, Song SY, Shin SJ, Chung KS, Lee DY, Won JY, Kim SJ. Aortic and arterial aneurysms in behçet disease: management with stent-grafts--initial experience. *Radiology* 2001;220:745-750.
 15. Liu CW, Ye W, Liu B, Zeng R, Wu W, Dake MD. Endovascular treatment of aortic pseudoaneurysm in Behçet disease. *J Vasc Surg* 2009;50:1025-1030.