



Anesthetic Management of an Infant Presenting with an Intrapericardial Tumor: A Case Report

Mitra Golmohammadi, MD^{1*}, Shahyad Salehi, MD², Rozita Haghi, MD¹,
Mohammad Radvar, MD³

¹Department of Cardiac Anesthesiology, Urmia University of Medical Sciences, Urmia, Iran.

²Department of Cardiac Surgery, Urmia University of Medical Sciences, Urmia, Iran.

³Department of Pediatrics, Urmia University of Medical Sciences, Urmia, Iran.

Received 09 August 2017; Accepted 12 December 2017

Abstract

Intrapericardial teratomas are rare primary cardiac tumors. These tumors, albeit benign in essence, can be fatal if they exert pressure on the cardiovascular and/or respiratory system. We describe a 34-day-old infant, who needed emergent surgery due to cardiovascular structure compromise. Proper anesthetic and surgical techniques conferred an uneventful postoperative course. Histologic examination confirmed the tumor as an intrapericardial teratoma. At 8 months' postoperative follow-up, the child had a good developmental status and a normal echocardiogram.

J Teh Univ Heart Ctr 2018;13(2):76-79

This paper should be cited as: Golmohammadi M, Salehi S, Haghi R, Radvar M. Anesthetic Management of an Infant Presenting with an Intrapericardial Tumor: A Case Report. *J Teh Univ Heart Ctr 2018;13(2):76-79.*

Keywords: Heart neoplasms • Teratoma • Pericardial effusion • Anesthesia

Introduction

Primary tumors of the heart in infants and children are rare, with an incidence rate of 0.0017% to 0.28%.^{1, 2} Intrapericardial teratomas are the fourth major subgroup of such tumors.³ Cardiac teratomas were first reported in 1890.⁴ Autopsy studies in children have revealed an incidence rate of 0.03% to 0.08%. The ability to detect cardiac tumors noninvasively has led to a clear increase in the diagnosis.⁵ With an embryonic origin, teratomas are composed of elements derived from the 3 germinal layers in varying degrees. If at least 50% of the tumor is comprised of well-differentiated elements, the tumor is referred to as a mature teratoma.³ These tumors are usually benign, and their clinical signs and symptoms depend on the tumor size and location.⁷

They may be diagnosed during fetal life (often in the anterior mediastinum), and they are usually associated with pericardial effusion and hydrops fetalis, or soon after birth with severe cardiorespiratory system compromise.^{6, 8}

Case Report

A 34-day-old female infant, weighing 2.3 kg, was admitted to our institute with severe respiratory distress. Physical examination demonstrated severe tachypnea (respiratory rate = 35-40/min), sweating during breastfeeding, peripheral cyanosis, and indrawing of the chest cavity with inspiration. Chest X-ray revealed only cardiomegaly (Figure 1). Transthoracic echocardiography showed massive pericardial

*Corresponding Author: Mitra Golmohammadi, Assistant Professor, Urmia University of Medical Sciences, Shohada Hospital, 17 Shahrivar Blvd., Urmia, Iran. 57187-48983. Tel: +98 4432375917. Fax: +98 4432375914. E-mail: mitragolmohammadi@yahoo.com.



effusion with a space-occupying mass lesion, 5×4 cm in size, in the pericardial cavity on the right side. Based on the infant's clinical condition and the echocardiographic findings, she was scheduled for emergency tumor removal.

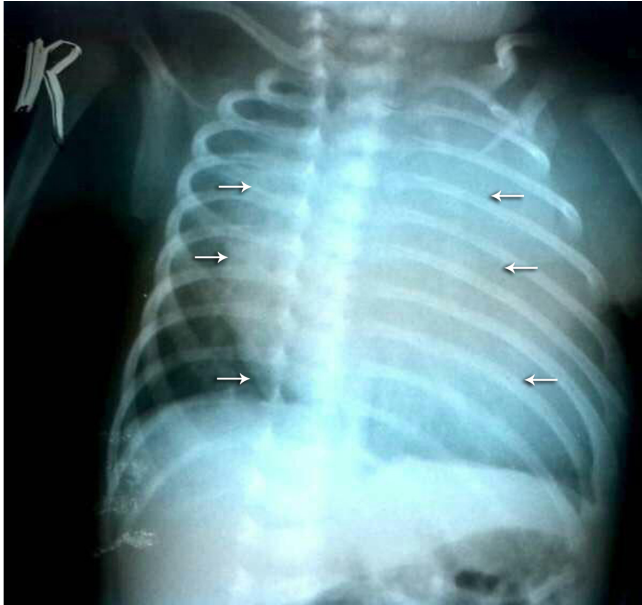

Figure 1. Chest radiograph (anteroposterior view) (revealing cardiomegaly and evidence of a pericardial mass). The arrows show the border of the possible mass.

The preoperative heart rate was between 130 and 140 bpm. The peripheral capillary oxygen saturation (SpO_2) before induction was 88% and after the administration of 100% oxygen with a mask, SpO_2 rose to 94%. Considering the infant's age, severe respiratory distress, and cardiovascular instability, we performed awake-sedate intubation after the administration of 5 μ g of fentanyl and topicalization of the tongue, larynx, and vocal cords with 15 mg of 1.0% lidocaine and a 3.0-mm Portex tracheal tube. Subsequently, the general anesthesia was maintained with a mixture of oxygen/air, isoflurane, 1-mg increments of atracurium, and 5 μ g of fentanyl intermittently. Thereafter, an arterial line and a central venous line were established. Other monitoring modalities such as the bispectral index (BIS), capnograph, and pulse oximetry were utilized as well. Extracorporeal circulation was on standby. Via a median sternotomy with the preservation of the thymus gland, the pericardium was opened and a large quantity of cloudy yellow fluid was aspirated. A multicystic lesion, around $50 \times 45 \times 30$ mm in size, was revealed. It covered most of the right ventricle and pressed on the right atrium (Figure 2 and Figure 4). Furthermore, the mass was polycystic and attached to the right anterior wall of the ascending aorta. The whole tumor was successfully removed. The patient was extubated in the intensive care unit on the first postoperative day and was discharged from the hospital on the fifth postoperative day.

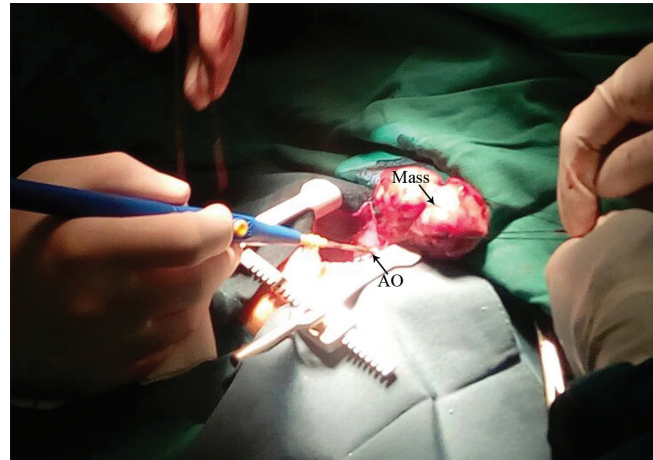


Figure 2. Intraoperative image of the teratoma after opening the pericardium, showing that the mass is adherent to the AO.

AO, Ascending aorta

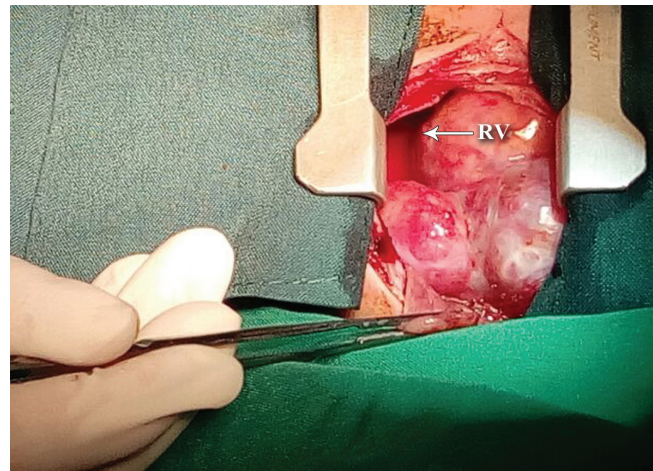


Figure 3. Intraoperative view of the large intrapericardial teratoma, showing that it covers most of the RV.

RV, Right ventricle

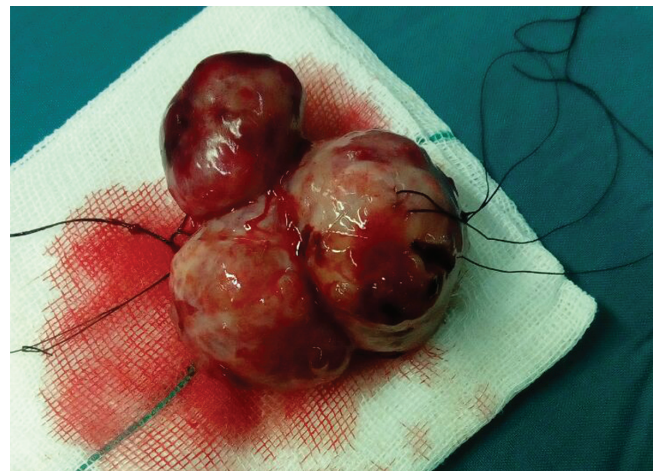


Figure 4. Macroscopic appearance of the mass (multicystic lesion)

Histologically, it was a mature teratoma with the

representation of all 3 germinal layers: endoderm 50%, mesoderm 25%, and ectoderm 25%.

Discussion

Intrapericardial tumors are usually diagnosed in neonates and infants; nonetheless, they may be discovered in the fetal life period. Typically, not only are they lone tumors but also they are large and polycystic with a capsule and a pedicle. Tumor adhesion to the heart itself and/or the great vessels (aorta or pulmonary arteries) is relatively common.^{9,10} Most of the time, the tumor is benign and often associated with massive pericardial effusion, cardiac compression, and even severe cardiorespiratory distress.¹¹ Herein we described a patient with a pericardial tumor who developed massive pericardial effusion and severe respiratory distress. The hypothesis is that a small patent communication between the cyst and the pericardium results in pericardial effusion and this connection is later on spontaneously sealed by obliterative fibrosis.¹² Echocardiography is the first imaging diagnostic tool, although magnetic resonance imaging has a better ability to illustrate the anatomical relationship between the intrapericardial tumor and the adjacent vital structures.¹³ Intrapericardial tumors perpetually pose a challenge to both anesthesiologists and surgeons. Anesthesiologists should expect airway obstruction or hemodynamic instability during the induction of anesthesia, which may be unresponsiveness to any treatment except the immediate excision of the mass. However, hemodynamic instability may occur during heart and tumor manipulation.^{14,15} Large pericardial tumors may act as an anterior mediastinal mass, which could press the lung, superior vena cava, and pulmonary artery.¹⁶ The choice of the anesthetic technique depends on the effects of the tumor on the patient's hemodynamic and clinical status. There is some evidence lending support to the use of specific anesthetic methods.^{17,18} Since our patient was a 34-day-old infant with severe respiratory distress and cardiovascular instability, our anesthetic management was awake-sedate intubation without the use of bag-and-mask-ventilation and loss of consciousness. Subsequently, we maintained the general anesthesia with a mixture of oxygen/air, isoflurane, muscle relaxant, and fentanyl. Fortunately, we encountered no unpleasant event during the perioperative period.

In our patient, although the teratoma was anchored to the ascending aorta and thus caused pressure on the right atrium, we achieved its complete removal. The postoperative period was uneventful, with the patient being extubated on the first postoperative day in the intensive care unit and then discharged home on the fifth postoperative day. Microscopic examination of the specimen yielded a definitive diagnosis. The surgical removal of such tumors is not only curative but also lifesaving because failure to achieve a prompt removal of these lesions can prove fatal. Our patient's prognosis was

good insofar as at 8 months' postoperative follow-up, she had a good developmental status and a normal echocardiogram.

Conclusion

Intrapericardial teratomas are rare; they should, however, be included in the differential diagnosis of a newborn or infant presenting with respiratory distress. Intrapericardial teratomas should be removed as soon as they are detected because, despite their inherent benignity, they can be potentially fatal.

References

1. Uzun O, Wilson DG, Vujanic GM, Parsons JM, De Giovanni JV. Cardiac tumours in children. *Orphanet J Rare Dis* 2007;2:11.
2. Wang JN, Yao CT, Chen JS, Yang YJ, Tsai YC, Wu JM. Cardiac tumors in infants and children. *Acta Paediatr Taiwan* 2003;44:215-219.
3. Becker AE. Primary heart tumors in the pediatric age group: a review of salient pathologic features relevant for clinicians. *Pediatr Cardiol* 2000;21:317-323.
4. De Geeter B, Kretz JG, Nisand I, Eisenmann B, Kieny MT, Kieny R. Intrapericardial teratoma in a newborn infant: use of fetal echocardiography. *Ann Thorac Surg* 1983;35:664-666.
5. Zhou QC, Fan P, Peng QH, Zhang M, Fu Z, Wang CH. Prenatal echocardiographic differential diagnosis of fetal cardiac tumors. *Ultrasound Obstet Gynecol* 2004;23:165-171.
6. Roy N, Blurton DJ, Azakie A, Karl TR. Immature intrapericardial teratoma in a newborn with elevated alpha-fetoprotein. *Ann Thorac Surg* 2004;78:e6-8.
7. Laquay N, Ghazouani S, Vaccaroni L, Vouhé P. Intrapericardial teratoma in newborn babies. *Eur J Cardiothorac Surg* 2003;23:642-644.
8. Arciniegas E, Hakimi M, Farooki ZQ, Green EW. Intrapericardial teratoma in infancy. *J Thorac Cardiovasc Surg* 1980;79:306-311.
9. Reynolds JL, Donahue JK, Pearce CW. Intrapericardial teratoma: a cause of acute pericardial effusion in infancy. *Pediatrics* 1969;43:71-78.
10. Reddy SC, Fenton KM, Gandhi SK, Lanford LM, Pigula FA. Intrapericardial teratoma in a neonate. *Ann Thorac Surg* 2003;76:626.
11. Marx GR. Intrapericardial teratomas. In: Emanouilides GC, Riemenschneider TA, Allen HD, Gutgesell HP, eds. *Heart Disease in Infants, Children and Adolescents, Including the Fetus and Young Adult*. 5th ed. Baltimore/Philadelphia/London: Williams and Wilkins; 1995. p. 1780-1782.
12. Bandeira FC, de Sá VP, Moriguti JC, Rodrigues AJ, Jurca MC, Almeida-Filho OC, Marin-Neto JA, Maciel BC. Cardiac tamponade: an unusual complication of pericardial cyst. *J Am Soc Echocardiogr* 1996;9:108-112.
13. Beghetti M, Prieditis M, Rebeyka IM, Mawson J. Images in cardiovascular medicine. Intrapericardial teratoma. *Circulation* 1998;97:1523-1524.
14. Ragupathy R, Nemeth L, Kumaran V, Rajamani G, Krishnamoorthy P. Successful surgical management of a prenatally diagnosed intrapericardial teratoma. *Pediatr Surg Int* 2003;19:737-739.
15. Kumar IH, Shrote V, Kumar H. Anaesthetic management of a child presenting with intrapericardial teratoma compressing the airway and the heart. *Ann Card Anaesth* 2009;12:63-66.
16. Slinger P, Karsli C. Management of the patient with a large anterior mediastinal mass: recurring myths. *Curr Opin Anaesthesiol* 2007;20:1-3.



17. Cerza RF. Cardiac masses: clinical and anesthetic correlations. *J Cardiothorac Vasc Anesth* 1994;8:441-445.
18. Johns RA, Kron IL, Carey RM, Lake CL. Atrial myxoma: case report, brief review, and recommendations for anesthetic management. *J Cardiothorac Anesth* 1988;2:207-212.