



Echocardiographic Evaluation of Intracardiac Masses

Maryam Esmailzadeh, MD, FCAPSC*

Shaheed Rajaie Cardiovascular Medical and Research Center, Tehran, Iran.

Abstract

Echocardiography plays a fundamental role in the evaluation of patients with an intracardiac mass. The ability to distinguish tissue characteristics, location, attachment, shape, size, and mobility non-invasively, quickly, and without the use of ionizing radiation makes echocardiography the ideal diagnostic modality. With careful attention to mass location and morphology, and appropriate application of clinical information, echocardiography can usually distinguish between the three principal intracardiac masses: tumor, thrombus, and vegetation. Equivocal transthoracic findings typically indicate the need for a transesophageal evaluation, during which the atria and great vessels might be better imaged. Surgical intervention is often indicated based on possible echocardiographic findings, without the need for additional time-consuming procedures. This review will focus on cardiac tumors.

J Teh Univ Heart Ctr 2 (2008) 59-76

Keywords: Echocardiography • Heart • Tumors • Diagnostic imaging

Introduction

Neoplasms of the heart divided into primary cardiac tumors arising in the heart and secondary cardiac tumors that have metastasized to the heart. Primary cardiac tumors stratified into benign and malignant tumors. Secondary involvement of the heart is relatively uncommon; 10% to 20% of patients dying of disseminated cancer have metastatic involvement of the heart or pericardium.^{1,2} Primary tumors of the heart are uncommon but not rare. The incidence of primary cardiac neoplasm ranges between 0.17% and 0.19% in unselected autopsy series.³⁻⁸ Approximately 75% of primary cardiac tumors are benign and 25% are malignant.^{2,9} Approximately 50% of the benign tumors are myxomas, and about 75% of the malignant tumors are sarcomas.^{2,9} Echocardiography is an invaluable technique for the evaluation of intracardiac masses,

and can reliably identify mass location, attachment, shape, size, and mobility, while defining the presence and extent of any consequent hemodynamic derangement. With careful attention to mass location and morphology, and appropriate application of clinical information, echocardiography can usually distinguish between the three principal intracardiac mass lesions: tumor, thrombus, and vegetation. Transesophageal imaging frequently adds additional important information to the assessment of masses and should always be considered when image quality is inadequate or pertinent clinical questions remain unanswered with surface imaging. It can be performed at the bedside, operating theater and in critically ill patients. However, echocardiographic image quality can be suboptimal, and ultrasound artifacts

*Corresponding Author: *Maryam Esmailzadeh, Shaheed Rajaie Cardiovascular Medical and Research Center, Tehran, Iran. Tel: +98 21 23922524. Fax: +98 21 22055594. E-mail: meszadeh@rhc.ac.ir*

can occasionally be mistaken for an anatomic mass. Careful identification of a mass lesion throughout the cardiac cycle in more than one imaging plane is an important first step in evaluating a suggested mass, and will decrease the likelihood of misinterpreting artifact as pathology.

A thorough understanding of normal anatomy, normal variants, embryologic remnants, and the structural changes seen with certain operative and interventional procedures is crucial and will further avoid misdiagnosis. Finally, it is important that clinical and historic information be available and thoughtfully applied to the final echocardiographic interpretation.

Normal variants

Numerous normal anatomic variants exist that can easily be confused with primary mass lesions. In the left ventricle, webs and chords, prominent or calcified papillary muscles, prominent apical trabeculations, and dense mitral annular calcification (Figure 1) can mimic abnormal pathology. Ventricular noncompaction (Figure 2) and the apical form of hypertrophic cardiomyopathy can also be confused with tumors.¹⁰⁻¹³

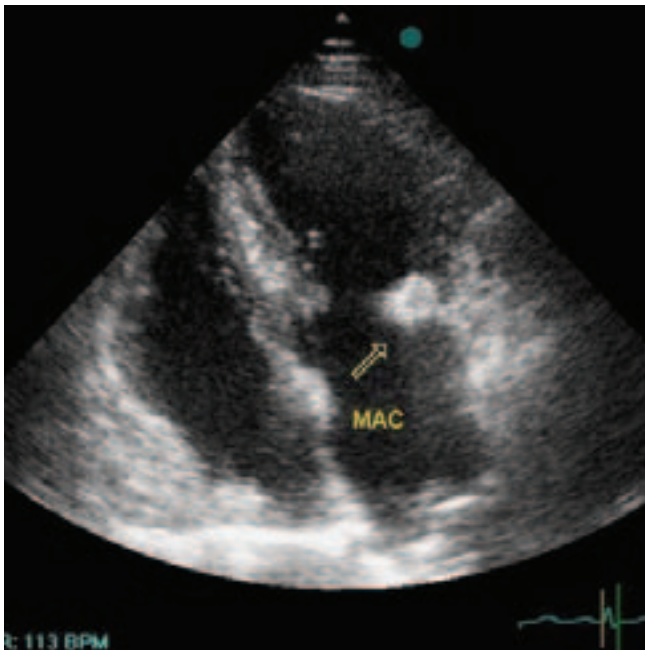


Figure 1. Mitral annular calcification (MAC); apical four-chamber view showing significant calcification of posterior mitral annulus (arrow)

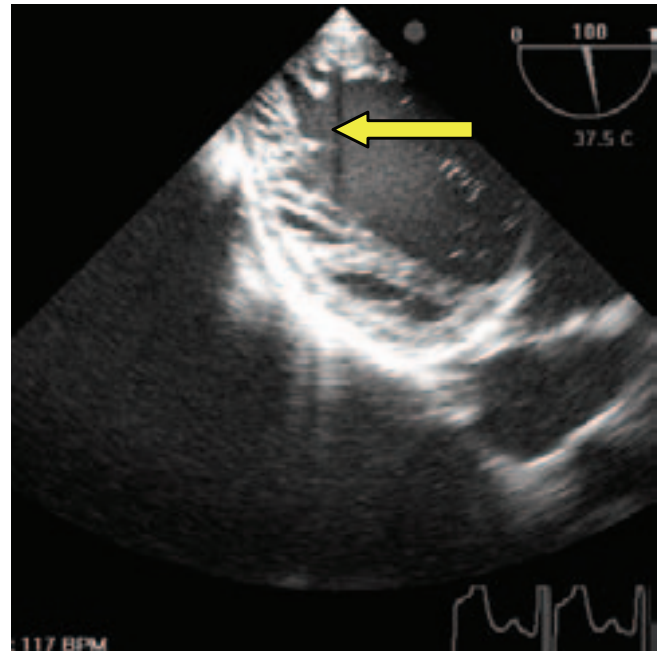


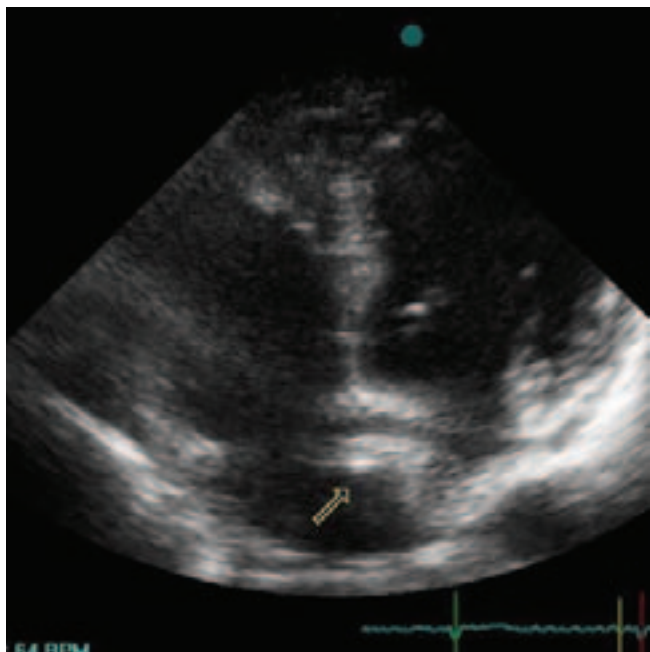
Figure 2. Non-compaction left ventricle; transgastric view showing markedly thickened two-layered myocardial wall with multiple trabeculations and deep intertrabecular recesses (arrow)

In the left atrium, beam-width artifacts can cause interpretive confusion, as can the suture lines associated with cardiac transplantation. Left atrium cords are rare but well-recognized findings. These cords typically originate at the atrial septum and insert into the atrial surface of the mitral leaflets; no clinical significance has ever been described. These cords should not be confused with true obstructive cor triatriatum. An interatrial septal aneurysm may appear as a cystic mass bulging into either atrium. A dilated coronary sinus can mimic an LA mass in the parasternal long axis view, as can a prominent descending aorta from the apical view. A left arm injection of agitated saline will define a persistent left superior vena cava draining into the coronary sinus, which is the most common structural anomaly associated with the dilatation of the coronary sinus. When a large accumulation of pericardial fluid is present, the transverse sinus can become prominent.

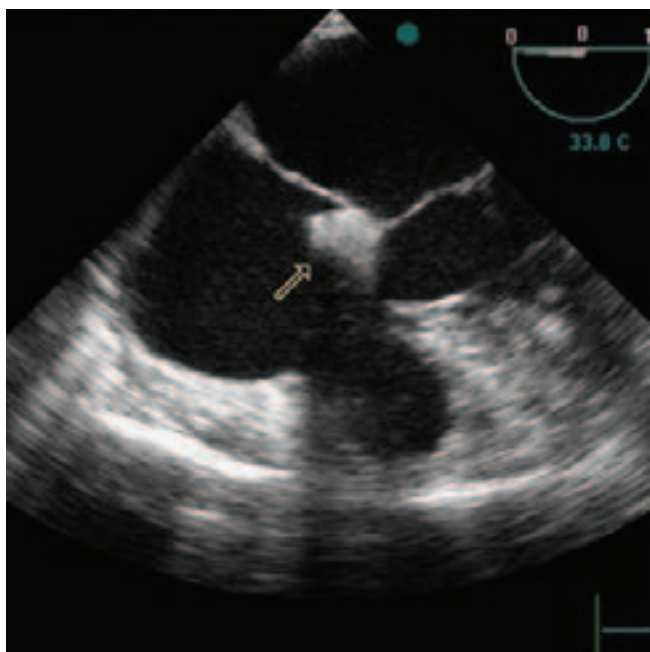
Pectinate muscles in the appendage can mimic a thrombus. An inverted left atrium appendage (a postoperative finding) can also be confused with a tumor.^{14,15} A hiatal hernia can impinge on both atria and can be confirmed after ingestion of carbonated beverage.

A prominent moderator band or tricuspid papillary muscles can create diagnostic confusion in the right ventricle. A fatty tricuspid annulus can be quite prominent. A substantial number of congenital remnants are seen in the right atrium, all of which can create diagnostic confusion.

The crista terminalis is a dense muscle ridge that extends between the right sides of the superior and inferior caval orifices and continues cephalad to open into the right atrium appendage (Figure 3).



A



B

Figure 3. Prominent crista terminalis (arrows); transthoracic (A) and transesophageal (B) views

It can be quite prominent but is commonly seen in the same image plane as the superior vena cava, which should be a clue to its identity.¹⁶ The Eustachian valve is an incompetent valve flap of variable thickness and mobility at the orifice of the inferior vena cava.

The Chiari network is a network of both coarse and fine fibers with attachments extending from the region of the crista terminalis to the Eustachian valve or floor of the right atrium (Figure 4).

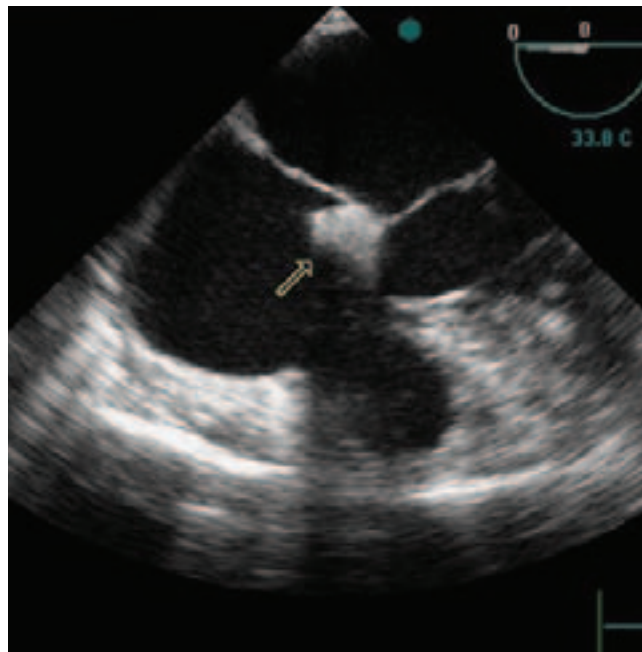


Figure 4. The Chiari network (arrow); transesophageal view

These fibers may become the site of thrombus formation or a catheter entrapment, requiring thoracotomy for retrieval; several recent reports describe entanglement of an atrial septal defect closure device and septal ablation guide wire in the Chiari network.¹⁷⁻¹⁹

Pectinate muscles can be seen on the right atrium appendage and the right atrium free wall and, when prominent, can mimic a thrombus. Venous varicose (clumps of veins) of the heart, rare lesions of unknown incidence and with no distinct or specific echocardiographic characteristics, are surprisingly well described in the pathology literature.²⁰ They almost always occur in the right atrium at the posteroinferior border of the fossa ovalis. They are clumpy, dilated venous channels with irregular borders.²¹

Monitoring lines and pacer wires will also be evident in the right atrium and can occasionally become coiled, simulating a mass.

Fatty infiltrates of the atrial septum, termed as lipomatous hypertrophy, are preferential to the right atrium. Although they can occasionally be quite prominent (>6 cm), they should be distinguishable from a tumor by their typical location and shape.

Certain valvular structures can be confused with mass lesions as well. The nodules of Arantius and Lunula and the threadlike Lambl's excrescences (Figure 5), which are commonly found on the aortic valve in patients older than 60 years, can be confused with vegetations. Redundant supporting apparatus and redundant leaflet tissue of the mitral valve may mimic vegetations as well. Thoughtful application of clinical information is necessary to distinguish

degenerative from infectious processes. Excess epicardial fat may be confused with a tumor contained in the pericardium, as can fibrinous debris in the free pericardial fluid. Atelectatic segments of the lung can be misinterpreted as primary masses in the pleura.

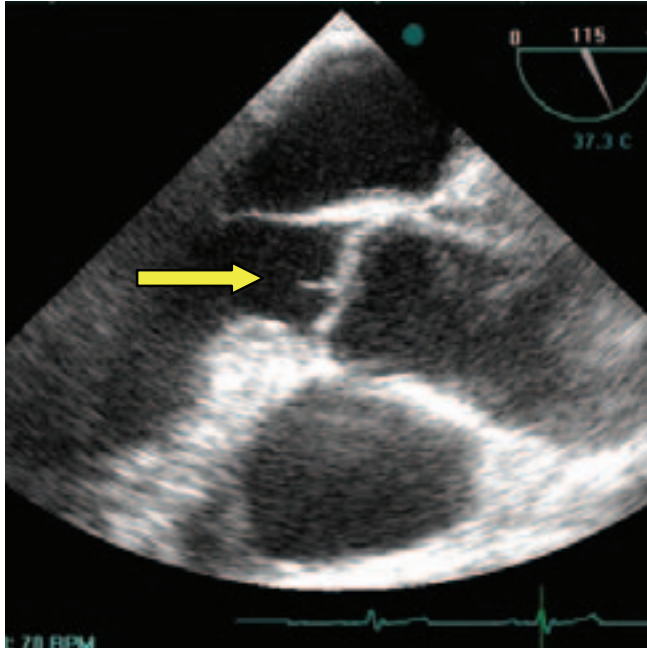


Figure 5. Lambl's excrescence of the aortic valve; mid esophageal long-axis view of the Aorta (arrow)

Primary tumors

A primary cardiac neoplasm was first described by Realdo Colombo in 1559.^{22,23} Primary tumors of the heart and pericardium are difficult to diagnose because they are so uncommon and because their clinical presentation is so variable. The incidence of primary tumors at autopsy ranges from 0.002% to 0.3%.^{24,25} Approximately, 75% of primary cardiac tumors are benign. In adults, the most common cardiac tumor is the myxoma; in children younger than 15 years, the most common tumor is the rhabdomyoma.²⁵ Of the primary malignant tumors, sarcomas are by far the most common, including angiosarcoma, rhabdomyosarcoma, and fibrosarcoma. Mesothelioma and primary intracardiac lymphoma comprise approximately 6% of the malignant tumors of the heart.²⁶ Primary malignant cardiac tumors are rare in children.

Myxoma

Myxomas comprise 25% of all cardiac neoplasms and 50% of benign cardiac tumors in adults but only 15% of such tumors in children. Myxomas usually occur sporadically and

are more common in women than men.^{4,27}

The peak incidence is between the third and sixth decades of life, and 94% of tumors are solitary.²⁸ Tumors are unlikely to be associated with other abnormal conditions and have a low recurrence rate.^{4,28} However, they can be familial or complex (syndrome myxoma). Less than 10% of myxoma patients show a familial pattern based on autosomal dominance inheritance.²⁹⁻³⁰ These patients and 20% of those with sporadic myxomas have an abnormal DNA genotype chromosomal pattern.³¹ In contrast to "typical" sporadic myxomas, familial myxoma patients are more likely to be younger, equally likely to be male and female, and more often (22%) have multicentric tumors originating from either the atrium or the ventricle.³²⁻³⁷

Familial myxomas have a higher recurrence rate after surgical resection (21% - 67%).^{33,38,39} The familial variety may be part of a syndrome (Carney's complex, NAME, LAMB), frequently includes multiple tumors in several chambers, and has a high rate of tumor recurrence.²⁴ If the patient is young with multiple tumors, the screening of first-degree relatives is indicated. The complex variety, also known as Carney's complex, may include a combination of the following: (1) multiple pigmented skin lesions (lentiginos), (2) breast adenomas, (3) skin myxomas, (4) endocrine overactivity (e.g. pituitary adenomas), and (5) cardiac myxomas, often multiple.^{40,41} Syndrome myxomas are also occasionally referred to as the NAME syndrome (nevi, atrial myxoma, myxoid neurofibroma, and ephelides) or the LAMB syndrome (lentiginos, atrial myxoma, and blue nevi).⁴¹

Myxomas occur in any chamber of the heart but have a special predilection for the left atrium, from which approximately 75% originate (Figure 6).⁴²

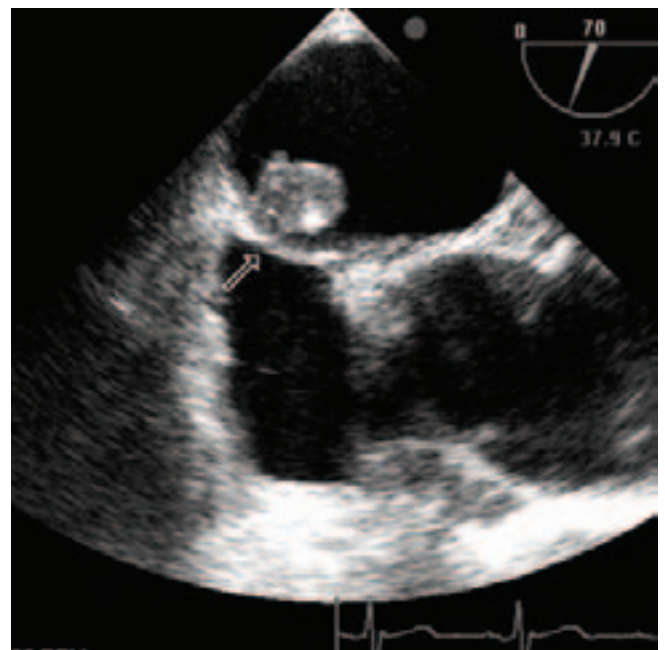


Figure 6. Large left atrial myxoma; transesophageal long-axis view showing the attachment of the tumor to the fossa region (arrow)



The next most frequent site is the right atrium, where 15-20% are found. The remaining 6% to 8% are equally distributed between the left and right ventricles.² Both biatrial and multicentric tumors are more common in familial disease. Biatrial tumors probably arise from the bidirectional growth of a tumor originating within the atrial septum.⁴³ Atrial myxomas generally arise from the interatrial septum at the border of the fossa ovalis but can originate anywhere within the atrium including the appendage.⁴ In addition, isolated reports confirm that myxomas arise from the cardiac valves, pulmonary artery and vein, and vena cava.^{44,45} Right atrial myxomas are more likely to have broad-based attachments than left atrial tumors; they also are more likely to be calcified and thus visible on chest radiographs.^{34,35} Ventricular myxomas occur more often in women and children and may be multicentric.^{2,46} Right ventricular tumors typically arise from the free wall, and left ventricular tumors tend to originate in the proximity of the posterior papillary muscle.

Grossly, about two thirds of myxomas are round or oval tumors with a smooth or slightly lobulated surface.²⁷ Most are polypoid, relatively compact, pedunculated, and mobile.^{2,4} Mobility depends on the length of the stalk and the extent of attachment to the heart.⁴ Sessile forms are unusual (approximately 10%).^{2,47} Less common villous or papillary myxomas are gelatinous and fragile and prone to fragmentation and embolization, occurring about in one third.^{27,48} Focal areas of hemorrhage, cyst formation, or necrosis may be seen. The average size is about 5 cm in diameter but growth to 15 cm in diameter and larger has been reported. Most myxoma tumors appear to grow rapidly, but growth rates vary and occasionally tumor growth arrests spontaneously.⁴ Weights range from 8 to 175 g with a mean between 50 and 60 g.⁸ Work by Malekzadeh and Roberts suggests that myxomas grow on average 1.8 cm or 14 g each year.⁴⁹

The classic triad of myxoma clinical presentation is intracardiac obstruction with congestive heart failure (67%), signs of embolization (29%), systemic or constitutional symptoms of fever (19%) and weight loss or fatigue (17%), and immunologic manifestations of myalgia, weakness, and arthralgia (5%), with almost all patients presenting with one or more of these symptoms.²⁷

Cardiac rhythm disturbances and infection occur less frequently. Myxomas in the left atrium tend to mimic mitral valvular heart disease. Large myxomas may interfere with mitral leaflet closure and produce mitral regurgitation. Syncopal episodes occur in some patients and are thought to result from the temporary occlusion of the mitral orifice.^{35,50,52} Right atrial myxomas can produce a clinical picture of right heart failure with signs and symptoms of venous hypertension,

including hepatomegaly, ascites, and dependent edema. The tumor simulates tricuspid valve stenosis by partially obstructing the valve orifice.^{35,50-52} Systemic embolization occurs in 30% to 40% of patients.^{2,4,35,50,51} Because the majority of myxomas are left-sided, approximately 50% of embolic episodes affect the central nervous system owing to both intracranial and extracranial vascular obstruction.

Surgical removal of all varieties of myxomas is the treatment of choice. Echocardiography is very useful for the diagnosis and evaluation of myxomas. The sensitivity of 2-D echocardiography for myxomas is 100%.⁵³

Color flow and spectral Doppler are useful to evaluate functional obstruction to LA emptying. Transthoracic echocardiography usually provides all the information for surgical resection, but transesophageal echocardiography provides the best information concerning tumor size, location, mobility, and attachment.⁵⁴⁻⁵⁵ Transesophageal echocardiography detects tumors as small as 1–3 mm in diameter.⁵⁶ Additionally, intraoperative transesophageal echocardiography post-tumor excision is indicated to identify any residual tumor fragments prior to leaving the operating room. Recurrence of nonfamilial sporadic myxomas is approximately 1% to 4%.^{4,57,58} Many large series report no recurrent tumors.^{44,57,59,60} The disease-free interval averages about 4 years and can be as brief as 6 months.⁵⁷ Most recurrent myxomas occur within the heart, in the same or different cardiac chambers, and may be multiple.^{35,61,62}

The extent to which patients should be subjected to long-term echocardiographic surveillance after myxoma resection is not standardized.

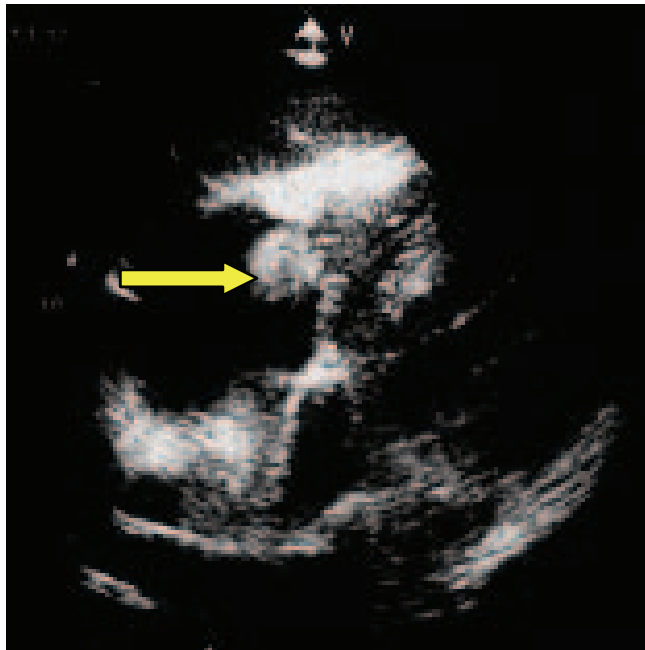
It would seem prudent to closely follow patients who are treated initially for multicentric tumors, those whose tumors are removed from unusual locations, tumors believed to have been incompletely resected, and those with abnormal DNA genotype.

Other benign cardiac tumors

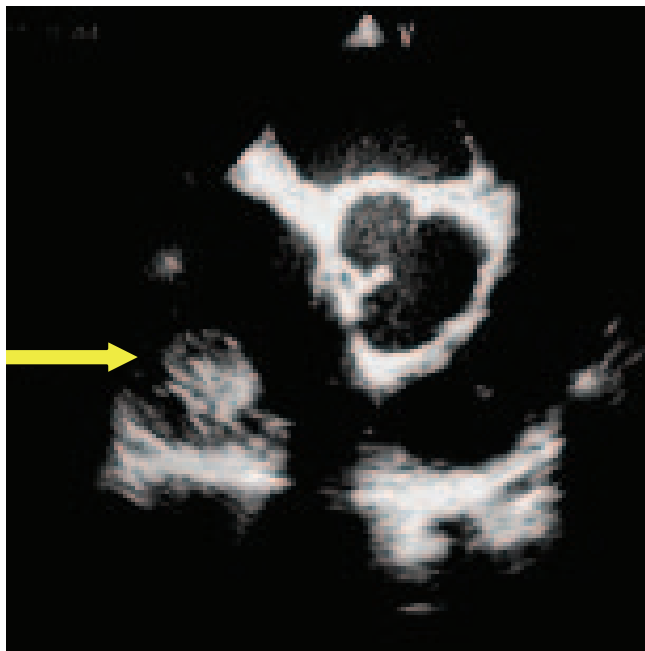
Lipomas, papillary fibroelastomas, and rhabdomyomas are the most common benign tumors.

Papillary fibroelastoma

Papillary fibroelastomas are rare, primary benign cardiac tumors that are most frequently located in the cardiac valves or adjacent endocardium (Figure 7).⁶³



A



B

Figure 7. Papillary fibroelastoma of the tricuspid valve; transthoracic subcostal view (A) and transesophageal view (B) showing large fibroelastoma attached to atrial surface of the anterior tricuspid valve leaflet (arrows)

Fibroelastomas are usually found by chance in post-mortem examinations. It is now known that they are capable of producing the obstruction of the flow, particularly the coronary ostial flow, and may embolize to the brain and produce stroke.⁶⁴⁻⁶⁶ They are usually asymptomatic until a critical event occurs. The prompt detection of papillary fibroelastomas is, therefore, of great importance. They are

potential causes of systemic emboli, stroke, myocardial infarction, and sudden death.⁶⁷⁻⁶⁹ Right-sided localization is even rarer.⁷⁰ In order of frequency, they are the third primary cardiac tumors after myxomas and lipomas.⁷¹ Papillary fibroelastomas represent 7.9% of benign primary cardiac tumors in adults.⁶³ Approximately, 90% of primary fibroelastomas arise from the valvular tissue, most commonly from the aortic or mitral valves.^{72,73}

In a study including 162 patients with papillary fibroelastomas, the age ranged from 5 to 86 (mean 60 ± 16 years).⁷⁴ They may be single or multiple occurring more frequently on the ventricular surface of the semi lunar valve and on the atrial surface of atrioventricular valves and may be pedunculated with some mobility.^{75,76} The tricuspid valve is most affected in children and the mitral and aortic valves in adults.⁷⁶ On gross anatomical examination, they resemble a sea anemone, consisting of multiple fingerlike fronds. The pathogenesis of papillary fibroelastomas remains under discussion, but several possible explanations have been reported, including previous mechanical damage to the endothelium, iatrogenic factors, organizing thrombi, and a latent infectious mechanism due to cytomegalovirus.^{72,77,78} With the advent of echocardiography, an increasing number of papillary fibroelastomas have been diagnosed. Typical echocardiographic features include the following:

1. Round, oval, or irregular appearance, with well-demarcated borders and a homogenous texture.
2. Small mobile stalks in 50%. Those with stalks are mobile.^{74,79}

Sun et al. found that 99% of papillary fibroelastomas were <20 mm in the largest diameter.⁷⁴ The largest reported one is 53 mm.⁸⁰ Even though papillary fibroelastomas are classified as benign cardiac tumors, they often cause systemic embolic events such as cerebrovascular stroke and more rarely myocardial infarction.⁸¹ This occurs because of their very friable and soft texture as well as the creation of thrombi on their surface, which may later become embolic. Echocardiography is a reliable means of evaluating the extent and anatomic attachment of these very small tumors, but many go undetected. There are no significant characteristics that enable the differentiation of fibroelastomas from degenerative valve disease. Surgical excision may be indicated in patients with large, mobile, left-sided tumors. Surgical removal of right-sided papillary fibroelastomas in asymptomatic patients is indicated only for large mobile tumors. The presence of a patent foramen ovale with a sizable right to left shunt is an additional consideration for right-sided fibroelastomas. Asymptomatic patients with small left-sided non-mobile (no stalk) fibroelastomas are usually observed. However, fibroelastomas ≥ 1 cm, especially if mobile, should be considered for excision, including in patients with other cardiovascular diseases, young patients with low risk of surgery, and those with a high cumulative risk for embolization.⁷⁴



Rhabdomyoma

Rhabdomyomas are the most common cardiac tumors of infants and young children. They usually present during the first few days after birth. They are thought to be a myocardial hamartoma rather than a true neoplasm.⁸² They have a strong association with tuberous sclerosis, a familial neurologic syndrome characterized by hamartomas, epilepsy, mental retardation, sebaceous adenomas, and skin lesions. One study indicated that 80% of patients with cardiac rhabdomyomas had tuberous sclerosis, and 60% of patients with tuberous sclerosis younger than 18 years had cardiac rhabdomyomas.⁸³ The exceptional patient is one with a solitary, single rhabdomyoma who does not have or develop tuberous sclerosis. Over 90% of rhabdomyomas are multiple and occur with approximate equal frequency in both ventricles.⁸³⁻⁸⁵

The atrium is involved in fewer than 30% of patients. Pathologically, these tumors are firm, gray, and nodular and tend to project into the ventricular cavity. The most common presentation is heart failure caused by tumor obstruction of the cardiac chambers or valvular orifice flow. Clinical findings may mimic valvular or subvalvular stenosis. Arrhythmias, particularly ventricular tachycardia and sudden death, may be a presenting symptom.

Atrial tumors may produce atrial arrhythmias.⁸⁶ When associated with mechanical complications such as outflow tract obstruction, surgical excision may be indicated. However, surgical intervention is usually not necessary in the asymptomatic patient.^{87,88}

Fibroma

Fibromas are the second most common benign cardiac tumors, with over 83% occurring in children; most are diagnosed by age 2 years. These tumors are solitary, occur exclusively within the left ventricle and the ventricular septum, and are typically intramural.²⁴ They commonly invade the septum, anterior apex, and free wall; and may appear as markedly disproportionate, irregular hypertrophy.

They affect both sexes equally. Fibromas are non-encapsulated, firm, nodular, gray-white tumors that can become bulky. Calcium deposits or bone may occur within the tumor and occasionally are seen in radiography. These tumors are histologically benign but frequently have a malignant course. The majority of fibromas produce symptoms through chamber obstruction, interference with contraction accounting for lethal ventricular dysrhythmia, and intractable heart failure associated with dyspnea and fatigue.⁸⁹⁻⁹¹

Depending on size and location, they may interfere with valve function, obstruct flow paths, or cause sudden death from conduction disturbances in up to 25% of patients.⁹² Fibromas localized to the apex can be confused with thrombus

or true apical hypertrophy, but perhaps can be distinguished by their abnormal texture. Intracardiac calcification on chest roentgenograms suggests the diagnosis, which is confirmed by echocardiography. Although successful surgical resection is common now, these tumors can be extensively infiltrative, and it is not always possible to completely remove the tumor and partial removal is only palliative and may cause further myocardial dysfunction.^{92,93} Successful, complete excision is curative.^{93,94}

Children with extensive fibromas have been treated by cardiac transplantation.^{90,95,96}

Lipoma

Lipomas are well-encapsulated tumors composed of mature fat cells, and may occur anywhere in the heart (Figure 8).²

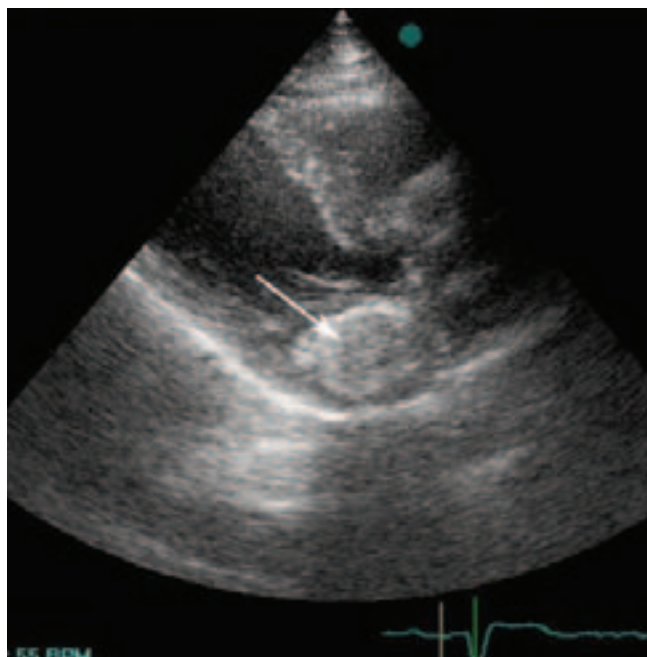


Figure 8. Lipoma; parasternal long-axis view showing a very large encapsulated mass in the left atrioventricular groove (arrow)

The most common sites affected are the left ventricle, right atrium, and interatrial septum.²⁴ They may occur at any age and have no sex predilection. Lipomas are slow growing and may attain considerable size (≥ 4 kg) before producing obstructive or arrhythmic symptoms.⁹⁷ Many are asymptomatic and are discovered incidentally on routine chest roentgenogram, echocardiogram, or at surgery or autopsy.^{98,99}

Subepicardial and intrapericardial lipomas tend to compress the heart, may be associated with pericardial effusion, and present as cardiac or mediastinal enlargement on chest radiograph. Subendocardial tumors may produce chamber obstruction. Lipomas lying within the myocardium or septum

can produce arrhythmias or conduction abnormalities.^{100,101} Large tumors that produce severe symptoms should be resected. These tumors are not known to recur.

Lipomatous hypertrophy of the interatrial septum

Although lipomas are true neoplasms, lipomatous hypertrophy is a non-encapsulated accumulation of mature adipose tissue within the atrial septum.² This abnormality, more common than cardiac lipomas, tends to be quite large (≥ 7 cm), favors the right atrium, and is a common finding in women who are elderly and obese as an incidental finding during a variety of cardiac imaging procedures.^{60,102}

Echocardiographers should recognize this lesion by its characteristic dumbbell shape, the result of sparing of the fossa ovalis (Figure 9) with the preponderance of fat typically in the superior portion of the septum. When the atrial septum is massively infiltrated by fat, the amount of adipose tissue in other parts of the heart is always increased, particularly the right ventricle epicardial surface. The main problem is differentiation from a cardiac neoplasm.¹⁰³

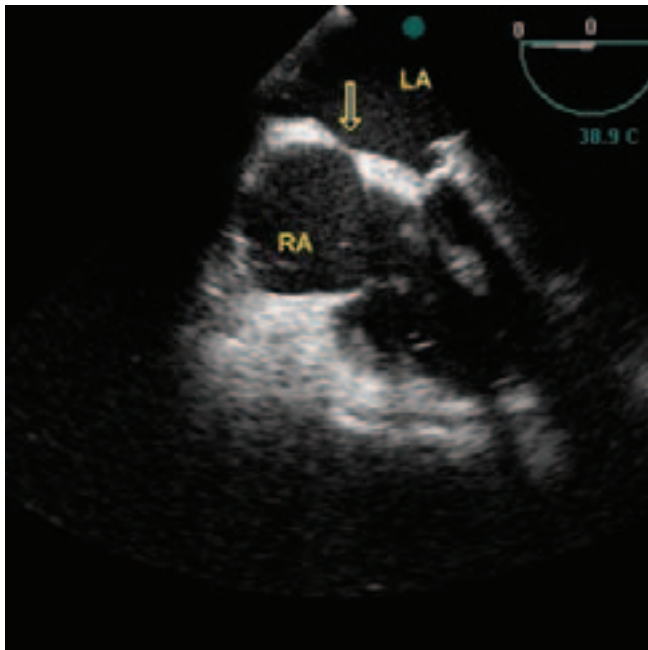


Figure 9. Lipomatous hypertrophy of interatrial septum; typical dumbbell shape, the result of sparing of the fossa ovalis (arrow)

Magnetic resonance imaging is reliable in the characterization of fat if diagnostic issues remain.^{104,105}

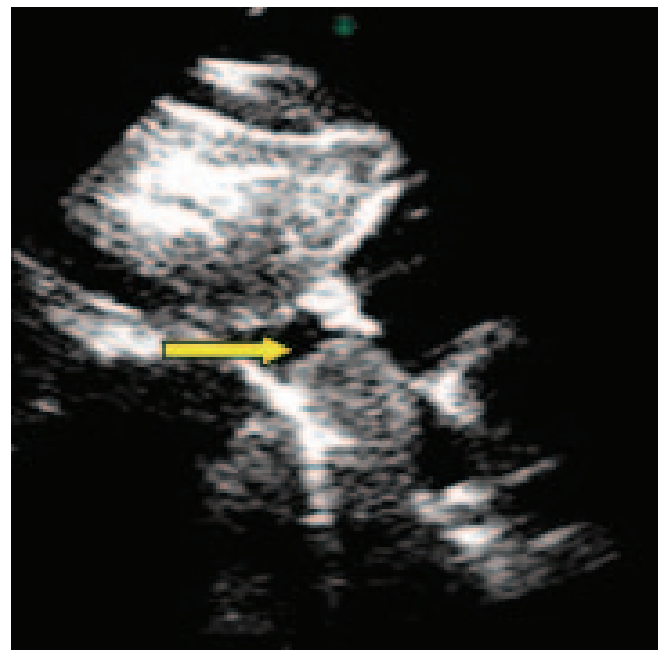
Various arrhythmias and conduction disturbances have been attributed to its presence, but a definite cause-and-effect relationship has not been established.¹⁰² Arrhythmias or heart block are considered by some as an indication for resection, but data are lacking as to the long-term benefits from resection.¹⁰⁶

Angiomas, teratomas, and mesotheliomas of the atrioventricular node and endocrine tumors are extremely rare, representing less than 7% of all cardiac tumors.²⁶ Angiomas are vascular tumors, and myocardial contrast echocardiography has been particularly useful in determining their vascular nature.¹⁰⁷⁻¹⁰⁹

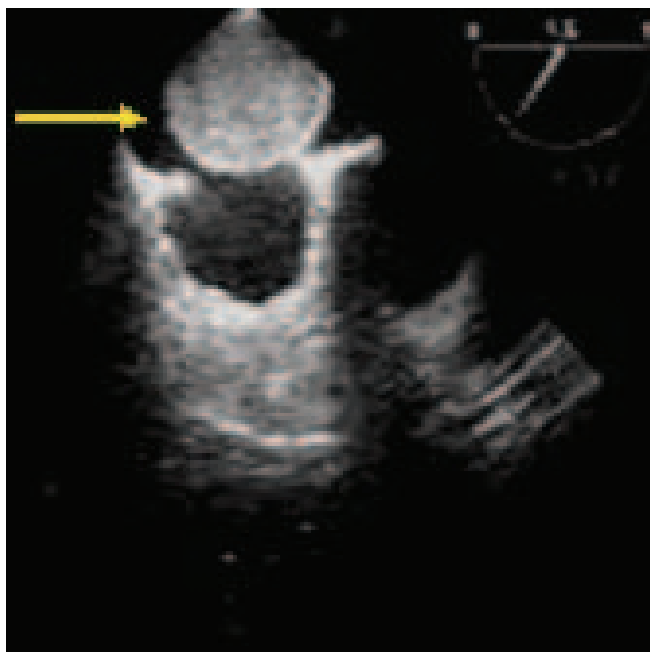
Hemangioma

Primary hemangiomas of the heart were first described in 1893. Mc Allister reviewed 533 primary tumors and cysts of the heart and pericardium, of which 15 (2.8%) were hemangiomas.¹¹⁰ They are rare benign primary cardiac tumors, with less than 100 cases described in the current cardiac literature.¹¹¹

The origin of hemangiomas is uncertain; they are thought to be either true neoplasms or hamartomas. These tumors can be localized in any part of the heart and pericardium. They are commonly found in the interventricular septum or the atrioventricular node, where they can cause complete heart block and sudden death. In a previous review of 56 cases of cardiac hemangiomas, 36% were found in the right ventricle, 34% in the left ventricle, 23% in the right atrium, and the rest on the interatrial septum (Figure 10) and in the left atrium.¹¹² Histological patterns that have been described include capillary hemangiomas, cavernous hemangiomas, hemangioendotheliomas, and intramuscular hemangiomas.¹¹³ Hemangiomas can present in any age group with a mild predominance in females. The symptomatology depends on the anatomic location and extension of the tumor. Although most cardiac hemangiomas are discovered incidentally, they may cause dyspnea, palpitation, atypical chest pain, arrhythmia, and pericardial effusion.¹¹⁴



A



B

Figure 10. Cavernous Hemangioma; transthoracic subcostal (A) and transesophageal bicaval (B) views demonstrating large homogenous mass in interatrial septum bulging into right atrium (arrows)

Echocardiography is usually the initial imaging modality and has an 81% accuracy rate in detecting cardiac tumors. Cardiac catheterization studies (particularly ventricular angiograms) can help to diagnose a cardiac tumor in 40% of cases by revealing an intracavitary filling defect. The classic finding on coronary arteriography is a vascular blush. Recently CT and MR have been used in preoperative diagnosis and in the evaluation of extra cardiac extension and myocardial involvement.¹¹⁵ Preoperative diagnosis of cardiac hemangiomas occurs in a minority of cases. The long-term prognosis is favorable after adequate surgical resection. Unresectable tumors have a poor prognosis and may lead to sudden death due to arrhythmias.

Teratoma

Cardiac teratomas are rare tumors that usually present in infants and young children but sometimes occur in adults.¹¹⁶ About 80% of the tumors are benign and the remainders have microscopic or clinically malignant cells.¹¹⁷

Teratomas are usually found in the mediastinum. Rarely intracardiac, they are usually within the pericardial space. Teratomas have elements of all 3 germ cell layers, and can have skin, hair, and muscle. Large bloody pericardial effusions causing hemodynamic compromise are a well-described presentation of these uncommon tumors.^{118,119} Fetal echocardiography has been useful in identifying mediastinal

masses causing cardiac compression, with associated accumulations of pericardial fluid.

Mesothelioma of the atrioventricular node

Mesotheliomas of the atrioventricular node, also termed polycystic tumors, Purkinje tumors, or conduction tumors, are mentioned in the pathologic classification of tumors. They are relatively small, multicystic tumors that arise in proximity to the atrial ventricular node and may extend upward into the bundle of His.²

Mesotheliomas are associated with heart block, ventricular fibrillation,¹²⁰ and sudden death. Cardiac pacing alone does not prevent subsequent ventricular fibrillation. Surgical excision has been reported.¹²¹

Pheochromocytoma

Cardiac pheochromocytomas arise from the chromaffin cells of the sympathetic nervous system and produce excess amounts of catecholamines, particularly norepinephrine. Approximately 90% of pheochromocytomas are in the adrenal glands. Fewer than 2% arise in the chest. These tumors predominantly affect young and middle-aged adults with an equal distribution between the sexes. Approximately 60% occur in the roof of the left atrium. The remainder involve the interatrial septum or anterior surface of the heart. The patients usually present with symptoms of uncontrolled hypertension. These tumors are usually located by scintigraphy and CT or MRI.^{122,123} Cardiac catheterization with differential blood chamber sampling is sometimes necessary.¹²⁴ Because these tumors are vascular and may be near major coronary arteries, coronary arteries angiography is advised. After the tumor is located, it should be removed. Transplantation has been performed for unresectable tumors. Complete excision produces cure.¹²²⁻¹²⁴

Primary malignant tumors

Approximately, 25% of primary cardiac tumors are malignant; and of these, about 75% are sarcomas. McAllister's survey of cardiac tumors found the most common to be angiosarcomas (31%), rhabdomyosarcomas (21%), malignant mesotheliomas (15%), and fibrosarcomas (11%).² Primary malignant cardiac tumors are sporadic, showing no inherited linkage.

Sarcomas most commonly occur in patients between the ages of 30 and 50 years, are unusual in children, are typically found in the right heart chambers, and occur equally in men and women.²⁴ There are several reports of sarcomas developing around surgically implanted Dacron grafts or

prosthetic valves, both in the heart and in other peripheral vascular sites.¹²⁵⁻¹²⁸ Cardiac sarcomas are characteristically very aggressive tumors and, once diagnosed, are associated with a downhill course. They grow rapidly, and death is usually the result of widespread infiltration of the myocardium or extensive distant metastasis. Sarcomas may cause right heart failure as a result of obstruction anywhere in the right heart inflow/outflow tract; penetration into the pericardial space and subsequent pericardial effusion may occur. Dysrhythmia is common. Cardiac findings are determined by the location of the tumor. Chest X-ray may be abnormal and even show a mass lesion, but the definite diagnosis is usually made via echocardiography.^{129,130} The echocardiographic characteristics of sarcomas are not specific, but sarcomas may attach at any site in the chamber, and many are sessile. A heterogeneous mass lesion in the right heart associated with dysrhythmia or conduction disturbance should include sarcoma in the differential. Right atrial lesions are more frequently malignant (usually angiosarcomas) than left-sided lesions (usually myxomas, but when malignant are often malignant fibrous histiocytomas). If malignancy is suspected, chest CT or MRI may suggest histology and provide detailed anatomy and help in staging and assessing resectability. Unfortunately, primary cardiac malignancy may grow to a large size prior to detection and involve portions of the heart not amenable to resection. Palliative medical therapy can be attempted with radiation therapy. Whether the tumor is primary or secondary, the decision to resect is based on the tumor size and location and an absence of metastatic spread.

Angiosarcoma

Angiosarcomas are two to three times more common in men than women and have a predilection for the right heart. Eighty percent arise in the right atrium.¹³¹⁻¹³³ These tumors tend to be bulky and aggressively invade adjacent structures, including the great veins, tricuspid valve, right ventricular free wall, interventricular septum, and right coronary artery.¹³² Obstruction and right heart failure are not uncommon. Unfortunately, most of these tumors have spread by the time of presentation, usually to the lung, liver, and brain.¹³¹ Without resection, 90% of the patients are dead within 9 to 12 months after diagnosis despite radiation or chemotherapy.^{42,134}

Malignant fibrous histiocytoma

Malignant fibrous histiocytomas are the most common soft-tissue sarcomas in adults. They are characterized histologically by a mixture of spindle cells, polygonal cells resembling histiocytes, and malignant giant cells. The cell of

origin is the fibroblast or histioblast.¹²⁹⁻¹³⁵ They usually occur in the left atrium and often mimic myxomas. Their tendency to metastasize is not as prominent as that of angiosarcomas. Several reports exist with rapid symptomatic recurrence after incomplete resection despite chemotherapy.

Rhabdomyosarcoma

Rhabdomyosarcomas do not evolve from rhabdomyoma and occur equally in the sexes. The tumors are multicentric in 60% of patients and arise from either ventricle. These tumors frequently invade cardiac valves or interfere with valve function because of their intracavitary bulk. These tumors are aggressive and may invade the pericardium. Surgical excision of small tumors may be rational but local and distant metastasis and poor response to radiation or chemotherapy limit survival to less than 12 months in the majority of these patients.^{94,116,117,130,136,137}

Lymphomas

Lymphomas may, albeit rarely, arise from the heart.¹³⁸ Most of these tumors respond to radiation and chemotherapy. Even when complete resection is not possible and incomplete resection is performed to relieve acute obstructive systems, radiation and chemotherapy have allowed for up to 3-year survival in selected patients.

Metastatic tumors

Whereas primary tumors of the heart are rare, cardiac metastases have been described in up to 20% of patients with malignancies of other organ systems.^{2,5,9,139} Secondary neoplasms are 20 to 40 times more common than primary cardiac malignancies.^{4,26,140} No malignant tumor preferentially metastasizes to the heart, with the possible exception of malignant melanomas, which involve the heart in up to 50% of patients.¹⁴¹ Cardiac lesions develop in up to 50% of patients with leukemia.⁵ Other cancers that commonly involve the heart include breast, lung, lymphoma, melanoma, and various sarcomas.^{2,142,143} Metastasis involves the pericardium, epicardium, myocardium, and endocardium.^{2,9} Cardiac metastases are encountered typically in patients with widespread systemic tumor dissemination; even in this setting, the heart may still be spared tumor deposition because of vigorous cardiac contractility and rapid coronary blood flow. The tumors that most commonly manifest cardiac metastasis are lung, breast, ovarian, kidney, leukemia, lymphoma, esophageal, and, as noted, melanoma.^{24,26}

Although solid intracardiac metastasis from melanomas is well described, the most common cardiac extension of



melanomas is subclinical and manifests as “charcoal” heart, with tumor studding the pericardial surface.¹⁴⁴

Metastasis can reach the heart through hematogenous spread via coronary arteries, lymphatic channels, direct extension from adjacent lung, breast, esophageal and thymic tumors, and from the sub-diaphragmatic vena cava.²⁴

Pericardial metastasis occurs more often than myocardial invasion by direct extension of thoracic cancer. The most common symptom is pericardial effusion with and without cardiac tamponade. The effusion may contain solid material adherent to the visceral or parietal pericardium; these masses may be tumors or may be clotted blood. Unfortunately, routine cytological examinations of the fluid are associated with a false-negative rate of perhaps as high as 20%.¹⁴⁵ Recurrent effusions are common, and pericardial window may be necessary. Solid pericardial metastasis that extends into cardiac chambers can be very aggressive, with the tumor expanding rapidly and causing significant hemodynamic derangement, including obstruction to cavity emptying and filling. Chemotherapy and tumor resection or debulking may alleviate symptoms and prolong survival. Occasionally, patients develop refractory arrhythmias or congestive heart failure.²⁴ Echocardiography is particularly useful for the diagnosis of pericardial effusion, irregular pericardial thickening, or intracavitary masses interfering with the blood flow.

Right atrial extension of sub-diaphragmatic tumors

Both benign and malignant abdominal and pelvic tumors can extend to the heart through the inferior vena cava. Wilms' tumors (common in children), uterine leiomyosarcomas, and hepatomas may also metastasize to the heart by the inferior vena cava. Of all the tumors that metastasize to the heart via the inferior vena cava, renal cell carcinomas (hypernephroma) are the most common. Up to 10% of renal cell carcinomas invade the inferior vena cava, and up to 43% of patients with this tumor demonstrate right atrium involvement.^{146,147}

Their point of origin and extension into the inferior vena cava usually can distinguish these metastases from the typical myxomas, and this attachment is best imaged in the subcostal plane. Radiation and chemotherapy are not effective in relieving the obstruction of the blood flow. If the kidney can be fully removed as well as the tail of the tumor thrombus, survival can approach 75% at 5 years.^{92,148,149}

Intravascular leiomyomatosis

The most commonly reported benign tumor with inferior vena cava intracardiac extension is intravascular leiomyomatosis of pelvic or uterine origin (Figure 11).

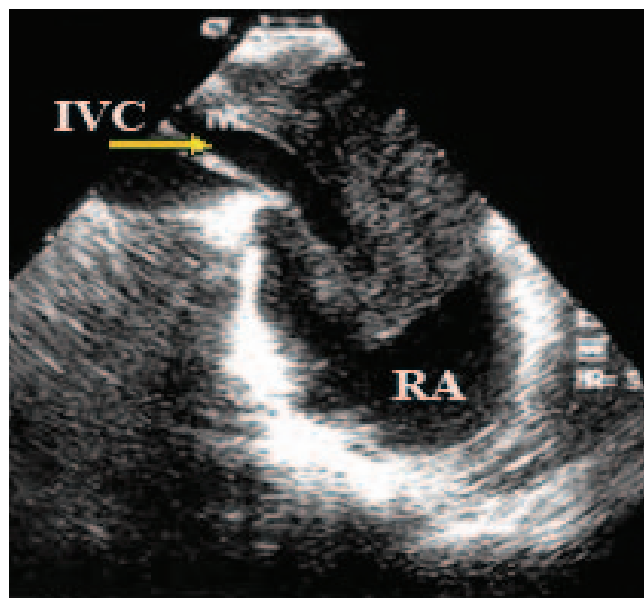


Figure 11. Intracardiac leiomyomatosis; transesophageal view of intracardiac leiomyomatosis invading right atrium (RA) by dilated inferior vena cava (IVC). Tumor is heterogeneous in appearance and abuts superior border of IVC (arrow).

Leiomyomatosis, a rare uterine tumor, is defined as the extension into the venous channels of a histologically benign smooth muscle tumor. As cardiac involvement is present in up to 10% of cases, it may be misdiagnosed as a primary cardiac tumor or venous thrombus-in-transit.¹⁵⁰ It was first reported by Birch-Hirschfeld in 1897,¹⁵¹ and the first case report in the English literature was published by Marshall and Morris in 1959.¹⁵² It generally occurs in women aged between 28 and 80 years old, most patients being middle-aged women.¹⁵³ The patients often have a history of hysterectomy, or may have symptoms due to uterine fibroids. Cardiac involvement presents typically with right-sided congestive symptoms. There are, however, other presentations like syncope due to obstruction at the tricuspid valve. Rarer manifestations that have been reported include a high output state, secondary thrombosis with Budd-Chiari syndrome, massive ascites, sudden death, and systemic embolism. Metastasis to lungs and lymph nodes has been reported, and pulmonary nodules have been described.

The most important condition in the differential diagnosis is thrombus-in-transit, which appears as elongated mobile masses of venous casts and gives a “popcorn” appearance within the cardiac chambers.¹⁵⁰

Other tumors such as renal cell carcinoma and hepatomas may extend into the right-sided cardiac chambers via the inferior vena cava. Tumor removal may necessitate sternotomy as well as laparotomy.¹⁵¹ If the tumor is extensive, a two-stage operation may be needed.¹⁵² Recurrence after the surgical removal of the cardiac tumor is not unusual and can occur up to 15 years after surgery. Echocardiography may be useful for detecting cardiac recurrence and monitoring tumor growth.

Carcinoid syndrome

The carcinoid syndrome (flushing, gastrointestinal hypermotility with secretory diarrhea, bronchospasm associated with wheezing, and carcinoid heart disease) results from circulating humoral substances secreted by the carcinoid tumor.¹⁵⁴ Patients with primary carcinoid tumors of the ileum who have liver metastasis develop the distinctive lesions of the heart. These lesions are always located on the right and occasionally on the left side of the heart. When the primary carcinoid tumor is of a pulmonary bronchus, the carcinoid valvular lesions may be limited to the left-sided valves. In this setting, the liver may be tumor free.¹⁵⁵ Carcinoid valve lesions are characterized by plaque-like, fibrous endocardial thickening that causes retraction and fixation of the tricuspid and pulmonary valve leaflets.

Tricuspid regurgitation is a nearly universal finding; tricuspid stenosis, pulmonary regurgitation, and pulmonary stenosis may also occur.¹⁵⁴ The lesion occurs nearly entirely on the downstream (ventricular) side of the septal and posterior tricuspid leaflets. On the anterior tricuspid leaflet, the deposits can occur on both sides, which results in the adherence of the leaflet to the underlying mural endocardium and in significant valvular incompetence and occasionally some degree of stenosis.¹⁵⁴ The dominant pulmonic valve lesion tends to be stenosis. Carcinoid is the only condition in which both right-sided valves are uniformly involved, and the lesions are pulmonary stenosis and tricuspid regurgitation. The typical valve morphology is of rigid leaflets fixed in a semi-open position.

Surgical replacement of dysfunctional valves is described, but the mortality appears to be fairly high.^{156,157}

Cardiac cysts

Although cardiac cysts are not true neoplasms, they are occasionally found within the heart and pericardium. The most common cysts are pericardial cysts, echinococcal (hydatid) cysts, and blood cysts.

Echinococcosis

Hydatid disease is a parasitic infestation caused by the larvae of the tape form echinococcus. Cardiac involvement is rare, with a reported occurrence between 0.2- 2% of all hydatid diseases.¹⁵⁸⁻¹⁶¹ Primary involvement of the heart usually occurs in 50% of cases via the coronary arteries. Secondary involvement of the heart occurs from the hydatid disease of the adjacent organs, such as lungs or from the dome of the liver. The left ventricle is affected most often

(50-70%), followed by right ventricle pericardium (15-20%), and interventricular septum (5-15%).^{159,161,162}

Symptoms, signs, and potential complications depend on the location and the size of the cysts.¹⁵⁸ Rupture, dysrhythmia, heart failure, and emboli are common and can result in death.^{158,159,163} Echocardiography, CT, and MRI might be used for the diagnosis. Transesophageal echocardiography shows the cystic nature of the mass, but sometimes the echolucent and multi-septated nature of lesions may be absent. Echocardiography cannot be used to differentiate hydatid cysts from congenital pericardial lesions. Computed tomography and MRI are superior to surrounding tissues. Calcifications are best seen on CT.^{158,163,164}

The differential diagnosis of cardiac hydatid disease, other cystic masses, and tumor-like lesions of the heart such as myocardial aneurysms, pericardial cysts, and pleuropericardial masses should always be considered. Operation is the treatment of choice.¹⁶⁵⁻¹⁶⁹

Pericardial cysts

Pericardial cysts are rounded echolucent structures typically adjacent to the right atrium. The diagnosis can be made on chest radiograph. Pericardial cysts are usually asymptomatic, but can become quite large and cause compression of the right atrium and right ventricle and the surrounding mediastinal structures, including the bronchus and esophagus. Operation is indicated when significant symptoms dominate the clinical picture.¹⁷⁰⁻¹⁷³

Blood cysts

Blood cysts are congenital cysts typically found on the closure lines of the valvular endocardium. They appear as well-circumscribed masses with thin walls and an echolucent core. They are rare in adults, and only a few reports of prospective echocardiographic diagnosis are available. Careful echocardiographic monitoring of the cysts for changes in size and for the assessment of changes in cardiac function may be appropriate, and operation may be indicated when the cysts are noted to cause cardiac dysfunction.¹⁷⁴⁻¹⁷⁷

Conclusion

Echocardiography is the procedure of choice for the evaluation of intracardiac masses. Echocardiography should, therefore, be meticulously applied and data cautiously interpreted. The appropriate knowledge of and careful attention to cardiac anatomy, use of multiple scan planes, and application of clinical information are mandatory for the diagnosis.



References

1. Smith C. Tumors of the heart. *Arch Pathol Lab Med* 1986;110:371-374.
2. McAllister HA, Fenoglio JJ Jr. Tumors of the cardiovascular system. In: Rubinstein L, ed. *Atlas of Tumor Pathology*, fascicle 15. 2nd ed. Washington DC: Armed Forces Institute of Pathology; 1978. p. 5-71.
3. Straus R, Merliss R. Primary tumors of the heart. *Arch Pathol* 1945;39:74-78.
4. Reynen K. Cardiac myxomas. *N Engl J Med* 1995;333:1610-1617.
5. Fine G. Neoplasms of the pericardium and heart. In: Gould SE, ed. *Pathology of the Heart and Blood Vessels*. New York: Springfield; 1968. p. 851-876.
6. Nadas AD, Ellison RC. Cardiac tumors in infancy. *Am J Cardiol* 1968;21:363-366.
7. Pollia JA, Gogol LJ. Some notes on malignancies of the heart. *Am J Cancer* 1936;27:329-333.
8. Wold LE, Lie JT. Cardiac myxomas: a clinicopathologic profile. *Am J Pathol* 1980;101:219-240.
9. Silverman NA. Primary cardiac tumors. *Ann Surg* 1980;191:127-138.
10. Agmon Y, Connolly H, Olson L, Khanderia B, Seward J. Noncompaction of the ventricular myocardium. *J Am Soc Echocardiogr* 1999;12:859-863.
11. Lowery MH, Martel JA, Zambrano JP, Ferreira A, Eco L, Gallagher A. Noncompaction of the ventricular myocardium: the use of contrast-enhanced echocardiography in the diagnosis. *J Am Soc Echocardiogr* 2003;16:94-96.
12. Stollberger C, Finsterer J. Left ventricular hypertrabeculation/noncompaction. *J Am Soc Echocardiogr* 2004;17:91-100.
13. Ward RP, Weinert L, Spencer KT, Furlong KT, Bednarz J, DeCara J, Lang RM. Quantitative diagnosis of apical cardiomyopathy using contrast echocardiography. *J Am Soc Echocardiogr* 2002;15:316-322.
14. Minich LL, Hawkins JA, Tani LY, Judd VE, McGough EC. Inverted left atrial appendage presenting as an unusual left atrial mass. *J Am Soc Echocardiogr* 1995;8:328-330.
15. Toma DM, Stewart RB, Miyake-Hull CY, Otto CM. Inverted left atrial appendage mimicking a left atrial mass during mitral valve repair. *J Am Soc Echocardiogr* 1995;8:557-559.
16. Pharr J, West M, Kusomoto F, Figueredo V. Prominent crista terminalis appearing as a right atrial mass on transthoracic echocardiogram. *J Am Soc Echocardiogr* 2002;15:753-755.
17. Goldschlager A, Goldschlager N, Brewster H. Catheter entrapment in a Chiari network involving an atrial septal defect. *Chest* 1972;62:345-346.
18. Cooke J, Gelman J, Harper R. Chiari network entanglement and herniation into the left atrium by an atrial septal defect occluder device. *J Am Soc Echocardiogr* 1999;12:601-603.
19. Shimoike E, Ueda N, Maruyama T, Kaji Y, Niho Y. Entrapment of a guide wire by the Chiari network in a patient with ablated idiopathic ventricular tachycardia. *J Interv Card Electrophysiol* 2001;5:219-222.
20. Heggveit HA. Thrombosed varices of the heart. *Am J Pathol* 1966;48:50-55.
21. Harrity P, Tazelaar H, Edwards W, Orszulak T, Freeman W. Intracardiac varices of the right atrium: a case report and review of the literature. *Int J Cardiol* 1995;48:177-181.
22. Ensberding R, Erbel DR, Kaspar W. Diagnosis of heart tumors by transesophageal echocardiography. *Eur Heart J* 1993;14:1223-1228.
23. Moes RJ, O'Malley CD. Realdo Columbo: on those things rarely found in anatomy. *Bull Hist Med* 1960; 34:508-512.
24. Roberts WC. Primary and secondary neoplasms of the heart. *Am J Cardiol* 1997;80:671-682.
25. Lam KY, Dickens P, Chan ACL. Tumors of the heart: a 20-year experience with review of 12485 consecutive autopsies. *Arch Pathol Med* 1993;117:1027-1031.
26. Burke A, Virmani R. *Atlas of tumor pathology*. In: Rubinstein L, ed. *Atlas of Tumor Pathology*, fascicle 16. 3rd ed. Washington DC: Armed Forces Institute of Pathology; 1978. p. 1-98.
27. Tazelaar HD, Locke Pinede L, Duhaut P, Loire R. Clinical presentation of left atrial cardiac myxoma: a series of 112 consecutive cases. *Medicine* 2001;80:159-172.
28. Carney JA. Differences between nonfamilial and familial cardiac myxoma. *Am J Surg Pathol* 1985;64:270-283.
29. Bortolotti U, Faggian G, Mazzucco A, Milano A, Thiene G, Fasoli G, Gallucci V. Right atrial myxoma originating from the inferior vena cava. *Ann Thorac Surg* 1990;49:1000-1002.
30. Kuroda H, Nitta K, Ashida Y, Hara Y, Ishiguro S, Mori T. Right atrial myxoma originating from the tricuspid valve. *J Thorac Cardiovasc Surg* 1995;109:1249-1250.
31. McCarthy PM, Schaff HV, Winkler HZ, Lieber MM, Carney JA. Deoxyribonucleic acid ploidy pattern of cardiac myxomas. *J Thorac Cardiovasc Surg* 1989;98:1083-1086.
32. King YL, Dickens P, Chan ACL. Tumors of the heart. *Arch Pathol Lab Med* 1993;117:1027-1039.
33. Gelder HM, O'Brian DJ, Staples ED, Alexander JA. Familial cardiac myxoma. *Ann Thorac Surg* 1992;53:419-424.
34. Kennedy P, Parry AJ, Parums D, Pillai R. Myxoma of the aortic valve. *Ann Thorac Surg* 1995;59:1221-1223.
35. St. John Sutton MG, Mercier LA, Guiliana ER, Lie JT. Atrial myxomas: a review of clinical experience in 40 patients. *Mayo Clin Proc* 1980;55:371-376.
36. Burke AP, Virmani R. Cardiac myxoma: a clinicopathologic study. *Am J Clin Pathol* 1993;100:671-680.
37. Peters MN, Hall RJ, Cooley DA. The clinical syndrome of atrial myxoma. *JAMA* 1974;230:695-701.
38. Carney JA, Hruska LS, Beauchamp GD. Dominant inheritance of the complex of myxomas, spotty pigmentation, and endocrine overactivity. *Mayo Clin Proc* 1986;61:165-172.
39. Farrah MG. Familial cardiac myxoma: study of patients with myxoma. *Chest* 1994;105:65-68.
40. Carney JA, Gordon H, Carpenter PC, Shenoy BV, Go VL. The complex of myxomas, spotty pigmentation, and endocrine overactivity. *Medicine* 1985;64:270-283.
41. Mahilmaran A, Seshadri M, Nayar PG, Sudarsana G, Abraham KA. Familial cardiac myxoma; Carney's complex. *Tex Heart Inst J* 2003;30:80-82.
42. Waller R, Grider L, Rohr T. Intracardiac thrombi: frequency, location, etiology and, complications: a morphologic review, part I. *Clin Cardiol* 1995;18:477-479.
43. Imperio J, Summels D, Krasnow N, Piccone VA Jr. The distribution patterns of biatrial myxoma. *Ann Thorac Surg* 1980;29:469-473.
44. Jones DR, Hill RC, Abbott AE Jr, Gustafson RA, Murray GF. Unusual location of an atrial myxoma complicated by a secundum atrial septal defect. *Ann Thorac Surg* 1993;55:1252-1252.
45. Kuroki S, Naitoh K, Katoh O. Increased interleukin-6 activity in cardiac myxoma with mediastinal lymphadenopathy. *Intern Med* 1992;31:1207-1209.

46. Reddy DJ, Rao TS, Venkaiah KR. Congenital myxoma of the heart. *Indian J Pediatr* 1956;23:210-212.
47. Prichard RW. Tumors of the heart: review of the subject and report of one hundred and fifty cases. *Arch Pathol* 1951;51:98-128.
48. Prichard RW. Tumors of the heart: review of the subject and report of one hundred and fifty cases. *Arch Pathol* 1951;51:98-128.
49. Malekzadeh S, Roberts WC. Growth rate of left atrial myxoma. *Am J Cardiol* 1989;64:1075-1076.
50. Goodwin JF. The spectrum of cardiac tumors. *Am J Cardiol* 1968;21:307-314.
51. Greenwood WF. Profile of atrial myxoma. *Am J Cardiol* 1968;21:367-375.
52. Bulkley BH, Hutchins GM. Atrial myxomas: a fifty year review. *Am Heart J* 1979;97:639-643.
53. Munding A, Gruber HP, Dinkel E. Imaging cardiac mass lesions. *Radiol Med* 1992;10:135-140.
54. Reeder GS, Khandheria BK, Senard JB. Transesophageal echocardiographs and cardiac masses. *Mayo Clin Proc* 1991;66:1101-1109.
55. Ensberding R, Erbel DR, Kaspar W. Diagnosis of heart tumors by transesophageal echocardiography. *Eur Heart J* 1993;14:1223-1228.
56. Samdarshi TE, Mahan EF 3rd, Nanda NC, Guthrie FW, Bernstein IJ Jr, Kirklin JW. Transesophageal echocardiographic diagnosis of multicentric left ventricular myxomas mimicking a left atrial tumor. *J Thorac Cardiovasc Surg* 1992;103:471-474.
57. McCarthy PM, Piehler JM, Schaff HV, Pluth JR, Orszulak TA, Vidaillet HJ Jr, Carney JA. The significance of multiple, recurrent, and "complex" cardiac myxoma. *J Thorac Cardiovasc Surg* 1986;91:389-396.
58. Dato GMA, Benedictus M, Dato AA. Long-term follow-up of cardiac myxomas (7-31 years). *J Cardiovasc Surg* 1993;34:141-146.
59. Zingas AP, Carrera JD, Murray CA. Lipoma of the myocardium. *J Comput Assist Tomogr* 1983;7:1098-1100.
60. Reyes CV, Jablowski VR. Lipomatous hypertrophy of the atrial septum: a report of 38 cases and review of the literature. *Am J Clin Pathol* 1979;72:785-788.
61. Markel ML, Armstrong WF, Waller BF. Left atrial myxoma with multicentric recurrence and evidence of metastases. *Am Heart J* 1986;111:409-413.
62. Hade Y, Takahashi T, Takenaka K. Recurrent multiple myxomas. *Am Heart J* 1984;107:1280-1282.
63. Edwards FH, Hale D, Cohen A, Thompson L, Pezzella AT, Virmani R. Primary cardiac valve tumors. *Ann Thoracic Surg* 1991;52:1127-1131.
64. Israel DH, Sherman W, Ambrose JA. Dynamic coronary ostial occlusion due to papillary fibroelastoma leading to myocardial ischemia and infarction. *Am J Cardiol* 1991;67:104-105.
65. Darvishian F, Farmer P. Papillary fibroelastoma of the heart: report of two cases and review of the literature. *Ann Clin Lab Sci* 2001;31:291-296.
66. Shing M, Rubenson DS. Embolic stroke and cardiac papillary fibroelastoma. *Clin Cardiol* 2001;24:346-347.
67. Klarich KW, Enriquez Sarano M, Gura GM, Edwards WD, Tajik AJ, Seward JB. Papillary fibroelastoma: echocardiographic characteristics for diagnosis and pathologic correlation. *Am Coll Cardiol* 1997;30:784-790.
68. Mugge A, Daniel WG, Haverich A. Diagnosis of non-infective cardiac mass lesions by two-dimensional echocardiography. Comparison of the transthoracic and transesophageal approaches. *Circ* 1991;83:70-78.
69. Winkler M, Higgins CB. Suspected intracardiac masses: Evaluation with MR imaging. *Radiol* 1987;165:117-122.
70. Trga L, Manfredi J. Papillary fibroelastoma of the septal leaflet of the tricuspid valve. Report of a case and review of literature. *Ital Heart J* 2003;S4:862-865.
71. Eslami-Varzaneh F, Brun A. An unusual case of multiple papillary fibroelastoma, review of literature. *Cardiovasc Pathol* 2003;12:170-173.
72. Mc Alister HA, Fenoglio JJ. Tumors of the cardiovascular system. Tumors of the cardiovascular system. In: Rubinstein L, ed. *Atlas of Tumor Pathology, fascicle 15*. 2nd ed. Washington DC: Armed Forces Institute of Pathology; 1978. p. 20-25.
73. Roberts WC. Papillary Fibroelastoma of the heart. *Am J Cardiol* 1997;80:973-975.
74. Sun JP, Ashe CR, Yang XS, Cheng GG, Scalia GM, Massed AG, Griffin BP, Ratliff NB, Stewart WJ, Thomas JD. Clinical and echocardiographic characteristics of papillary fibroelastoma: a retrospective and prospective study in 162 patients. *Circ* 2001;103:2687-2693.
75. Lichtenstein HL, Lee JC, Stewart S. Papillary tumor of the heart: incidental finding at surgery. *Hum pathol* 1979;10:473-475.
76. Hicks KA, Kovach JA, Frishberg DP, Wiley TM, Gurezak PB, Vernalis MN. Echocardiographic evaluation of papillary fibroelastoma: a case report and review of the literature. *Am J Soc Echocardiogr* 1996;9:353-360.
77. Almagro UA, Perry LS, Choi H, Pinator K. Papillary fibroelastoma of the heart. Report of six cases. *Arch Pathol Lab Med* 1982;106:318-321.
78. Grandmougin D, Fayaf G, Monkussa D, Decoene C, Abolmaali K, Bodart JC, Limousin M, Warembong H. Cardiac valve papillary fibroelastoma: clinical, histological and immunohistochemical studies and a physiopathogenic hypothesis. *J Heart Valve Dis* 2000;9:832-841.
79. Joffe II, Jacobs LE, Owen AN, Ioli A, Kotler MN. Rapid development of a papillary fibroelastoma with associated thrombosis: The role of transthoracic and transesophageal echocardiography. *Echocardiography* 1997;14:287-291.
80. Koji T, Fujioka M, Imai H, Komada T, Takeuchi M, Ichikawa T, Tameda Y, Sato F, Nakano T. Infected papillary fibroelastoma attached to the atrial septum. *Circ* 2002;66:305-307.
81. Al Mohammad A, Pambakian H, Young C. Fibroelastoma: case report and review of the literature. *Heart* 1998;79:301-304.
82. Nicks R. Hamartoma of the right ventricle. *J Thorac Cardiovasc Surg* 1967;47:762-766.
83. Bass JL, Brenningstall GN, Swaiman KF. Echocardiographic incidence of cardiac rhabdomyoma in tuberous sclerosis. *Am J Cardiol* 1985;55:1379-1382.
84. Chan HSL, Sonley MJ, Moes CAF, Daneman A, Smith CR, Martin DJ. Primary and secondary tumors of the heart, pericardium, and great vessels: a report of 75 cases and review of the literature. *Cancer* 1985;56:825-836.
85. Fenoglio JJ, McAllister HA, Ferrans VJ. Cardiac rhabdomyoma: a clinicopathologic and electron microscopic study. *Am J Cardiol* 1976;38:241-251.
86. Garson A, Smith RT, Moak JP. Incessant ventricular tachycardia in infants: myocardial hamartomas and surgical cure. *J Am Coll Cardiol* 1987;10:619-626.
87. Fesslova V, Villa L, Rizzuti T, Mastrangelo M, Mosca F. Natural history and long-term outcome of cardiac rhabdomyomas detected prenatally. *Prenat Diagn* 2004;24:241-248.



88. Verhaaren HA, Vanakker O, DeWolf D, Suys B, Francois K, Matthys D. Left ventricular outflow obstruction in Rhabdomyoma of infancy: meta-analysis of the literature. *J Pediatr* 2003;143:258-263.
89. Cina SJ, Smialek JE, Burke AP, Virmani R, Hutchins GM. Primary cardiac tumors causing sudden death: a review of the literature. *Am J Forensic Med Pathol* 1996;17:271-281.
90. Wong JA, Fishbein MC. Cardiac fibroma resulting in fatal ventricular arrhythmia. *Circulation* 2000;101:168-170.
91. Cho JM, Danielson G, Puga F, Dearani JA, McGregor CGA, Tazelaar HD. Surgical resection of ventricular cardiac fibromas: early and late results. *Ann Thorac Surg* 2003;76:1929-1934.
92. Reece IJ, Cooley DA, Frazier OH, Hallman GL, Powers PL, Montero CG. Cardiac tumors. Clinical spectrum and prognosis of lesions other than classic benign myxoma in 20 patients. *J Thorac Cardiovasc Surg* 1984;88:439-446.
93. Yamaguchi M, Hosokawa Y, Ohashi H, Imai M, Oshima Y, Minamiji K. Cardiac fibroma: long term fate after excision. *J Thorac Cardiovasc Surg* 1992;103:140-145.
94. Burke AP, Rosado-de-Christenson M, Templeton PA, Virmani R. Cardiac fibroma: clinicopathologic correlates and surgical treatment. *J Thorac Cardiovasc Surg* 1994;108:862-870.
95. Jamieson SA, Gaudiani VA, Reitz BA. Operative treatment of an unresectable tumor on the left ventricle. *J Thorac Cardiovasc Surg* 1981;81:797-799.
96. Valente M, Cocco P, Thiene G. Cardiac fibroma and heart transplantation. *J Thorac Cardiovasc Surg* 1993;106:1208-1212.
97. Lang-Lazdunski L, Oroudji M, Pansand Y, Vissuzaine C, Hvass U. Successful resection of giant intrapericardial lipoma. *Ann Thorac Surg* 1994;58:238-240.
98. Harjola PR, Ala-Kulju K, Ketonen P. Epicardial lipoma. *Scand J Thorac Cardiovasc Surg* 1985;19:181-183.
99. Arciniegas E, Hakimi M, Farooki ZQ. Primary cardiac tumors in children. *J Thorac Cardiovasc Surg* 1980;79:582-591.
100. Reyes LH, Rubio PA, Korompai FL. Lipoma of the heart. *Int Surg* 1976;61:179-180.
101. Voigt J, Agdal N. Lipomatous infiltration of the heart: an uncommon cause of sudden unexpected death in a young man. *Arch Pathol Lab Med* 1982;106:497-498.
102. Shirani J, Roberts WC. Clinical, electrocardiographic and morphologic features of massive fatty deposits ("lipomatous hypertrophy") in the atrial septum. *J Am Coll Cardiol* 1993;22:226-238.
103. Simons M, Cabin HS, Jaffe CC. Lipomatous hypertrophy of the atrial septum: diagnosis by combined echocardiography and computerized tomography. *Am J Cardiol* 1984;54:465-466.
104. Basu S, Folliguet T, Anselmo M. Lipomatous hypertrophy of the interatrial septum. *Cardiovasc Surg* 1994;2:229-231.
105. Zeebregts CJAM, Hensens AG, Timmermans J, Pruszczynski MS, Lacquet LK. Lipomatous hypertrophy of the interatrial septum: indication for surgery? *Eur J Cardiothorac Surg* 1997;11:785-787.
106. Vander Salm TJ. Unusual primary tumors of the heart. *Semin Thorac Cardiovasc Surg* 2000;2:89-100.
107. Bednarz JE, Spencer KT, Weinert L, Sugeng L, Mor-avi V, Lang RM. Identification of cardiac masses and abnormal blood flow patterns with harmonic power Doppler contrast echocardiography. *J Am Soc Echocardiogr* 1999;12:871-875.
108. Kirkpatrick JN, Wong T, Bednarz JE, Spencer KT, Sugeng L, Ward RP. Differential diagnosis of cardiac masses using contrast echocardiographic perfusion imaging. *J Am Coll Cardiol* 2004;43:1412-1419.
109. Lepper W, Shivalkar B, Rinkevich D, Belcik T, Wei K. Assessment of the vascularity of a left ventricular mass using myocardial contrast echocardiography. *J Am Soc Echocardiogr* 2002;15:1419-1422.
110. McAllister H. Tumors of the heart and pericardium. In: Silver MD, ed. *Cardiovascular pathology*. 1st ed. New York: Churchill Livingstone; 1978. p. 909-943.
111. Perk G, Yim J, Varkey M, Colvin SB, Tunick PA, Kronzon I. Cardiac Cavemous Hemangioma. *J Am Soc Echocardiogr* 2005;18:979.e3-4.
112. Esmaeilzadeh M, Jalalian R, Maleki M, Givtaj N, Mozaffari K, Parsaee M. Cardiac cavernous hemangioma. *Eur J Echocardiogr* 2007;8:487-489.
113. McAllister HA, Fenoglio JJ Jr. Tumors of the cardiovascular system. In: Rubinstein L, ed. *Atlas of Tumor Pathology, fascicle 15*. 2nd ed. Washington DC: Armed Forces Institute of Pathology; 1978. p. 46-52.
114. Stonfel E, Prime G, Kahn RJ. Cardiac tamponade with renal failure due to hemangioma of the heart. *Acta Cardiologica* 1979;34:345-349.
115. Oshima H, Hara M, Kono T, Shibamoto Y, Mishima A, Akita S. Cardiac hemangioma of the left atrial appendage: CT and MR findings. *J Thorac Imaging* 2003;18:204-206.
116. Thomas CR, Johnson GW, Stoddard MF. Primary malignant cardiac tumors: update 1992. *Med Pediatr Oncol* 1992;20:519-531.
117. Poole GV, Meredith JW, Breyer RH, Mills SA. Surgical implications in malignant cardiac disease. *Ann Thorac Surg* 1983;36:484-491.
118. Tollens M, Grab D, Lang D, Hess J, Oberhoffer R. Pericardial teratomas: prenatal diagnosis and course. *Fetal Diagn Ther* 2003;18:432-436.
119. Tollens T, Casselman F, Devlieger H, Gewillig MH, Vandenberghe K, Lerut TE, Daenen WJ. Fetal cardiac tamponade due to an intrapericardial teratomas. *Ann Thorac Surg* 1998;66:559-560.
120. Nishida K, Kaijima G, Nagayama T. Mesothelioma of the atrioventricular node. *Br Heart J* 1985;53:468-470.
121. Balasundaram S, Halees SA, Duran C. Mesothelioma of the atrioventricular node: first successful follow-up after excision. *Eur Heart J* 1992;13:718-719.
122. Sisson JC, Shapiro B, Beierwaltes WH. Locating pheochromocytomas by scintigraphy using 131-I-metaiodobenzylguanidine. *Cancer* 1984;34:86-92.
123. Orringer MB, Sisson JC, Glazer G, Shapiro B, Francis I, Behrendt DM, Thompson NW, Lloyd RV. Surgical treatment of cardiac pheochromocytomas. *J Thorac Cardiovasc Surg* 1985;89:753-757.
124. Jebara VA, Uva MS, Farge A. Cardiac pheochromocytomas. *Ann Thorac Surg* 1991;53:356-361.
125. Okada M, Takeuchi E, Mori Y, Ichihara S, Usui A, Ueda Y. An autopsy case of angiosarcoma arising around a woven Dacron prosthesis after a Cabrol operation. *J Thorac Cardiovasc Surg* 2004;127:1843-1845.
126. Ben-Izhak O, Vlodaysky E, Ofer A, Engel A, Nitecky S, Hoffman A. Epithelioid angiosarcoma associated with a Dacron vascular graft. *Am J Surg Pathol* 1999;23:1418-1423.
127. Durrleman NM, El-Hamamsy I, Demaria RG, Carrier M, Perrault LP, Albat B. Cardiac lymphoma following mitral valve replacement. *Ann Thorac Surg* 2005;79:1040-1042.
128. Fyfe BS, Quintana CS, Kaneko M. Aortic sarcoma four years after Dacron graft insertion. *Ann Thorac Surg* 1994;58:1752-1754.
129. Burke AP, Cowan D, Virmani R. Primary sarcomas of the heart. *Cancer* 1992;69:387-395.
130. Putnam JB, Sweeney MS, Colon R, Lanza LA, Frazier OH,

- Cooley DA. Primary cardiac sarcomas. *Ann Thorac Surg* 1991;51:901-906.
131. Bear PA, Moodie DS. Malignant primary cardiac tumors: the Cleveland Clinic experience. *Chest* 1987;92:860-870.
132. Rettmar K, Stierle U, Shiekhzadeh A. Primary angiosarcoma of the heart: report of a case and review of the literature. *Jpn Heart J* 1993;34:667-683.
133. Hermann MA, Shankerman RA, Edwards WD. Primary cardiac angiosarcoma: a clinicopathologic study of six cases. *J Thorac Cardiovasc Surg* 1992;102:652-656.
134. Wiske PS, Gillam LD, Blyden G. Intracardiac tumor regression documented by two-dimensional echocardiography. *Am J Cardiol* 1986;58:186-190.
135. Reardon MJ, DeFelice CA, Sheinbaum R, Baldwin JC. Cardiac autotransplant for surgical treatment of a malignant neoplasm. *Ann Thorac Surg* 1999;67:1793-1795.
136. Nagata K, Irie K, Morimatsu M. Rhabdomyosarcoma of the right ventricle. *Acta Pathol Jpn* 1982;32:839-843.
137. Miralles A, Bracamonte MD, Soncul H, del Castillo RD, Akhtar R, Bors V, Pavie A, Gandjbackhch I, Cabrol C. Cardiac tumors: clinical experience and surgical results in 74 patients. *Ann Thorac Surg* 1991;52:886-895.
138. Takagi M, Kugimiya T, Fuii T. Extensive surgery for primary malignant lymphoma of the heart. *J Cardiovasc Surg* 1992;33:570-572.
139. Pillai R, Blauth C, Peckham M, Hendry W, Barrett A, Goldstraw P. Intracardiac metastasis from malignant teratoma of the testis. *J Thorac Cardiovasc Surg* 1986;92:118-120.
140. Hallahan ED, Vogelzang NJ, Borow KM. Cardiac metastasis from soft-tissue sarcomas. *J Clin Oncol* 1986;4:1662-1669.
141. Mukai K, Shinkai T, Tominaga K, Shomoto Y. The incidence of secondary tumors of the heart and pericardium: a ten-year study. *Jpn N Clin Oncol* 1988;18:195-201.
142. Skhvatsabaja LV. Secondary malignant lesions of the heart and pericardium in neoplastic disease. *Oncology* 1986;43:103-106.
143. Press OW, Livingston R. Management of malignant pericardial effusion and tamponade. *JAMA* 1987;257:1088-1092.
144. Waller BV, Gottdeiner JS, Virmani R, Roberts WC. The "charcoal heart": melanoma to the cor. *Chest* 1980;77:671-676.
145. Warren WH. Malignancies involving the pericardium. *Semin Thorac Cardiovasc Surg* 2000;12:119-129.
146. Almasi GH. Surgery for tumors with cavoatrial extension. *Semin Thorac Cardiovasc Surg* 2000;12:111-118.
147. Prager RL, Dean R, Turner B. Surgical approach to intracardiac renal cell carcinoma. *Ann Thorac Surg* 1982;33:74-77.
148. Vaislic CD, Puel P, Grondin P, Vargas A, Thevenet A, Fontan F, Deville C, Leguerrier A, Touchot B, Piwnica A. Cancer of the kidney invading the vena cava and heart: results after 11 years of treatment. *J Thorac Cardiovasc Surg* 1986;91:604-609.
149. Shahian DM, Libertino JA, Zinman LN, Leonardi HK, Eyre RC. Resection of cavoatrial renal cell carcinoma employing total circulatory arrest. *Arch Surg* 1990;125:727-732.
150. Farfel Z, Shechter M, Vered Z. Review of echocardiographically diagnosed right heart entrapment of pulmonary emboli-in-transit with emphasis on management. *Am Heart J* 1987;113:171-178.
151. Timmis AD, Smallpeice C, Davies AC. Intracardiac spread of intravenous leiomyomatosis with successful surgical excision. *N Engl J Med* 1980;303:1043-1044.
152. Ricci MA, Cloutier LM, Mount S. Intravenous leiomyomatosis with intracardiac extension. *Cardiovasc Surg* 1995;3:693-696.
153. Esmailzadeh M, Tavakoli A, Safaei A. Recurrent intracardiac leiomyomatosis. *Can J Cardiol* 2007;23:1085-1086.
154. Roberts WC. A unique heart disease associated with a unique cancer: carcinoid heart disease. *Am J Cardiol* 1997;80:251-256.
155. Kulke M, Mayer RJ. Medical progress: carcinoid tumors. *N Eng J Med* 1999;340:858-868.
156. Connolly HM, Nishimura RA, Smith HC, Pellikka PA, Mullany CJ, Kvols LK. Outcome of cardiac surgery for carcinoid heart disease. *J Am Coll Cardiol* 1995;25:410-416.
157. Robiolio PA, Rigolin VH, Harrison JK, Lowe JE, Moore JO, Bashore TM. Predictors of outcome of tricuspid valve replacement in carcinoid heart disease. *Am J Cardiol* 1995;75:485-488.
158. Birincioglu CL, Bardakci H, Kucuker SA, Ulus AT. A clinical dilemma: cardiac and pericardial echinococcosis. *Ann Thorac Surg* 1999;68:1290-1294.
159. Bashour TT, Alali AP, Mason DT, Saalouke M. Echinococcosis of the heart: clinical and echocardiographic features in nineteen patients. *Am Heart J* 1996;132:1028-1030.
160. Kabbani SS, Jokhadar M, Sundouk A, Nabhani F. Surgical management of cardiac echinococcosis. Report of four cases. *J Cardiovasc Surg* 1992;44:505-510.
161. Rey M, Alfonso F, Torrecilla EG, McKenna WJ. Diagnostic value of two-dimensional echocardiography in cardiac hydatid disease. *Eur Heart J* 1991;12:1300-1307.
162. Esmailzadeh M, Zoroufian A, Bassiri HA, Raiisi K, Rezaei R. Cardiac Echinococcosis. *The Cardiology* 2006;2:39-41.
163. Siwach SB, Jagdish-Katyal VK. Cardiac echinococcosis, a rare echocardiographic diagnosis. *Heart* 1997;77:378-379.
164. Garcia-Dioz AI, Ros Mendoza LH, Villacampa VM. MRI evaluation of soft tissue hydatid disease. *Eur Radiol* 2000;10:462-463.
165. Ben-Hamda K, Maatouk F, Ben-Farhat M, Betbout F, Gamra H, Addad F. Eighteen year experience with Echinococcosis of the heart: clinical and echocardiographic features in 14 patients. *Int J Cardiol* 2003;91:145-151.
166. Atilgan D, Kudar H, Tukek T, Ozcan M, Yildirim O, Elmaci TT, Dursun Onursal E. Role of transesophageal echocardiography in diagnosis and management of cardiac hydatid cyst: report of three cases and review of the literature. *J Am Soc Echocardiogr* 2002;15:271-274.
167. Makaryus AN, Hametz C, Mieres J, Kort S, Carneglia J, Mangion J. Diagnosis of suspected cardiac echinococcosis with negative serologies: role of transthoracic, transesophageal, and contrast echocardiography. *Eur J Echocardiogr* 2004;5:223-227.
168. Hassine E, Kraoua S, Marniche K, Bousnina S, Lefi A, Kachboura S. A dead and calcified right ventricular hydatid cyst: the limits of imaging. *Presse Med* 2003;32:1802-1804.
169. Nisanoglu V, Erdil N, Isik B, Battaloglu B, Alat I. Acute abdominal aortic embolism caused by rupture of a cardiac hydatid cyst. *Ann Vasc Surg* 2004;18:484-486.
170. Patel J, Park C, Michaels J, Rosen S, Kort S. Pericardial cyst: case reports and a literature review. *Echocardiography* 2004;21:269-272.
171. Bava GL, Magliani L, Bertoli D, Gorrieri PF, Rimini A, Zaccagnini G. Complicated pericardial cyst: atypical anatomy and clinical course. *Clin Cardiol* 1998;21:862-864.
172. Bandeira FC, de Sa VPO, Moriguti JC, Rodrigues AJ, Jurca MC, Filho OC, Marin-Neto JA, Maciel BC. Cardiac tamponade: an unusual complication of pericardial cyst. *J Am Soc Echocardiogr* 1996;9:108-112.



173. Antonini-Canterin F, Piazza R, Ascione L, Pavan D, Nicolosi GL. Value of transesophageal echocardiography in the diagnosis of compressive, atypically located pericardial cysts. *J Am Soc Echocardiogr* 2002;15:192-194.
174. Pelikan HMP, Tsang TSM, Seward JB. Giant blood cyst of the mitral valve. *J Am Soc Echocardiogr* 1999;13:1005-1007.
175. Nkomo V, Miller FA. Eustachian valve cyst. *J Am Soc Echocardiogr* 2001;14:1224-1226.
176. Sim EKW, Wong ML, Tan KT, Sim SK. Blood cyst of the tricuspid valve. *Ann Thorac Surg* 1996;61:1012-1013.
177. Prasad A, Callahan MJ, Malouf JF. Acquired right atrial blood cyst: a hitherto unrecognized complication of cardiac operation. *J Am Soc Echocardiogr* 2003;16:377-378.