

# Thoracoabdominal Aortic Aneurysms

Ali Azizzadeh, MD\*, Anthony L. Estrera, MD, Charles C. Miller III, PhD, Hazim J. Safi, MD

*Memorial Hermann Hospital-Heart & Vascular Institute, The University of Texas at Houston Medical School, Houston, USA.*

## Abstract

Over the last 50 years, significant progress has been made in the surgical repair of thoracoabdominal aortic aneurysms (TAAA). Improvements in perioperative care and surgical techniques have resulted in reductions in complication and mortality rates. Adjunctive use of distal aortic perfusion and cerebrospinal fluid drainage has been especially helpful, reducing the incidence of neurological deficits to 2.4%. Current research is aimed at improving organ preservation. This review focuses on the current diagnosis and management of TAAA.

*J Teh Univ Heart Ctr 3 (2008) 131-140*

**Keywords:** Thoracoabdominal aortic aneurysm • Surgery • Review

## Epidemiology

In the United States, infrarenal abdominal aortic aneurysms (AAA) occur 3 to 7 times more frequently than thoracic aortic aneurysms. Fewer than 1000 thoracoabdominal aortic aneurysms (TAAA) are repaired annually, compared to approximately 50,000 infrarenal AAA. The prevalence of AAA varies between 2.3% to 10.7%, depending on the population studied and the size used to define an aneurysm.<sup>1-3</sup> The incidence of TAAA is estimated to be 10.4 cases per 100,000 person-years.<sup>4</sup> The mean age of patients with thoracic aortic aneurysm is between 59 and 69 years with a male to female predominance of between 2 and 4 to 1.<sup>5</sup>

Less than 40% of patients with untreated large TAAA survive beyond 5 years, with most deaths due to rupture.<sup>5-8</sup> TAAA studies have shown that rupture is more likely to occur when aneurysms exceed 5 cm, with risk of rupture increasing with aneurysm size.<sup>6,9-12</sup> The median size at which a TAAA will rupture is around 7.0 cm.<sup>13,14</sup> Aneurysms equal to or greater than 8 cm have an 80% risk of rupture within a year of diagnosis.<sup>15</sup> The lifetime probability of rupture for any untreated aortic aneurysm is 75% to 80%. It is difficult to predict at what size and when an aneurysm will rupture.

## Pathogenesis

An aortic aneurysm is defined as a localized or diffuse dilatation that exceeds 50% of normal aortic diameter. Most TAAAs are degenerative, with an underlying pathology similar to the more frequently encountered infrarenal abdominal aortic aneurysm. For a long time, arteriosclerosis has been implicated in the development of aortic aneurysm. However, arteriosclerosis primarily affects the intima and typically causes occlusive disease, whereas aneurysmal disease usually involves the media and adventitia. Although the pathogenesis of arteriosclerotic occlusive disease and that of aneurysm disease have been shown to be distinct, the two conditions commonly occur together. Histologically, degenerative aortic aneurysms are characterized by thinning of the media with destruction of smooth muscle cells and elastin, infiltration of inflammatory cells, and neovascularization.<sup>16-18</sup> A chronic inflammatory infiltrate, comprised of macrophages, as well as T and B lymphocytes, is consistently observed in the outer layer of aneurysm wall. The degree of vessel wall inflammation varies and the stimulus for cell migration remains unclear. These inflammatory cells, particularly macrophages, secrete proteases and elastases that can degrade the aortic wall; in

\*Corresponding Author: **Ali Azizzadeh**, Assistant Professor, Director of Endovascular Surgery, Department of Cardiothoracic and Vascular Surgery, The University of Texas at Houston Medical School, 6410 Fannin Street, Suite 450, Houston, TX 77030 USA. Tel: +1 713 500-5304. Fax: +1 713 500-0656. E-mail: ali.azizzadeh@uth.tmc.edu.

turn, the elastin degradation products may act as chemotactic agents for the influx of inflammatory cells.<sup>16</sup> The role of matrix metalloproteinases (MMP), the most prominent type of elastases, in the development of aortic aneurysms has emerged from both clinical and experimental studies. Increased amounts of elastases MMP-2, MMP-9 and MMP-12 have been found in aortic aneurysmal aortic tissue.<sup>16,19-21</sup>

Familial clustering of aortic aneurysm is evident, as up to 20% of patients with aneurysms have one or more first-degree relatives with the same affliction.<sup>22-24</sup> Marfan syndrome, characterized by skeletal, ocular, and cardiovascular abnormalities, is the most common inherited connective tissue disorder related to aortic aneurysm and dissection. Marfan syndrome occurs at a frequency of 1: 5000 worldwide. Aortic dilatation observed in Marfan patients has been linked to mutation in fibrillin-1 (FBN-1). Other known genetic syndromes that predispose individuals to thoracic aortic aneurysm and dissection include Ehlers-Danlos syndrome, Turner syndrome, and polycystic kidney disease.<sup>25-28</sup> In addition, a familial syndrome in which multiple members have thoracic aortic aneurysm and dissection, with yet to be identified genetic abnormalities, has been reported in the literature.<sup>24</sup> In the majority of these families, the phenotype for thoracic aortic aneurysm and dissection is inherited in an autosomal dominant manner with marked variability in the age at onset of aortic disease and decreased penetrance.<sup>24</sup>

Approximately 25% of TAAAs are associated with chronic aortic dissection. About 20% to 40% of patients will develop aneurysms in the thoracoabdominal aorta within 2 to 5 years following acute aortic dissection.<sup>10,29,30</sup> Persistent patency of the false aortic lumen is reported to be a significant predictor of aneurysmal formation.<sup>30,31</sup> However, the presence of chronic aortic dissection or patent false lumen has not been linked to a higher risk of aortic rupture.<sup>32</sup> In approximately 20% of cases, aneurysmal disease occurs in more than one part of the aorta. The so-called “mega” aorta is an “extensive” aortic aneurysm involving the ascending, transverse arch, and the entire thoracoabdominal aorta. The cause of extensive aortic aneurysm remains unknown, although associated factors include Marfan syndrome and chronic aortic dissection.

The options remain limited for patients afflicted with a large TAAA. Sudden fatal aneurysm rupture is a looming and unpredictable threat. Most patients succumb with rupture of the aneurysm. Although emergency repair of ruptured TAAA can save lives, the associated morbidity and mortality remain extremely high. Elective surgical repair of TAAA is the only effective treatment for eradicating the risk of aneurysm rupture and improving patient survival.

### ***Clinical manifestations***

As they increase in size, aortic aneurysms can cause compressive symptoms although most do not until they reach

a large size. Symptoms include:

1. Ill-defined chronic back pain, although pain can also occur in the chest, flank or epigastrium. Acute changes in the characteristics and severity of pain can indicate sudden expansion or impending aortic rupture.
2. Hoarseness, resulting from vocal cord paralysis due to compression of the left recurrent laryngeal or vagus nerves, frequently seen in patients with large aneurysms of the distal transverse arch or proximal descending thoracic aorta.
3. Dyspnea related to compression of the tracheobronchial tree.
4. Dysphagia or weight loss related to pressure on the adjacent esophagus or duodenum, leading to obstruction or early satiety.
5. Exsanguination, presenting as massive hemoptysis or hematemesis due to direct erosion of the aneurysm into the adjacent tracheobronchial tree, esophagus, or both. Less frequently, this can cause slow intermittent blood loss.
6. Paraplegia or paraparesis rarely occurs in patients with TAAA due to acute occlusion of the intercostal or spinal arteries. This is usually associated with acute aortic dissection but can also result from thrombo-embolization.
7. Distal embolization causing acute mesenteric, renal or lower extremity ischemia is infrequent, even though there is a varying amount of mural thrombus associated with aneurysms.

In 10% to 20% of patients rupture may be the first clinical manifestation of a TAAA. A ruptured aneurysm should be suspected if there is an acute onset of severe chest, abdominal or back pain associated with hypotension. A pulsatile mass may be palpable in the abdomen unless the larger part of the TAAA is positioned deep in the thoracic cage. Most ruptured aneurysms are fatal unless treated emergently, but the ruptured arterial wall may temporarily seal for several hours or days before free rupture. The rupture is usually contained within the pleura or retroperitoneum in patients who make it to the hospital alive. Free rupture with severe hypotension usually results in death before surgical care can be obtained.

### ***Preoperative evaluation and preparation***

The initial consultation with the TAAA patient includes:

1. A thorough history and physical examination, primarily to detect co-morbidities, as there are generally few symptoms or physical signs related to the aneurysm itself.
2. Imaging studies to determine the extent of the TAAA.
3. Evaluation of associated risk factors.
4. Consultation with cardiologist, pulmonologist or nephrologist to aid in the stratification of risks.
5. Transthoracic echocardiography to estimate cardiac function. Ischemic heart disease is prevalent and is the most common cause of death.



Coronary artery revascularization, using either percutaneous intervention (balloon angioplasty or stent) or surgical bypass, may be indicated prior to TAAA surgery. For patients who must undergo coronary artery bypass prior to TAAA repair, our conduit of choice is the saphenous vein graft. We avoid using the left internal mammary artery to obviate the possibility of cardiac ischemia should aortic cross-clamping proximal to the left subclavian artery be required during the TAAA repair. Moreover, the internal mammary artery may be an important collateral blood supply to the spinal cord.

## Operative techniques

The history of techniques reveals:

- 1- 1955: Etheredge did the first successful repair of a thoracoabdominal aortic aneurysm (TAAA) using a homograft tube.
- 2- 1956: DeBakey sewed his own Dacron tube grafts to replace the descending thoracic aorta and infrarenal abdominal aorta.
- 3- Crawford introduced the clamp-and-sew technique, encompassing three basic principles of aortic surgery: the inclusion technique, use of Dacron tube graft conduit, and reimplantation of both visceral and renal arteries.
- 4- A classification was developed based upon the extent of the TAAA (Figure 1).
- 5- Early operations had to be done with haste to avoid extended periods of organ ischemia. Now the use of adjuncts provides longer operative time, better organ protection and improved outcome.

Current operative procedures require a multidisciplinary team at a specialized cardiothoracic surgery unit. The patient is placed in the supine position on the operating table and prepared for surgery. General anesthesia is induced. Endotracheal intubation is established using a double lumen tube for selective one-lung ventilation during surgery. Electrodes are attached to the scalp for electroencephalogram (EEG) and along the spinal cord for both motor and somatosensory evoked potential (SSEP) to assess the central nervous system and spinal cord function, respectively. The patient is then positioned on the right side with the hips and knees flexed to open the intervertebral spaces. A lumbar catheter is placed in the 3<sup>rd</sup> or 4<sup>th</sup> lumbar space to provide cerebrospinal fluid (CSF) pressure monitoring and drainage. The CSF pressure is kept at 10 mmHg or less by gravity drainage of CSF fluid throughout the procedure.

We tailor the incision to complement the extent of the aneurysm. The full thoracoabdominal incision begins posteriorly between the tip of the scapula and the spinous process, curving along the sixth intercostal space to the costal cartilage, then obliquely to the umbilicus, and finally in the midline to above the symphysis pubis. The latissimus dorsi muscle is divided and at the insertion of the serratus. Usually, a full thoracoabdominal exploration is necessary for extent II, III and IV TAAA. A modified thoracoabdominal incision begins similar to the full thoracoabdominal incision but ends at the costal cartilage or above the umbilicus.

The modified thoracoabdominal incision provides excellent exposure for surgery involving the descending thoracic aorta, extent I, and extent V TAAA, when the aneurysm

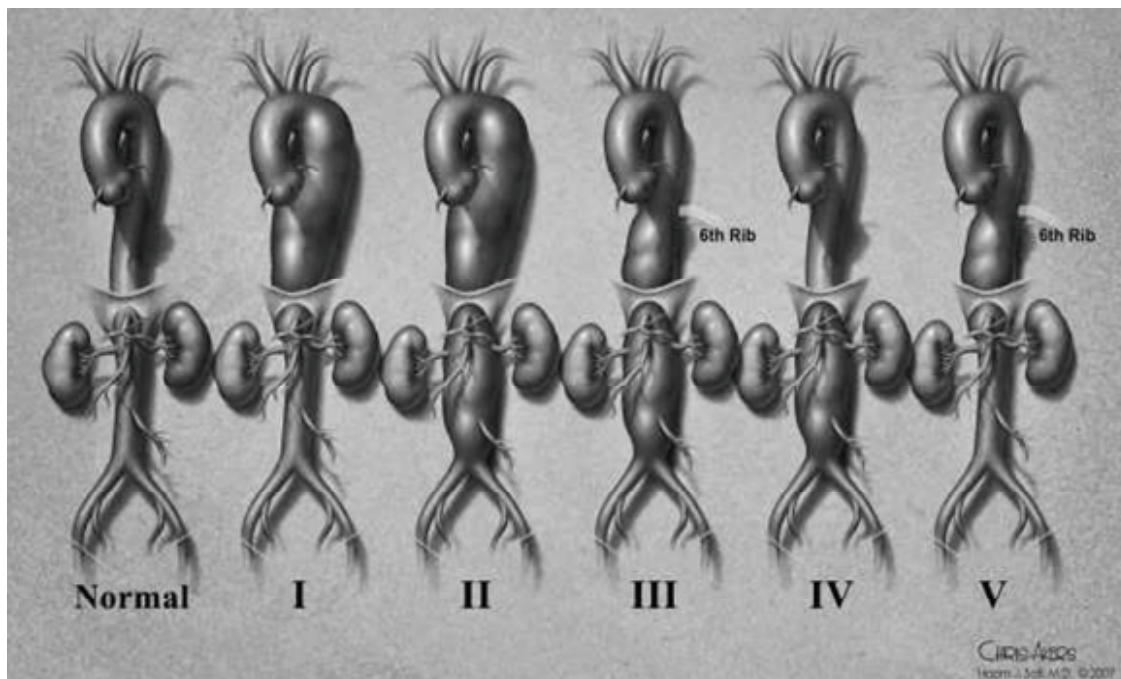


Figure 1. Thoracoabdominal aortic aneurysm classification. Extent I, distal to the left subclavian artery to above the renal arteries. Extent II, distal to the left subclavian artery to the below the renal arteries. Extent III, from the sixth intercostal space to below the renal arteries. Extent IV, the twelfth intercostal space to the iliac bifurcation (total abdominal aortic aneurysm). Extent V, below the sixth intercostal space to just above the renal arteries

ends above the superior mesenteric artery. We extend the thoracoabdominal incision to the level of the umbilicus, for extent I and V TAAA that involve the superior mesenteric artery. A self-retaining retractor is placed firmly on the edges of the incision to maintain full thoracic and abdominal exposure during the procedure.

The dissection begins at the level of the hilum of the lung cephalad to the proximal descending thoracic aorta. We identify the ligamentum arteriosum and transect it, taking care to avoid injury to the left recurrent laryngeal nerve. The extent of the distal abdominal aneurysm is assessed. We divide the muscular portion of the diaphragm only and preserve the left phrenic nerve (Figure 2). A retroperitoneal plane is then developed, mobilizing the spleen, bowel loops, and left kidney to the right side of the abdominal aorta (medial visceral rotation). To prepare for distal aortic perfusion, the patient is anticoagulated using intravenous heparin (1 mg/kg of weight). The pericardium is opened posterior to the left phrenic nerve to allow direct visualization of the pulmonary veins and left atrium. The left atrium is cannulated through the left inferior pulmonary vein or atrial appendage. A centrifugal pump with an in-line heat exchanger is attached to the left atrial cannula and the arterial inflow is established through the left common femoral artery, or the descending thoracic aorta, if the femoral artery is not accessible. Distal aortic perfusion is begun (Figure 3).

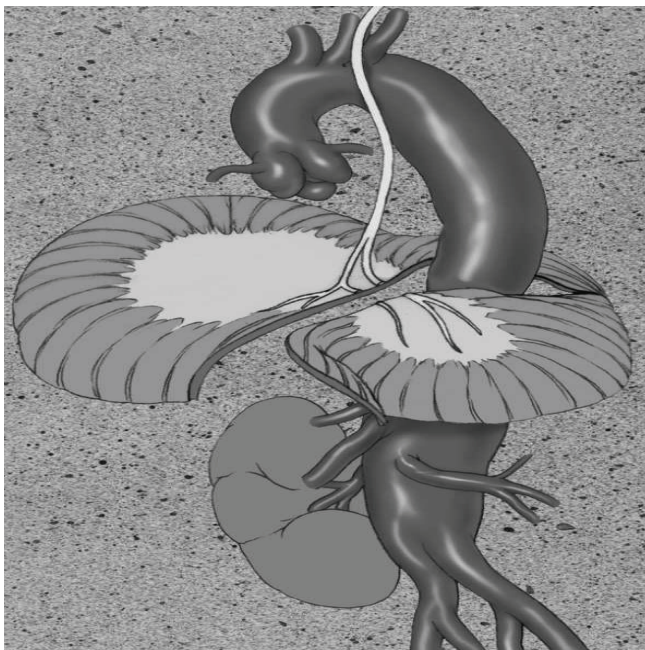


Figure 2. Only the muscular portion of the diaphragm is cut

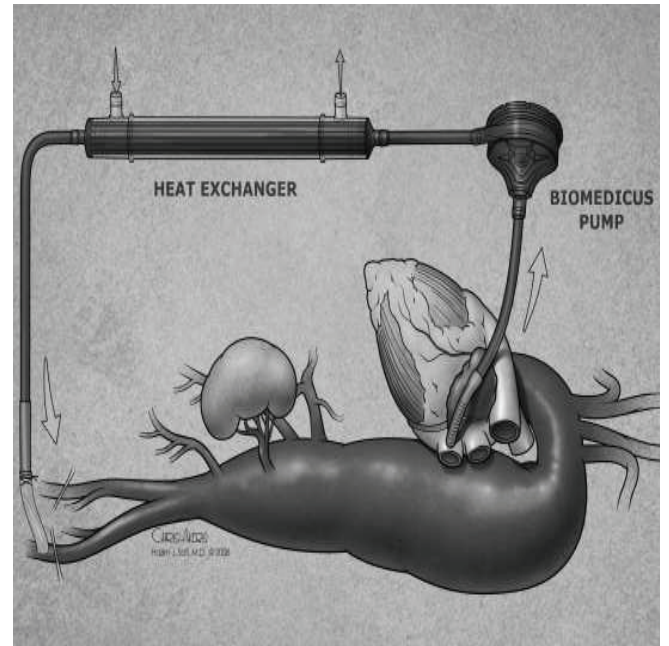


Figure 3. Distal aortic perfusion from the left pulmonary vein to the left femoral artery

Padded clamps are applied onto the proximal descending thoracic aorta just distal to the left subclavian artery and the mid-thoracic aorta. When the proximal extent of the aneurysm is too close to the left subclavian artery, we clamp the aorta between the left common carotid and left subclavian arteries and clamp the left subclavian artery separately. Because of the danger of graft-esophageal fistula, we no longer use the inclusion technique for the proximal anastomosis. Instead, we completely transect the aorta to separate it from the underlying esophagus (Figure 4a). We prefer a woven Dacron graft impregnated with collagen or gelatin for replacement. We suture the graft in an end-to-end fashion to the descending thoracic aorta, using a running 3-0 or 2-0 monofilament polypropylene suture. We check the anastomosis for bleeding and use pledgeted polypropylene sutures for reinforcement, if necessary. We use sequential clamping for all TAAAs. After completion of the proximal anastomosis, the mid-descending aortic clamp is moved distally onto the abdominal aorta at the celiac axis to accommodate intercostal reattachment. Reattachment of patent, lower intercostal arteries (T8-T12) is performed routinely, except in cases of occluded arteries, heavily calcified aorta, or acute aortic dissection. After completion of intercostal reattachment, the proximal clamp is released from the aorta and re-applied on the aortic graft beyond the intercostal patch, restoring pulsatile flow to the reattached intercostal arteries (Figure 4b). The distal clamp is moved onto the infrarenal aorta, the abdominal aorta is opened, and the graft is passed through the aortic hiatus. The



celiac, superior mesenteric and renal arteries are identified and perfused using #9 or #12 F balloon-tipped catheters, depending on the size of the ostia (Figure 4c). The delivery of cold perfusate (4°C) to the viscera is maintained between 300 and 600 mL/min. Renal temperature is directly monitored and kept at approximately 15°C. The visceral vessels are usually reattached using the inclusion technique. Upon completion of this anastomosis, the proximal clamp is moved beyond the visceral patch, restoring pulsatile flow to the viscera and kidneys (Figure 4d). The final graft anastomosis is then completed at the aortic bifurcation. In most cases an island patch accommodates reattachment of the celiac, superior mesenteric, and both renal arteries. If the right or left renal artery is located at too great a distance from other arteries, its reattachment usually requires a separate interposition bypass graft. We no longer use a visceral patch for Marfan patients, because of the high incidence of recurrent patch aneurysms in such cases. Instead we use a woven Dacron graft with side-arm grafts of 10 mm and 12 mm for separate attachment of the celiac, superior mesenteric and the left and right renal arteries.

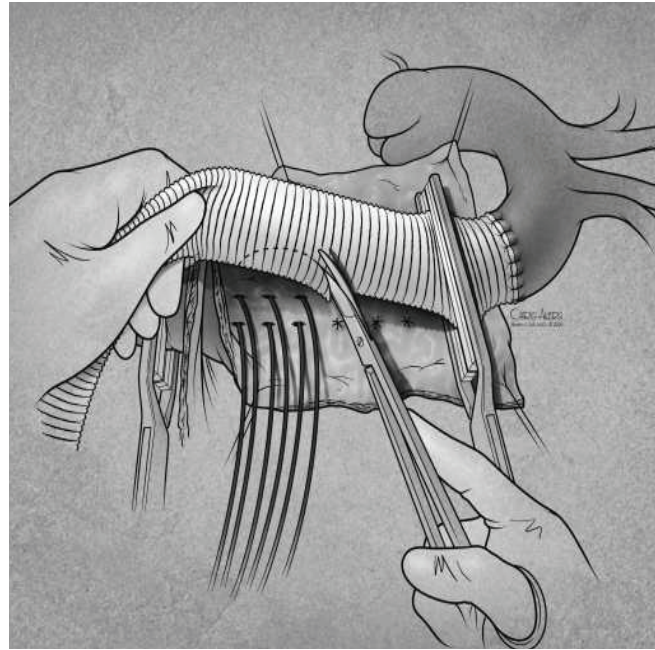


Figure 4b. The proximal anastomosis is fashioned. Subsequently, the patent lower intercostal arteries are reattached via an elliptical hole in the graft. The proximal clamp is then moved onto the graft to restore pulsatile flow to the intercostal arteries, and the graft is pulled through the hiatus into the abdomen

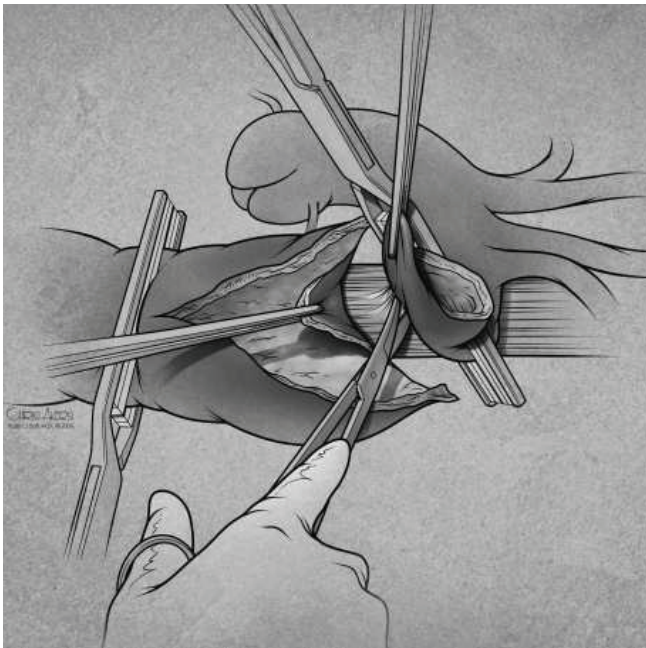


Figure 4a. Sequential clamping and graft replacement. Padded clamps are placed on the proximal and mid distal descending thoracic aorta. The proximal part of the aneurysm is opened. The aortic neck is completely transected and separated from the esophagus.

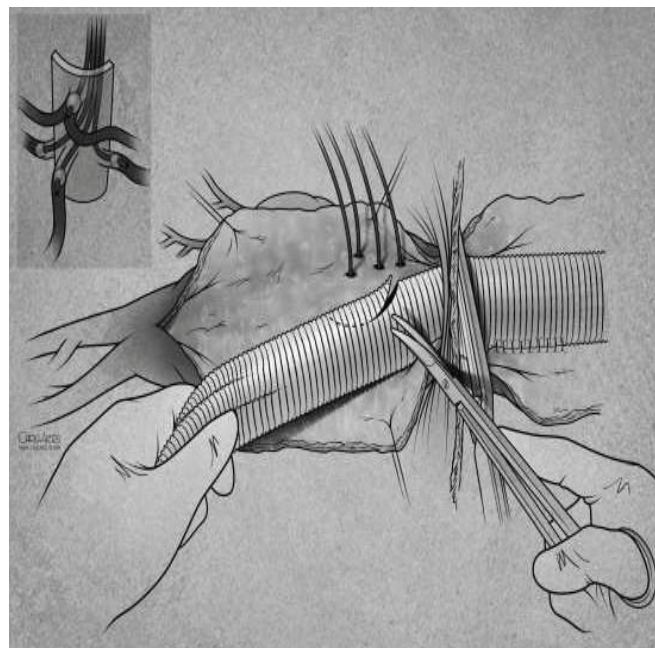


Figure 4c. The distal clamp is reapplied onto the infrarenal aorta. The remaining of the aneurysm is opened. Balloon-tipped catheters are inserted into the celiac, superior mesenteric, and renal arteries to permit perfusion. An elliptical hole is made in the graft for

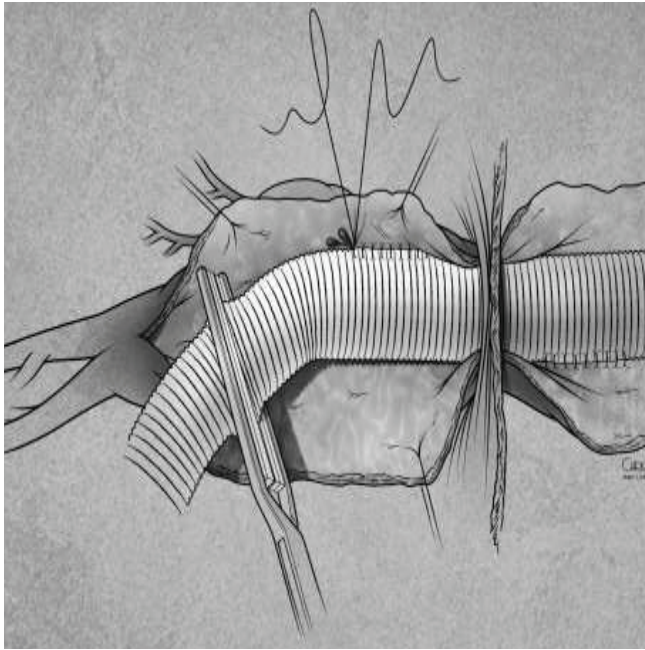


Fig 4d. Pulsatile flow is then restored to the visceral and renal arteries, and the distal anastomosis is completed

We then wean the patient from partial bypass once the core body or nasopharyngeal temperatures reaches 36 to 37°C. Protamine is administered (1 mg/1 mg heparin) and the atrial and femoral cannulae are removed. Once hemostasis is achieved, two or sometimes three 36-F chest tubes are placed in the pleural cavity for drainage. The diaphragm is reapproximated using running #1 polypropylene suture. The left lung is re-inflated. Closure of the incision is done in a standard fashion. The patient is placed in the supine position, and the double lumen endotracheal tube is exchanged for a single lumen tube. If the vocal cords are swollen, the double lumen tube is kept in place until the swelling resolves. The patient is then transferred to the intensive care unit.

### ***Postoperative management***

In the intensive care unit we monitor the patient's hemodynamics closely. We try to wake the patient as quickly as possible to check neurologic status. The patient's mean arterial pressure is maintained between 90 and 100 mmHg to ensure good organ perfusion, particularly to the spinal cord. CSF pressure is continuously monitored. Approximately 10 to 15 mL of CSF is drained hourly to keep CSF pressure at 10 mmHg or less. We start weaning the patient off the ventilator on the first postoperative day.

After the patient recovers from anesthesia and is moving all extremities, we are on the alert for delayed neurologic deficit. Warning signs for delayed neurologic deficit are unstable arterial blood pressure, hypoxemia, low hemoglobin (<10 g/dl), or increased CSF pressure (>15 mmHg).

Cerebrospinal fluid drainage is discontinued on the third postoperative day. We recommend annual CT scan follow-up to screen for the development of new aneurysm or graft-related pseudoaneurysm formation. The frequency of follow-up visits or CT scans may vary based on TAAA etiology. For example, patients with remaining unrepaired aortic dissection, connective tissue disorders (Marfan syndrome), a family history of aortic aneurysm, or concurrent aneurysms may need closer surveillance.

### ***Results of Surgery***

Mortality rates for patients undergoing thoracoabdominal and descending thoracic aortic aneurysm repair range between 4% and 21%,<sup>10,33-35</sup> depending on the series. The differing success rates are partly related to the heterogeneity of the patient population, and to the expertise of the treating team. In our cumulative experience, (January 1991 to February 2003), 1004 patients underwent thoracoabdominal and descending thoracic aortic aneurysm repair.<sup>36</sup> Sixty-three percent of our patients were men. The median age was 65 years (range, 8 to 89 years). Approximately 7% of patients had emergency surgery for free or contained rupture of thoracoabdominal or descending thoracic aortic aneurysm. Currently, our 30-day mortality rate is 14%. The mortality rate highly correlates with preoperative renal function as determined by calculated glomerular filtration rate (GFR). Patients with a GFR greater than 90 mL/min/1.73 m<sup>2</sup> had a mortality rate of 5.6% compared to a rate of 27.8% in patients with a GFR less than 49 mL/min/1.73 m<sup>2</sup>.<sup>37</sup> Using multivariable analysis, we have identified advanced age, renal failure, and paraplegia as important risk factors for mortality.<sup>38</sup> Patients aged 79 years or older with at least one of three factors-emergency presentation, a history of diabetes or congestive heart failure-have been identified as a particularly high-risk group with 30-day mortality as high as 50%.<sup>39</sup> Overall, 70% of our patients recover from TAAA without significant postoperative complications.<sup>40</sup> The 5-year survival for our patients after TAAA is between 60% and 70%. Recently, we found the negative predictors for long-term survival to include advanced age, extent II TAAA, renal failure, emergency surgery, cerebrovascular disease and active tobacco smoking.<sup>36</sup>

### ***Neurologic Outcome***

Postoperative neurologic deficit (ND) is the most devastating complication following TAAA repair. When the descending thoracic aorta is cross-clamped, the spinal cord is quickly rendered ischemic because of the immediate



interruption of perfusion to the spinal cord and consequent increased CSF pressure. Therefore, in the clamp-and-sew era, the single most important predictor of ND was the length of the clamp time. Our method of protection is to increase the spinal cord perfusion pressure directly with distal aortic perfusion, and indirectly by reducing CSF pressure to 10 mmHg or less. Animal and human studies have confirmed that CSF drainage reduces CSF pressure and can improve spinal cord perfusion during aortic cross clamping.<sup>41-43</sup>

We have utilized distal aortic perfusion and CSF drainage as adjuncts for all patients undergoing elective repair of TAAA since 1992. The overall incidence of ND was 3.3% (36/1106) with an incidence of ND of 1.1% during the last quartile. This combination of adjuncts has reduced our cumulative rate of ND to 0.9% for descending thoracic aortic repair and to 3.3% for thoracoabdominal aortic repair.<sup>36</sup> Repair of the most extensive TAAs (extent II) has long been known to result in the highest incidence of ND. In the clamp-and-sew era, this incidence was as high as 30% to 40%.<sup>34</sup> With the use of adjuncts, the rate of immediate ND for extent II TAAA has been reduced to 4% in our series.<sup>36</sup> In addition to the extent of the aneurysm, other perioperative risk factors for immediate ND include age, emergency presentation, renal dysfunction, active smoking, and cerebrovascular disease. The use of intraoperative distal aortic perfusion and perioperative CSF drainage, in combination, prevents one ND in twenty cases for all patients, and one in five for extent II TAAA.<sup>36</sup>

The reimplantation of intercostal arteries is critical in spinal cord protection. Reimplantation of intercostal arteries was found to be a risk factor for postoperative neurologic deficit during the clamp-and-sew era<sup>44</sup> because of the longer cross-clamp time required for reimplantation. The level at which the anterior radicular artery (known as the artery of Adamkiewicz, or *arteria radicularis magna*) originates is known to be variable. Usually it branches from one of the lower intercostal arteries with or without additional collateral branches from nearby intercostal arteries. The anterior radicular artery is believed to be the major blood supply to the anterior spinal artery of the spinal cord. We studied the relationship of neurologic deficit to ligation, reimplantation, and pre-existing occlusion of intercostal arteries in patients undergoing TAAA repair using adjuncts. We found that ligation of patent lower intercostal arteries (T9 to T12) increased the risk of paraplegia.<sup>44</sup> Therefore we reattach all patent lower intercostal arteries from T9 to T12, either together as a patch to a side hole made in the Dacron graft or, when the intercostal arteries are too far apart, separately as buttons or using interposition bypass grafts. However, if the lower intercostal arteries are occluded, we will reimplant the patent upper intercostal arteries, because these are thought to assume a more important role in the collateral system to the anterior spinal artery in this situation.

## Delayed Neurologic Deficits

Delayed neurologic deficit (DND) refers to the onset of paraplegia or paraparesis after a period of normal neurologic function. DND after TAAA repair was first reported in 1988, at which time the condition was considered irreversible and beyond the surgeon's control.<sup>45</sup> Since then numerous reports have described improvements in patients' neurologic function by using CSF drainage for DND.<sup>46-48</sup> We have observed DND as early as 2 hours and as late as 2 weeks following surgery (median, 3 days), in 2.7% of patients.<sup>49</sup> We have found no single risk factor responsible for DND. However, using multivariable analysis, we identified acute dissection, extent II TAAA, and renal insufficiency as significant preoperative predictors for DND.<sup>49</sup> In a subsequent case-control study, postoperative mean arterial pressure of less than 60 mmHg and CSF drain complications were found to be predictors in the development of DND, independent of preoperative predictors.<sup>50</sup>

DND has emerged as an important clinical entity now that improved spinal cord protection during TAAA surgery has reduced the incidence of neurologic complications. The exact mechanisms involved in the development of DND remain unknown. DND after TAAA repair may result from a 'second hit' phenomenon. Adjuncts can protect the spinal cord intraoperatively and reduce the incidence of immediate neurologic deficit, but the spinal cord remains vulnerable during the early postoperative period. Additional ischemic insults caused by hemodynamic instability, malfunction of the CSF drainage catheter, or both may constitute a 'second hit,' causing DND. Furthermore, in the rigid, unyielding spinal column, any rise in CSF pressure could lead to an increase in compartment pressure, with consequent decreased spinal cord perfusion. Hence, we drain CSF freely when DND develops to relieve the compartment pressure.

To optimize postoperative spinal cord perfusion and oxygen delivery, we keep the mean arterial pressure above 90 to 100 mmHg, hemoglobin above 10 mg/dL, and cardiac index greater than 2.0 L/min. If DND occurs, measures to increase spinal cord perfusion are begun immediately. The patient is placed flat in the supine position. The patency and function of the drain is ascertained at once. If the drain has been removed, the CSF drainage catheter is reinserted immediately and CSF is drained freely until the CSF pressure drops below 10 mmHg. The systemic arterial pressure is raised, blood transfusion is liberally infused, and oxygen saturation is increased, as indicated above. CSF drainage is continued for at least 72 hours for all patients with delayed onset neurologic deficit. Using this multifaceted approach to treating delayed onset neurologic deficit, we have seen overall improvement in neurologic function, as measured from the time of onset, in 57% of these patients.<sup>49</sup> Recovery was dependent on the status of the CSF drain at the time of onset. Seventy-five percent of patients recovered function when the CSF drain was still in place at the onset of delayed



neurologic deficit; 43% recovered neurologic function if the CSF drain had to be reinserted at the time of the delayed neurologic deficit. Patients who developed DND but did not have CSF drainage failed to recover function.

## Endoluminal Approach

Endovascular management of thoracic aortic pathology has evolved at a rapid pace since the first successful reported thoracic endograft procedure in 1991.<sup>51</sup> Numerous centers have reported series of patients receiving thoracic endografts for a variety of conditions, including acute and chronic type B aortic dissections, traumatic thoracic transections, and descending thoracic and TAAAs.<sup>52-54</sup> Although the short-term benefits of endovascular therapy are clear, with less morbidity and shorter length of hospital stay compared to conventional surgery, the reported mortality rates appear to replicate those from conventional surgery in large centers. The long-term effectiveness of endoluminal exclusion of aneurysms remains to be determined. Several cases of immediate and delayed paraplegia have been reported in the literature following thoracic endograft placement.<sup>55,56</sup> The development of fenestrated and branched endografts allows for reimplantation of patent visceral and renal arteries. The rapid advances in this field have made endovascular treatment an alternative to open repair in selected patients with TAAA. These devices currently have to be custom made to the patient's anatomy. Although tremendous progress has been made, the technology is still in its infancy. This approach is presently available in a very limited number of specialized centers and requires collaboration between different specialties. Surgeons who attempt this procedure must have extensive experience with endovascular techniques including treatment of abdominal and descending thoracic aortic aneurysms. There is much work that remains to be done in developing devices that are applicable to a wider range of patients with TAAA.

## Conclusion

Much progress has been made in the surgical treatment of TAAA. The reduction in mortality and complication rates can be attributed to improvements in perioperative care and in surgical technique, particularly the adoption of adjunct distal aortic perfusion and cerebrospinal fluid drainage. Neurologic deficit is no longer a major threat to patients, as the use of adjuncts has brought the incidence down to 2.4% for all TAAA. Further research is needed to improve organ preservation. The evolution of endovascular technology and the development of branched devices hold great promise in the future management of TAAA.

## Acknowledgement

We are grateful to G. Ken Goodrick, our editor, and to Chris Akers for his assistance with the illustrations.

## References

1. Bickerstaff LK, Hollier LH, Van Peenen HJ, Melton LJ, Pairolero PC, Cherry KJ. Abdominal aortic aneurysms: the changing natural history. *J Vasc Surg* 1984;1:6-12.
2. Wanhainen A, Bjorck M, Boman K, Rutegard J, Bergqvist D. Influence of diagnostic criteria on the prevalence of abdominal aortic aneurysm. *J Vasc Surg* 2001;34:229-235.
3. Wilmink AB, Quick CR. Epidemiology and potential for prevention of abdominal aortic aneurysm. *Br J Surg* 1998;85:155-162.
4. Clouse WD, Hallett JW, Schaff HV, Gayari MM, Ilstrup DM, Melton LJ. Improved prognosis of thoracic aortic aneurysms: a population-based study. *JAMA* 1998;280:1926-1929.
5. Bickerstaff LK, Pairolero PC, Hollier LH, Melton LJ, Van Peenen HJ, Cherry KJ. Thoracic aortic aneurysms: a population-based study. *Surgery* 1982;92:1103-1108.
6. Perko MJ, Norgaard M, Herzog TM, Olsen PS, Schroeder TV, Pettersson G. Unoperated aortic aneurysm: a survey of 170 patients. *Ann Thorac Surg* 1995;59:1204-1209.
7. Pressler V, McNamara JJ. Thoracic aortic aneurysm: natural history and treatment. *J Thorac Cardiovasc Surg* 1980;79:489-498.
8. Crawford ES, Crawford JL, Safi HJ, Coselli JS, Hess KR, Brooks B. Thoracoabdominal aortic aneurysms: preoperative and intraoperative factors determining immediate and long-term results of operations in 605 patients. *J Vasc Surg* 1986;3:389-404.
9. Cambria RA, Gloviczki P, Stanson AW, Cherry KJ, Bower TC, Hallett JW. Outcome and expansion rate of 57 thoracoabdominal aortic aneurysms managed nonoperatively. *Am J Surg* 1995;170:213-217.
10. Letsou GV, Hogan JF, Bsee, Miller CC, Elefteriades JA, Francischelli D. Physiologic characteristics of canine skeletal muscle: implications for timing skeletal muscle cardiac assist devices. *Ann Thorac Surg* 2001;72:1336-1342.
11. Lobato AC, Puech-Leao P. Predictive factors for rupture of thoracoabdominal aortic aneurysm. *J Vasc Surg* 1998;27:446-453.
12. Juvonen T, Ergin MA, Galla JD, Lansman SL, Nguyen KH, McCullough JN. Prospective study of the natural history of thoracic aortic aneurysms. *Ann Thorac Surg* 1997;63:1533-1545.
13. Coady MA, Rizzo JA, Hammond GL, Kopf GS, Elefteriades JA. Surgical intervention criteria for thoracic aortic aneurysms: a study of growth rates and complications. *Ann Thorac Surg* 1999;67:1922-1926.
14. Davies RR, Goldstein LJ, Coady MA, Tittle SL, Rizzo JA, Kopf GS. Yearly rupture or dissection rates for thoracic aortic aneurysms: simple prediction based on size. *Ann Thorac Surg* 2002;73:17-27.
15. Dapunt OE, Galla JD, Sadeghi AM, Lansman SL, Mezrow CK, de Asla RA. The natural history of thoracic aortic aneurysms. *J Thorac Cardiovasc Surg* 1994;107:1323-1332.
16. Ailawadi G, Eliason JL, Upchurch GR. Current concepts in the pathogenesis of abdominal aortic aneurysm. *J Vasc Surg* 2003;38:584-588.
17. Lopez-Candales A, Holmes DR, Liao S, Scott MJ, Wickline SA, Thompson RW. Decreased vascular smooth muscle cell density





in medial degeneration of human abdominal aortic aneurysms. *Am J Pathol* 1997;150:993-1007.

18. Pan JH, Lindholt JS, Sukhova GK, Baugh JA, Henneberg EW, Bucala R. Macrophage migration inhibitory factor is associated with aneurysmal expansion. *J Vasc Surg* 2003;37:628-635.

19. Longo GM, Xiong W, Greiner TC, Zhao Y, Fiotti N, Baxter BT. Matrix metalloproteinases 2 and 9 work in concert to produce aortic aneurysms. *J Clin Invest* 2002;110:625-632.

20. Annabi B, Shedid D, Ghosn P, Kenigsberg RL, Desrosiers RR, Bojanowski MW. Differential regulation of matrix metalloproteinase activities in abdominal aortic aneurysms. *J Vasc Surg* 2002;35:539-546.

21. McMillan WD, Pearce WH. Increased plasma levels of metalloproteinase-9 are associated with abdominal aortic aneurysms. *J Vasc Surg* 1999;29:122-127.

22. Biddinger A, Rocklin M, Coselli J, Milewicz DM. Familial thoracic aortic dilatations and dissections: a case control study. *J Vasc Surg* 1997;25:506-511.

23. Coady MA, Davies RR, Roberts M, Goldstein LJ, Rogalski MJ, Rizzo JA. Familial patterns of thoracic aortic aneurysms. *Arch Surg* 1999;134:361-367.

24. Pannu H, Fadulu VT, Chang J, Lafont A, Hasham SN, Sparks E. Mutations in transforming growth factor-beta receptor type II cause familial thoracic aortic aneurysms and dissections. *Circulation* 2005;112:513-520.

25. Hossack KF, Leddy CL, Johnson AM, Schrier RW, Gabow PA. Echocardiographic findings in autosomal dominant polycystic kidney disease. *N Engl J Med*. 1988;319:907-912.

26. Elsheikh M, Casadei B, Conway GS, Wass JA. Hypertension is a major risk factor for aortic root dilatation in women with Turner's syndrome. *Clin Endocrinol (Oxf)* 2001;54:69-73.

27. Pepin M, Schwarze U, Superti-Furga A, Byers PH. Clinical and genetic features of Ehlers-Danlos syndrome type IV, the vascular type. *N Engl J Med* 2000;342:673-680.

28. Wenstrup RJ, Meyer RA, Lyle JS, Hoehstetter L, Rose PS, Levy HP. Prevalence of aortic root dilation in the Ehlers-Danlos syndrome. *Genet Med* 2002;4:112-117.

29. Bachet JE, Termignon JL, Dreyfus G, Goudot B, Martinelli L, Piquois A. Aortic dissection. Prevalence, cause, and results of late reoperations. *J Thorac Cardiovasc Surg* 1994;108:199-205.

30. Bernard Y, Zimmermann H, Chocron S, Litzler JF, Kastler B, Etievent JP. False lumen patency as a predictor of late outcome in aortic dissection. *Am J Cardiol* 2001;87:1378-1382.

31. Marui A, Mochizuki T, Mitsui N, Koyama T, Kimura F, Horibe M. Toward the best treatment for uncomplicated patients with type B acute aortic dissection: a consideration for sound surgical indication. *Circulation* 1999;100:II275-280.

32. Juvonen T, Ergin MA, Galla JD, Lansman SL, McCullough JN, Nguyen K. Risk factors for rupture of chronic type B dissections. *J Thorac Cardiovasc Surg* 1999;117:776-786.

33. Kouchoukos NT, Daily BB, Rokkas CK, Murphy SF, Bauer S, Abboud N. Hypothermic bypass and circulatory arrest for operations on the descending thoracic and thoracoabdominal aorta. *Ann Thorac Surg* 1995;60:67-76.

34. Svensson LG, Crawford ES, Hess KR, Coselli JS, Safi HJ. Experience with 1509 patients undergoing thoracoabdominal aortic operations. *J Vasc Surg* 1993;17:357-368.

35. Cambria RP, Clouse WD, Davison JK, Dunn PF, Corey M, Dorer D. Thoracoabdominal aneurysm repair: results with 337 operations performed over a 15-year interval. *Ann Surg* 2002;236:471-479.

36. Safi HJ, Miller CC 3rd, Huynh TT, Estrera AL, Porat EE, Vinnerkvist AN, Allen BS, Hassoun HT, Moore FA. Distal aortic perfusion and cerebrospinal fluid drainage for thoracoabdominal and descending thoracic aortic repair: ten years of organ protection. *Ann Surg* 2003;238:372-381.

37. Huynh TT, van Eps RG, Miller CC 3rd, Villa MA, Estrera AL, Azizzadeh A, Porat EE, Goodrick JS, Safi HJ. Glomerular filtration rate is superior to serum creatinine for prediction of mortality after thoracoabdominal aortic surgery. *J Vasc Surg* 2005;42:206-212.

38. Safi HJ, Campbell MP, Ferreira ML, Azizzadeh A, Miller CC. Spinal cord protection in descending thoracic and thoracoabdominal aortic aneurysm repair. *Semin Thorac Cardiovasc Surg* 1998;10:41-44.

39. Huynh TT, Miller CC 3rd, Estrera AL, Sheinbaum R, Allen SJ, Safi HJ. Determinants of hospital length of stay after thoracoabdominal aortic aneurysm repair. *J Vasc Surg* 2002;35:648-653.

40. Miller CC, Porat EE, Estrera AL, Vinnerkvist AN, Huynh TT, Safi HJ. Analysis of short-term multivariate competing risks data following thoracic and thoracoabdominal aortic repair. *Eur J Cardiothorac Surg* 2003;23:1023-1027.

41. Jacobs MJ, de Mol BA, Elenbaas T, Mess WH, Kalkman CJ, Schurink GW. Spinal cord blood supply in patients with thoracoabdominal aortic aneurysms. *J Vasc Surg* 2002;35:30-37.

42. Hollier LH, Money SR, Naslund TC, Proctor CD, Buhrman WC, Marino RJ. Risk of spinal cord dysfunction in patients undergoing thoracoabdominal aortic replacement. *Am J Surg* 1992;164:210-213.

43. Coselli JS, Lemaire SA, Koksoy C, Schmittling ZC, Curling PE. Cerebrospinal fluid drainage reduces paraplegia after thoracoabdominal aortic aneurysm repair: results of a randomized clinical trial. *J Vasc Surg* 2002;35:631-639.

44. Safi H, Miller CI, Carr C, Iliopoulos D, Dorsay D, Baldwin J. The importance of intercostal artery reattachment during thoracoabdominal aortic aneurysm repair. *J Vasc Surg* 1998;27:58-68.

45. Crawford ES, Mizrahi EM, Hess KR, Coselli JS, Safi HJ, Patel VM. The impact of distal aortic perfusion and somatosensory evoked potential monitoring on prevention of paraplegia after aortic aneurysm operation. *J Thorac Cardiovasc Surg* 1988;95:357-367.

46. Widmann MD, DeLucia A, Sharp WJ, Richenbacher WE. Reversal of renal failure and paraplegia after thoracoabdominal aneurysm repair. *Ann Thorac Surg* 1998;65:1153-1155.

47. Azizzadeh A, Huynh TT, Miller CC 3rd, Safi HJ. Reversal of twice-delayed neurologic deficits with cerebrospinal fluid drainage after thoracoabdominal aneurysm repair: a case report and plea for a national database collection. *J Vasc Surg* 2000;31:592-598.

48. Safi HJ, Miller CC 3rd, Azizzadeh A, Iliopoulos DC. Observations on delayed neurologic deficit after thoracoabdominal aortic aneurysm repair. *J Vasc Surg* 1997;26:616-622.

49. Estrera AL, Miller CC, Huynh TT, Azizzadeh A, Porat EE, Vinnerkvist A. Preoperative and operative predictors of delayed neurologic deficit following repair of thoracoabdominal aortic aneurysm. *J Thorac Cardiovasc Surg* 2003;126:1288-1294.

50. Azizzadeh A, Huynh TT, Miller CC, Estrera AL, Porat EE, Sheinbaum R. Postoperative risk factors for delayed neurologic deficit after thoracic and thoracoabdominal aortic aneurysm repair: a case-control study. *J Vasc Surg* 2003;37:750-754.

51. Volodos NL, Karpovich IP, Troyan VI, Kalashnikova Yu V, Shekhanin VE, Ternyuk NE. Clinical experience of the use of self-fixing synthetic prostheses for remote endoprosthetics of the thoracic and the abdominal aorta and iliac arteries through the femoral artery and as intraoperative endoprosthesis for aorta reconstruction. *Vasa*



Suppl 1991;33:93-95.

52. Buffolo E, da Fonseca JH, de Souza JA, Alves CM. Revolutionary treatment of aneurysms and dissections of descending aorta: the endovascular approach. *Ann Thorac Surg* 2002;74:S1815-1817.

53. Dake MD, Miller DC, Mitchell RS, Semba CP, Moore KA, Sakai T. The "first generation" of endovascular stent-grafts for patients with aneurysms of the descending thoracic aorta. *J Thorac Cardiovasc Surg* 1998;116:689-703.

54. Greenberg R, Resch T, Nyman U, Lindh M, Brunkwall J, Brunkwall P. Endovascular repair of descending thoracic aortic aneurysms: an early experience with intermediate-term follow-up. *J Vasc Surg* 2000;31:147-156.

55. Kasirajan K, Dolmatch B, Ouriel K, Clair D. Delayed onset of ascending paralysis after thoracic aortic stent graft deployment. *J Vasc Surg* 2000;31:196-199.

56. Gravereaux EC, Faries PL, Burks JA, Latessa V, Spielvogel D, Hollier LH. Risk of spinal cord ischemia after endograft repair of thoracic aortic aneurysms. *J Vasc Surg* 2001;34:997-1003.